

## Small/medium size mid line ventral hernias: 4 layer Suture repair on physiological principle

Dr. Desarda M.P. (MS. General Surgery)

Consultant & Medical Director, Indian Hernia Institute, 1273, Shiwajinagar, Pune-411004, India

Correspondence: Dr. Desarda MP, 18, Vishwalaxmi Hsg Society, Kothrud, Pune-411038, INDIA.

EMAIL: desarda@desarda.com

---

### Abstract

**Background:** Mesh is routinely implanted to give mechanical artificial re-enforcement in front of the sutured hernia defect in the mid line abdominal wall or ventral hernias. This study shows how anterior rectus sheath is used in place of mesh to give such mechanical and biological re-enforcement in small and medium size ventral hernias. Additional recti muscle suture in mid line takes care of the divarication of recti, strengthens the weakened linea alba and repair such hernias on physiological principle with excellent success rate.

**Materials and methods:** This is a prospective study done on 161 patients operated during a period from June 2010 to May 2018 and followed up till June 2019. The sac is excised or inverted in the abdomen and closure of hernia defect + re-enforcement with anterior rectus sheath and strengthening of linea alba + recti muscles suture in mid line (Type A operation) was done in 131 patients and without such muscle suture in mid line (Type B operation) in 30 patients. Hospital stay, complications, pain, ambulation, recovery, post-operative life style and recurrences were recorded for a median follow up period of 4.5 years.

**Results:** 88.2% patients were followed up for a median period of 4.5 years. Median age was 50.5 years. 99.4% patients had a median stay of 18 hours in the hospital. Mild pain was seen in 96.9% patients. 98.1% patients had negligible pain and were freely mobile within a week. Hematoma in 2 (1.2%) and mild skin infection in 2 (1.2%) patients was noted. 2 (1.2%) patients had recurrence.

**Conclusions:** Repair of small and medium size mid line abdominal wall hernia by this 4 layer technique is anatomical without mesh. It shows good recovery with acceptable complication and recurrence rate without any foreign body complications. Therefore, it can be used as a first choice of repair in such patients.

**Key words:** Ventral hernia, Mid line abdominal wall hernia, Rectus diastasis, Linea alba, Physiological repair

---

Date of Submission: 26-05-2020

Date of Acceptance: 13-06-2020

---

### I. Introduction

All hernias were repaired anatomically before the mesh era started. Results of the operations done as described by the original author of the technique without modification were also reasonably satisfactory. But the large size and complex hernias were a problem for anatomical repairs due to more complications and recurrences. Use of mesh implants have shown improved results with reduced recurrence rates in such large size hernias. Later in 1990's it gradually spread to even small size and uncomplicated hernias as well due to simplicity of procedure. Today, mesh implant, open or laparoscopic, has become a routine to be used in all types of hernias even though many of them could have been repaired anatomically without mesh with excellent results and success.

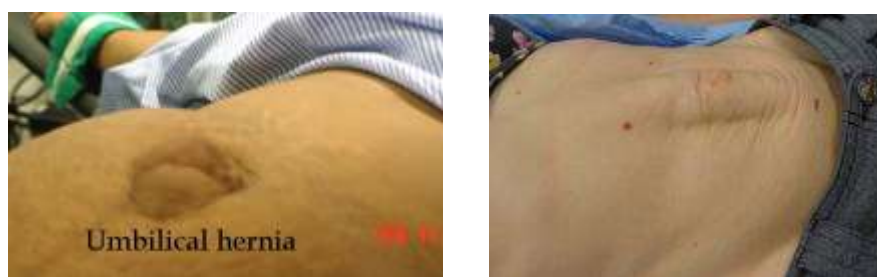But the main question still remains to be answered. 1] Have mesh implants really reduced recurrence rates over the suture repairs especially in small and medium sized hernias? 2] Can foreign body complications seen with mesh override the benefit of supposedly reduced recurrence rates? 3] Trend of ventral hernia to be repaired through laparoscope is justifiable? The author tried to answer these questions in this study. The author is of the opinion that the physiologically dynamic repair of midline ventral hernia will yield better results than the static repairs. Accordingly, this study was conducted to find the outcomes of pure tissue repairs of small/medium size midline ventral hernias on physiological principle.

### II. Materials And Methods

This prospective study was done on 161 patients operated during a period from June 2010 to May 2018. Patients included were between the age group of 18 to 80 years with the small/medium size (defect <5cms) midline ventral hernias and BMI less than 30. Subxiphoidal, recurrent, large hernias (defect >5cm) and obese patients (BMI >30) were excluded from this study. 88 (54.6%) were females and 73 (45.4%) were males. The patients were given a laxative dose of 20 gms Magnesium Sulfate for 1-2 nights prior to surgery to evacuate

the gases component in the abdomen. Patients with distended abdomen were prepared for 30 days by asking to reduce normal diet by 25% to reduce some weight and to take daily mild laxative to completely evacuate the bowels. Operations were done under spinal anesthesia. 60-90 micrograms of Bupriganesic was injected intrathecally along with the anesthetic agent. This reduces the post-operative pain dramatically. A shot of antibiotic (Cefixime 200 mg.) was given in operation theatre. Level of pain was measured as per the analgesics required. It was labelled as mild pain if patients were happy with oral analgesics, moderate if needed injectable analgesics or severe if they needed combination of both. Patients were ambulated as soon as the effect of spinal anaesthesia was gone. Mobility was measured as bed rest, limited movements in the room and freely mobile. The patients were given one-night stay and discharged next day if there were no complications. Patients were followed up after 10 days, 1 month, 6 months and then yearly. Patients not able to come for follow up were enquired on telephone about complications if any as per the PINQ-PHONE (Patient information need questionnaire), a 4-question telephone questionnaire designed and validated as a recurrence and complication detection method. Patients giving positive responses were called to visit the outpatient clinic. Hospital stay, complications, pain, ambulation, recovery, post-operative life style and recurrences were recorded. The data collected was analyzed at the end of this study.

### Operation Technique:

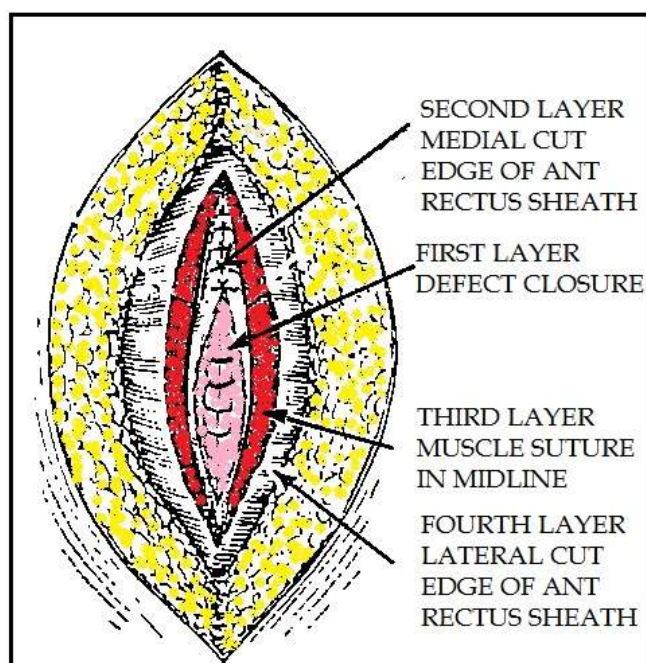


Umbilical hernia

Divarication of recti muscles

(Both umbilical hernia defect and divarication of recti must be repaired together to give excellent results)

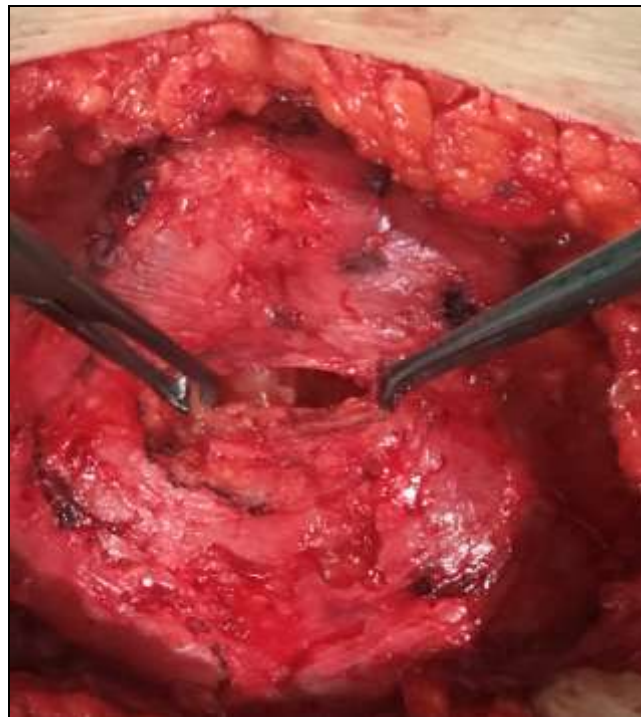
### 1] Type A Repair with mid line suture of recti muscles (Figure 1-9):



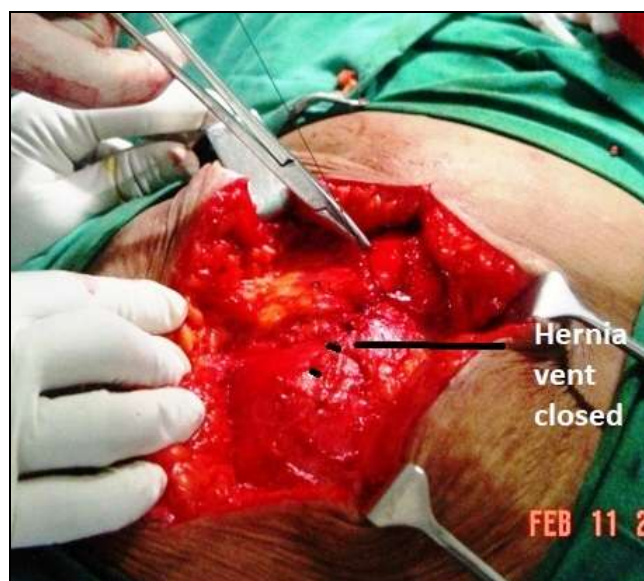**Fig. 1.** Linear diagram showing steps of the 4 layer repair (Type A repair)

**Step 1:** - Vertical midline incision is taken to preserve the umbilicus. Otherwise, an elliptical incision is taken encircling the hernia sac/umbilicus going for about 2 inches above and below the hernia sac. The hernia sac is cleared of fat and subcutaneous tissue up to its neck. Dissection is further extended to clear the anterior rectus sheath for about 2-3 inches all around the hernia sac as is done in mesh repair.

**Step 2: - First suture line- Closure of hernia defect (Figure 2-3):** The entire sac is inverted in the abdomen without opening it if possible or otherwise herniotomy is done by excising the sac after reducing all contents in the abdomen. At this stage, Proper bimanual palpation of the recti muscles through the defect is done to get an idea of its location and extent of separation. If the recti muscles are weak and flabby or more separated than clinically expected then Type B operation was done without opening the rectus canal and without midline suture of the recti muscles. Otherwise, proceed to do Type A operation. Hernia defect is closed *horizontally* with no.1 non-absorbable interrupted vertical mattress sutures. Closure of the defect is done by taking sutures near to the medial borders of the recti muscles through the strong aponeurotic tissues only. There is no tension seen on those sutures but normal physiological tension or even mild tension on those sutures is also acceptable and does not affect the outcome because the tension is distributed across many interrupted sutures in 4 separate layers just as is in Shouldice repair for inguinal hernias.

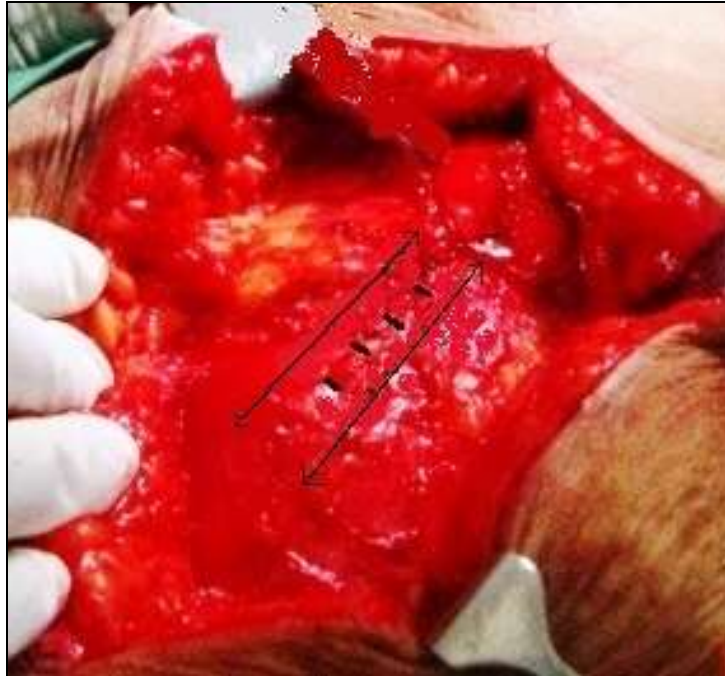

**Fig. 2.** Hernia defect held up with 2 forceps after excision of hernia sac and anterior rectus sheath being cleared for 2 inches all around the hernia defect

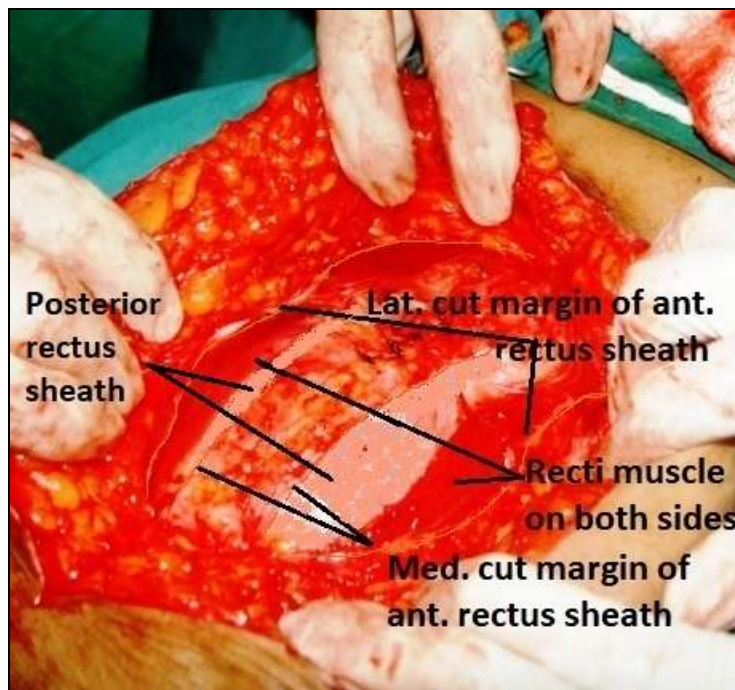


**Fig. 3.** Hernia defect is closed with interrupted vertical mattress sutures

**Step 3: - Rectus canals opened on either side (Figure 4, 5):** Rectus canal is opened by making a parallel vertical incision in the anterior rectus sheath on either side as near to the closed hernia defect as possible to expose the recti muscles on both the sides. These incisions are extended cranially and caudally for about 2 inches or more as required depending on the separation of muscles present.



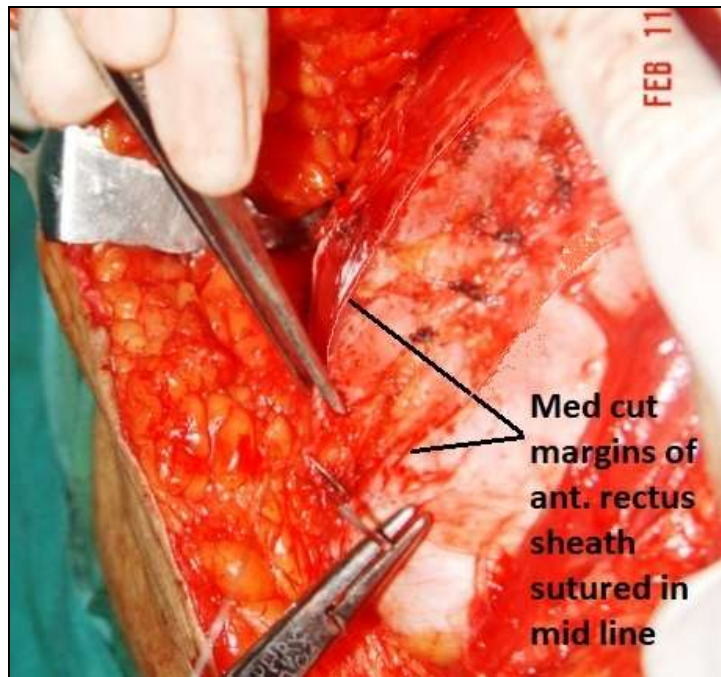
**Fig. 4.** Incision on both sides of anterior rectus sheath to open the rectus canal. Incision is extended for about 2 inches above and below the hernia defect



**Fig. 5.** Rectus canal opened on both sides showing medial and lateral cut margins of anterior rectus sheath and recti muscles on both sides

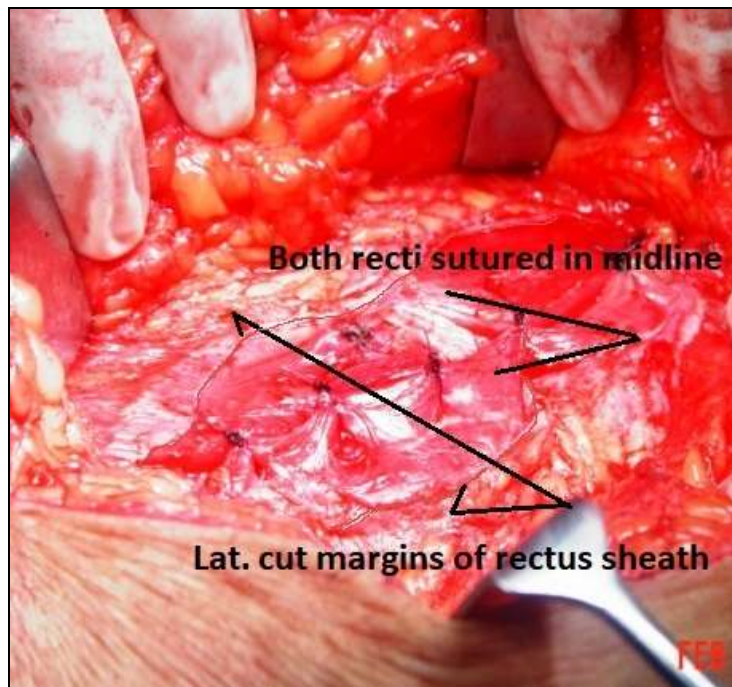
**Step 4: - Second suture line- Suturing of medial flaps- Strengthening of linea alba (Figure 6):** The medial flaps of those two incisions in the anterior rectus sheath are sutured in midline with no.1 non-absorbable

continuous sutures throughout its length to strengthen the linea alba in front, cranial and caudal to the sutured hernia defect. This will strengthen the linea alba not only in front but also above and below the hernia defect.



**Fig. 6.** Medial flaps of sheath being sutured in mid line by continuous sutures to strengthen the linea alba

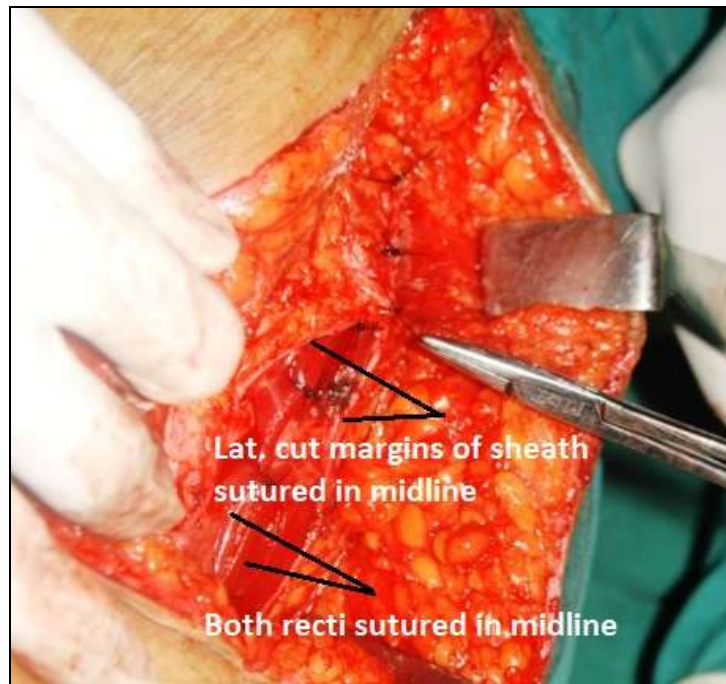
**Step 5: -Third suture line- Muscle approximation (Figure 7):** Recti muscles on either side are sutured in midline with no. '0' absorbable interrupted sutures. This muscle approximation in midline will give *physiologically dynamic protection* to the sutured hernia defect.



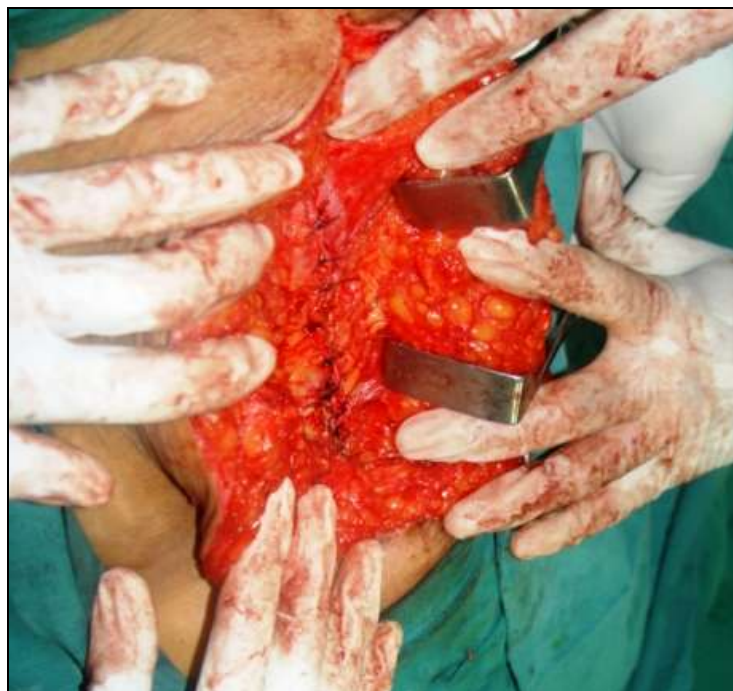**Fig. 7.** Both recti muscles are sutured in midline with interrupted sutures to give physiologically dynamic protection

**Step 6: -Fourth suture line- suturing of lateral flaps (Figure 8-9):** Approximation of lateral flaps of those two incisions in the anterior rectus sheath is done in front of the sutured muscles in the midline with no.1 non-absorbable interrupted vertical mattress sutures. This layer of the anterior rectus sheath gives natural re-

enforcement in front of the sutured hernia defect as is given by the mesh in mesh repairs and also for 2-3 inches beyond, cranial and caudal to the defect. There is no tension seen on those sutures but normal physiological tension or even mild tension on those sutures is also acceptable and does not affect the outcome because the tension is distributed across many interrupted sutures in 4 separate layers just as is in Shouldice repair for inguinal hernias. *The step 4, 5 and 6 will strengthen the linea alba, will give natural mechanical re-enforcement as is given by mesh and also will make this repair physiologically dynamic above the hernia defect, in front of the hernia defect and also below the hernia defect. This is the main crux of this repair technique.*



**Fig. 8.** Lateral flaps of anterior rectus sheath being sutured in mid line with interrupted vertical mattress sutures



**Fig. 9.** Lateral flaps of anterior rectus sheath suturing being completed

**Step 7:** - Subcutaneous fat and skin are closed as usual after proper haemostasis is done. No drainage is required to be kept if haemostasis is properly achieved.

## **2] Type B repair without mid line closure of recti muscles:**

All steps of the operation are same as above except that step 3, 4 and 5 are omitted. This is done in cases where you feel that a] either recti muscles are wide apart or weak and cannot be approximated easily in midline or b] the lateral flaps will move apart wider and cannot be easily approximated in mid line without tension.

**Step 1:** - Incision is taken as described above

**Step 2:** - Hernia sac is either inverted or excised and hernia defect is closed as described above

**Step 3:** - Now instead of opening the rectus canal by taking an incision in it as in step 3 above, anterior rectus sheath on either side of midline is directly sutured in midline in front of the closed hernia defect, cranial to the hernia defect and also caudal to the hernia defect for about 2 inches. Series of interrupted vertical mattress sutures are taken with non-absorbable no.1 sutures through this anterior rectus sheath on either side about 0.5 to 1 cm away from the midline to tighten it in the midline. This will give additional protection in front of the hernia defect as well as strengthen the linea alba cranial and caudal to the hernia defect for about 2-3 inches or as required for that patient. One more additional second layer suture line in front of this suture line can be taken if it is possible without tension. But it is not a must. These additional sutures are taken about 0.5 cm away from the previous suture line with continuous non-absorbable no.1 suture material. Bites are taken through both sides of the anterior rectus sheath and tightened in the midline throughout the incision in front of the previous suture line. *This tightening of the anterior rectus sheath in mid line will bring both recti muscles closer to or almost near to midline from its shifted lateral position to give physiologically dynamic protection. This will strengthen the linea alba, will give natural mechanical re-enforcement as is given by mesh and also bring both recti muscles closer to the midline giving additional physiological support to prevent from the recurrences.*

**Step 4:** - Subcutaneous fat and skin are closed as usual after proper haemostasis is done. No drainage is required to be kept if haemostasis is properly achieved.

### **III. Results**

Median age of the patients was 50.5 years. 88 (54.6%) were females and 73 (45.4%) were males. 142 (88.2%) patients were followed up for a median period of 4.5 year. 5 patients gave positive response to PINQ-PHONE and they all attended clinic later and were clinically examined. 160 (99.4%) patients had a stay of 1 night in the hospital. Average median hospital stay was 18 hours. Mild pain was seen in 156 (96.9%) patients and rest had moderate pain needing additional injectable analgesics during hospital stay. 151 (93.7%) patients were freely mobile in the wards within 24 hours. 158 (98.1%) patients had negligible pain and were freely mobile within a weeks' time with routine non-strenuous activities. 155 (96.2%) patients could step up strenuous activities like sports, exercises etc. after 6-8 weeks and return back to normal life style. Complications like subcutaneous hematoma in 2 (1.2%) and mild skin infection in 2 (1.2%) patients were noted. Patients needed only conservative treatment and change of antibiotic. 2 (1.2%) patients had another hernia formation, one above and one was below the repair after 1 year and 2.6 year respectively. Both these recurrences were seen in patients who were operated without mid line suture of the recti muscles (Type B). Thus, recurrence rate in this type of operation comes to 6.6% and another group of 131 patients with mid line suture of muscles (Type A) comes to 0%. None of the patients had recurrence at repair site during this follow up period.

### **IV. Discussion**

The authors technique follows the principle of a 4 layered closure of the abdominal wall using the linea alba (defect closure), medial layer of the anterior rectus sheath, muscle, and lateral layer of the anterior sheath to create a buttressed repair. Closure of the lateral layer of the anterior rectus sheath in midline gives natural mechanical protection in front, above and below the sutured hernia defect as is given by the mesh in mesh repairs. Closure of the medial layer of the anterior rectus sheath in midline strengthens the linea alba. Closure of the recti muscles in midline treats the rectus diastasis and gives physiologically dynamic protection. It means, smaller the cough smaller is the protection and stronger the cough stronger is the protection. Such repair on physiological principle gives stronger, better and long-lasting protection from the recurrences. The operation technique is simple to understand and simple to do without any complicated dissection or prosthetic material implantation. The steps of the operation are fixed and standardized so that there are minimal chances of personal error and low results even in the hands of the junior surgeons.

*The author postulates that closure of hernia defect is important but to strengthen the linea alba in front, cranial and caudal to the defect is also equally important to prevent the recurrences as is done by the tailor while stitching a torn shirt going 1-2 inches beyond the tear.* Non-closure of the midline properly had adverse effects on overall physical capacity and quality of life<sup>1</sup>. In a series of even small umbilical and epigastric hernias (<2 cm) concomitant rectus diastasis was diagnosed in 45% of patients<sup>2</sup>. Several hernias are observed in association with rectus diastasis<sup>3</sup>. If rectus diastasis is associated with midline hernias, the surgical procedure could be corrective surgery of both pathologies at the same time<sup>4</sup>. Authors' technique takes care of both, hernia as well as rectus diastasis as against mesh repairs that does not treat the rectus diastasis.

Many suture techniques have been described from simplest as Mayo's to complicated as component separation techniques, but none has proven to be satisfactory in well-performed clinical trials. Keen, Nattal, fascial, rectus-relieving incision, Cardiff and Mayo are few that are described<sup>5</sup>. The recurrence rates varied from 0–49%, depending on technique and methods of follow-up. Ramirez described the component separation technique with good personal results in large size hernias<sup>6</sup>. There is no level-1 evidence to show whether small and medium size hernias really need mesh repair<sup>7</sup>. In such cases, pain factor or foreign body sensation feeling for a life time cannot override the reduced recurrence rates. The present trend of offering laparoscopic mesh repair for small or medium size hernias is also not justified. Increased cost, expertise in lap surgery and gravity of complications far outweighs its reduced pain and other advantages if any. The evidence from the trial conducted by Luijendijk suggests that nearly one quarter of ventral hernias repaired with synthetic mesh recur within 3 years<sup>8</sup>. Complications like acute pain in <1%, chronic pain in 5-12%, recurrences in 6-10% patients, migration, rejection and seroma formation are seen associated with use of synthetic mesh, including infection of the prosthesis and the formation of enterocutaneous fistulae<sup>9</sup>. The diversity of synthetic and biologic repair materials available for the reinforcement of hernia repair complicates the selection of an appropriate prosthesis. At least 80 different prosthetic materials are available for hernia repair<sup>10</sup>.

In contrast, this study shows mild pain in 96.9% patients. 93.7% patients were freely mobile within 24 hours. 98.1% patients had negligible pain and were freely mobile within a weeks' time. Complication rate of 2.4% and recurrence rate of 1.2% was seen. No chronic pain or foreign body sensation was an added bonus to the patients. Protection starts immediately after operation. Patient can squat, climb up the staircase, carry luggage and travel or drive a car to go to office within a week as per his tolerance levels. This repair is not contra-indicated in young women wishing to keep pregnancy in future or in septic conditions. This data shows that the results of the author's technique are much superior or equal to other mesh or no mesh open or laparoscopic repairs. This technique is perfectly anatomical, risk free and simple to do and without need of any foreign prosthetic material. Therefore, the author's answer is 'no' to the questions raised in the introduction section of this article.

#### **Watchful waiting concept is not acceptable:**

The author does not understand as to who brought this concept. Does it mean that patient should wait till hernia becomes larger and gets complicated and then rush to the hospital for surgery? Assessment of hernia aperture size is of great importance in the preoperative evaluation of ventral hernia patients to consider risk for post-operative complications<sup>11</sup>. Bendavid suggested a careful attitude when applying watchful waiting concepts and when postponing hernia surgery to achieve weight loss. A delaying attitude may result in increased risk of complications caused by increasing hernia size. A small incisional hernia occurring early post laparotomy should be repaired while it is still small. These hernias almost always expand over time and extend to the entire incision leading to substantial comorbidity<sup>12</sup>.

#### **Comparison with other techniques:**

Chevrel's technique<sup>13</sup> or its modification described by E. H. H. Mommers<sup>14</sup> are using anterior rectus sheath and mesh both for repairs. It has extensive dissection with more post-operative complications (19.4%) but with improved recurrence rate (1.8%) especially in large size ventral or incisional hernias. Burger<sup>15</sup> did a comparative study on small and medium size incisional hernias treated with suture and mesh repair. Burger reported 63% recurrence in suture repair and 32% recurrence in mesh repair over a period of 10 year follow up. Only defect was treated in suture or mesh repair in those techniques. Author's technique is without mesh and strengthens the linea alba also along with defect closure with muscle approximation that results in low complication rate.

Dur's 2-layer technique<sup>16</sup> is without mesh and resembles to the author's technique. But the main difference is that the author's technique is a 4 layered repair technique as against Dur's 2-layer repair technique. Dur treats only defect whereas author's technique repairs the defect and also strengthens the midline for about 2 inches cranial and caudal to defect. Dur does not suture muscles separately but includes it in the bites taken to approximate the anterior and posterior rectus sheath. This causes more muscle damage due to multiple bites with more fibrosis and more loss of function. Whereas, Rectus muscle is sutured separately as a third layer in the author's technique preserving its function to give physiologically dynamic protection. Complication rate reported by Dur was: wound infection in 6.5%, recurrence in 4.5%, wound haematoma in 2.6%, respiratory insufficiency in 5.2% and pneumonia 6.5%. This complication rate is too high when his study included 81.4% of small and medium size hernias and only 18.6% were large hernias.

Arroyo<sup>17</sup> and Kaufmann<sup>18</sup> did comparative study on small and medium size umbilical hernias. Only defect was treated in suture repair and mesh repair in both of these studies. Arroyo reported 11% recurrence in suture and 1% in mesh repairs and Kaufmann reported 12% and 4% respectively. This was because only defect was repaired in those techniques but the strengthening of linea alba for about 2 inches above and below the



defect was not done nor muscle suture was done as is done in the authors technique to give physiologically dynamic protection and very low complication and recurrence rate.

#### **Tension or no tension on suture line:**

Mesh proponents may criticize: 1] weakness of the anterior rectus sheath due to herniation and 2] Tension on the suture line. The author confirmed in this study that hernia process does not affect the anterior rectus sheath but it is weak fascia of the linea alba or pseudo fascia. Aponeurotic structures are least affected by the aging process. There is also no tension on the suture lines. This was confirmed during surgery by the fact that none of the sutures needed holding on knots with forceps while tying the knots. And even if there is normal physiological tension or mild to moderate tension on suture line (not excessive tension) then body adopts and tissues heal without tension giving excellent results. This is because the tension gets divided on to multiple interrupted sutures at 4 separate levels of sutured layers just as is seen in Shouldice repair for inguinal hernias. And the interrupted vertical mattress sutures hold the tissues together for a longer period to heal without tear even if they are sutured under tension.

### **V. Conclusions**

Strengthening of linea alba by suturing either side anterior rectus sheath in midline in front, cranial and caudal to the sutured hernia defect gives long lasting results. In addition, approximation by suturing both recti muscles in the midline gives additional strong physiologically dynamic support. Repair of small and medium size mid line abdominal wall hernia by this 4 layer physiologically dynamic technique is perfectly anatomical and show good recovery with comparable complication and recurrence rate without any foreign body implants. Therefore, it can be recommended as a first choice of repair for the small and medium size midline ventral hernias including incisional hernias.

### **References**

- [1]. Burger JWA, Luijendijk RW, Hop WCJ, Halim JA, Verdaasdonk EGG, Jeekel J. Long-term follow-up of a randomized controlled trial of suture versus mesh repair of incisional hernia. *Ann Surg.* 2004; 240 (4): 578–585
- [2]. Köhler G, Kuketina RR, Emmanuel K. Sutured repair of primary small umbilical and epigastric hernias: concomitant rectus diastasis is a significant risk factor for recurrence. *World J Surg.* 2015; 39:121–6. <https://doi.org/10.1007/s00268-014-2765-y>
- [3]. Reinhold W, Köckerling F, Bittner R, Conze J, Fortelny R, Koch A, Kukleta J, Kuthe A, Lorenz R and Stechemesser B. Classification of Rectus Diastasis—A Proposal by the German Hernia Society (DHG) and the International Endohernia Society (IEHS). *Front. Surg.* 2019; 6:1. <https://doi.org/10.3389/fsurg.2019.00001>
- [4]. Bellido Luque J, Bellido Luque A, Valdivia J, Suarez Grau JM, Gomez Menchero J, Garcia Moreno J, et al. Totally endoscopic surgery on diastasis recti associated with midline hernias. The advantages of a minimally invasive approach. Prospective cohort study. *Hernia.* 2014; 19:493–501. <https://doi.org/10.1007/s10029-014-1300-2>
- [5]. Cassar K, Munro A. Surgical treatment of incisional hernia. *Br J Surg.* 2002; 89: 534–545
- [6]. Ramirez OM, Ruas E, Dellon AL. “Components separation” method for closure of abdominal wall defects: an anatomic and clinical study. *Plast Reconstr Surg.* 1990; 86: 519–526
- [7]. Van t Riet M, Steyerberg EW, Nellensteyn J, Bonjer HJ, Jeekel J. Meta-analysis of techniques for closure of midline abdominal incisions. *Br J Surg.* 2002; 89: 1350–1356
- [8]. Luijendijk RW, Hop WC, van den Tol MP, de Lange DC, Braaksma MM, IJzermans JN, et al. A comparison of suture repair with mesh repair for incisional hernia. *N Engl J Med.* 2000; 343:392-8.
- [9]. Voyles CR, Richardson JD, Bland KI, Tobin GR, Flint LM, Polk HC Jr. Emergency abdominal wall reconstruction with polypropylene mesh: short-term benefits versus long-term complications. *Ann Surg.* 1981; 194:219-23.
- [10]. Kingsnorth A, LeBlanc K. Hernias: inguinal and incisional. *Lancet.* 2003; 362:1561-71.
- [11]. Mikael Lindmark, Karin Strigard, Thyra Lo wenmark, Ursula Dahlstrand, Ulf Gunnarsson. Risk Factors for Surgical Complications in Ventral Hernia Repair. *World J Surg.* 2018 <https://doi.org/10.1007/s00268-018-4642-6>
- [12]. Bendavid R. Abdominal wall hernias, principles and management. 2001; Springer, New York.
- [13]. Chevrel JP, Dilin C, Morquette H. Traitement des éventrations abdominales médianes par autoplastie musculaire et prothèse pré-musculo-aponévrotique. *Chirurgie.* 1986; 112(9):616–622
- [14]. E. H. H. Mommers, B. J. M. Leenders, W. K. G. Leclercq, T. S. de Vries Reilingh, and J. A. Charbon. A modified Chevrel technique for ventral hernia repair: long-term results of a single centre cohort. *Hernia.* 2017; 21(4): 591–600
- [15]. Jacobus W.A. Burger, Roland W. Luijendijk, Wim C.J. Hop, Jens A. Halm, Emiel G.G. Verdaasdonk, Johannes Jeekel. Long-term Follow-up of a Randomized Controlled Trial of Suture Versus Mesh Repair of Incisional Hernia. *Ann Surg.* 2004 Oct; 240(4): 578–585
- [16]. A. H. M. Dur, D. den Hartog, W. E. Tuinebreijer, R. W. Kreis, and J. F. Lange. Low recurrence rate of a two-layered closure repair for primary and recurrent midline incisional hernia without mesh. *Hernia.* 2009 Aug; 13(4): 421–426.
- [17]. A. arroyo, P. Garcia, F. Perez, J. Andreu, F. Candela, R. Calpena. Randomized clinical trial comparing suture and mesh repair of umbilical hernia in adults. *Br J Surg.* 2001; Oct 88(10); 1321-3
- [18]. Ruth Kaufmann et al. Mesh Versus Suture Repair of Umbilical Hernia in Adults: A Randomised, Double-Blind, Controlled, Multicentre Trial. *Lancet.* 2018 Mar 3;391(10123):860-869. doi: 10.1016/S0140-6736(18)30298-8. Epub 2018 Feb 17.