

Cell Based Therapy for Ocular Surface Reconstruction

Dr. Ashish Joshi (M.S.), Dr. Rajat Jain (M.S. FICO)

Date of Submission: 20-09-2020

Date of Acceptance: 04-10-2020

Ocular surface reconstruction involves an entire gamut of modalities, both medical and surgical. The principal goals of medical therapy would be supplementation of the tear film, suppression of inflammation, limitation of tissue destruction and promotion of epithelial wound healing. The surgical approaches and techniques are varied and often performed as staged procedures. In this communication, we discuss the principles in the approach to the management of limbal stem cell deficiency disorders.

Relevant anatomy of the ocular surface

The ocular surface functional unit consists of stratified squamous corneal epithelium, limbal epithelium covering the junction between corneal and conjunctival epithelium, mucin producing conjunctival epithelium, muco-cutaneous junction of the lids which helps in the proper spread of the tear film, lipid secreting meibomian glands, aqueous secreting lacrimal glands and functioning eyelids.

It acts as an interface between the eye and the outer world and is unique that it is not protected by skin. The normal functioning of the ocular surface requires an adequate tear film, normal ocular adnexa, normal corneal sensitivity and functioning limbal stem cells and hence a normal corneal epithelium (Figure 1).

The limbus predominantly has two functions. It acts as a barrier between the avascular, smooth, non-keratinized and goblet cell-free corneal epithelium and a mucin secreting, goblet cell rich conjunctival epithelium. It is also the source of regenerating epithelial cells, from the stem cells, and helps in maintaining of the corneal epithelium¹⁻⁴.

Stem cells, present in all self-renewing tissues, are a small subpopulation of specialized undifferentiated, self-renewing cells with a slow cell cycle, long life span, a high capacity for error-free self renewal and a capability for asymmetric division¹⁻⁴. They are capable of indefinite

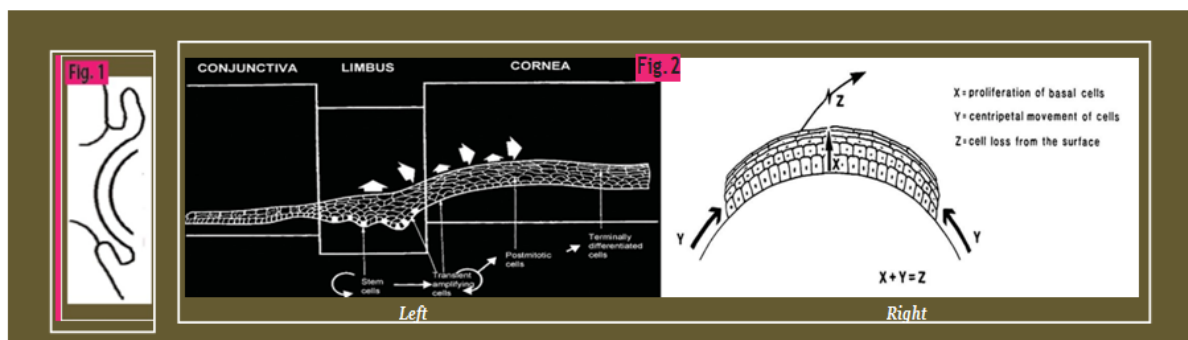


Figure 1: Figure showing the ocular surface which includes the tear film, eyelashes, eyelid margins, meibomian glands and epithelial surfaces of conjunctiva and cornea

Figure 2: (Left) Anatomy of the limbus and the lineage of 'Stem cells'; (Right) XYZ hypothesis

Table 1: Etiological Classification of Limbal Stem Cell Deficiency (LSCD)

Primary LSCD	Secondary LSCD
Aniridia	TRAUMA
Multiple Endocrine Deficiency	Chemical—Acid and Alkali
Sclerocornea	Thermal—Heat and Steam
Erythrokeratoderma	Radiation burns
	Iatrogenic
	Multiple ocular surgeries
	Cyclocryotherapy
	Use of topical Mitomycin C
	Systemic chemotherapy
	OCULAR Diseases
	Post infectious keratitis
	Neurotrophic keratitis
	Keratoconjunctivitis sicca
	Severe (limbal) Vernal Keratoconjunctivitis
	OSSN, Pterygium excision
	Chronic contact lens use
	IMMUNE mediated (Systemic)
	Mucous Membrane Pemphigoid
	Stevens Johnson Syndrome
	Vitamin A Deficiency
	Idiopathic

¹⁸Reproduced with permission

proliferation to a large number of differentiated progeny, responsible for cellular replacement and regeneration⁵⁻⁷. Though there are no direct markers for the stem cells, clinical⁸ and experimental evidence⁹⁻¹³ proves that the corneal stem cell niche lies at the limbus, in the palisades of Vogt^{14,15,16} (Figure 2 Left).

The asymmetric cell division of the limbal stem cells (SC) allows one of the daughter cells to remain a stem cell while the other cell differentiates to become a transient amplifying cell (TAC) located in the corneal epithelial basal layer. Both SCs and TACs are regarded as progenitor cells and they give rise to post-mitotic cells (PMC) and finally to terminally differentiated cells (TDC). The latter two cell types are incapable of further cell division³. The corneal epithelium is thus maintained by the balance of proliferation of basal epithelial cells (X) and proliferation and centripetal migration of limbal epithelial cells (Y) with the loss of epithelial cells from the surface (Z). This

was proposed by Thoft and Friend in 1983 as the 'XYZ hypothesis' ($X+Y=Z$)¹⁷. To ensure the normal health of the tissue, cellular proliferation and differentiation in a coordinated manner at different levels of this hierarchy is indispensable (Figure 2-Right).

Limbal Stem Cell deficiency and classification

Inflammatory, infectious, traumatic or congenital insult to these limbal cells may lead to limbal stem cell deficiency (LSCD). Limbal stem cell dysfunction should be differentiated from limbal stem cell destruction. Limbal stem cell dysfunction is usually primary or hereditary where the stem cells never achieve their normal function. The condition is usually bilateral and less severe as the rest of the ocular surface may be normal (e.g. aniridia, keratitis associated with multiple endocrinal deficiencies). Limbal stem cell destruction is an acquired loss of functioning limbal stem cells. The condition can be unilateral or bilateral and is associated with severe ocular surface damage (e.g. chemical or thermal burns, Stevens Johnson Syndrome, Ocular cicatricial pemphigoid, multiple surgeries, chronic contact lens wear, etc.)^{1,18,19}. LSCD could also be partial, focal loss of limbal stem cells with rest of the limbus being normal or total where there is total loss of limbal stem cells¹. The etiological classification of LSCD is given in Table 1.

Acute or chronic inflammatory damage to the stem cells makes it less capable of healing and leads to severe scarring of the cornea, conjunctiva or the eyelids. In advanced cases there may be destruction of the tear forming lacrimal glands leading to a dry ocular surface with progressive dermalization or formation of a skin like rough surface as seen in Stevens Johnson's Syndrome and Ocular Cicatricial Pemphigoid.

LSCD - clinical features

The histological hallmark of LSCD is the presence of conjunctival goblet cells on the corneal epithelium. Impression cytology of the perilimbal area with nitrocellulose acetate paper can detect the presence of goblet cells on the cornea^{20,21,22}. However, the diagnosis of LSCD can usually be established clinically and histological studies are not required. Patients usually complain of redness, irritation, foreign body sensation, photophobia decreased vision and blepharospasm. The clinical hallmark of LSCD is a triad of signs: conjunctivalisation, neovascularisation and chronic inflammation²³⁻²⁶. The fluorescein-stained conjunctivalised cornea has a stippled appearance²⁷⁻²⁸ and there may be loss of palisades of Vogt in an area known to have palisades prior to the insult²⁹⁻³⁰. In unilateral cases, it is useful to compare the limbus in the affected quadrants with the corresponding areas of the unaffected fellow eye. Other features include recurrent and persistent epithelial defects, superficial vascularisation, scarring, thick fibrovascular pannus, ulceration, melting and perforation¹⁸.

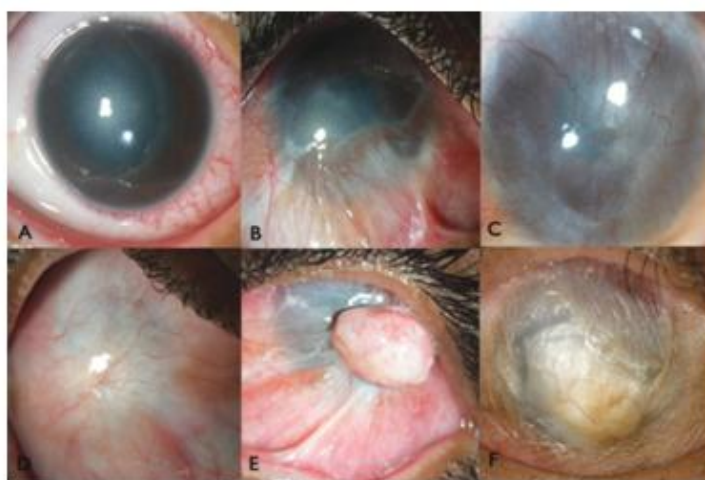

Figure 3: Composite showing acute chemical injury with an epithelial defect, corneal edema and surrounding limbal involvement (A); partial limbal stem cell deficiency (LSCD) with central corneal scarring (B); total LSCD with fine pannus on the cornea (C); total LSCD with thick pannus covering the whole corneal surface (D); total LSCD with granuloma, (E); total LSCD in a bone dry ocular surface in a patient of Stevens Johnson Syndrome (F)

Figure 3 represents a composite of figures representing varying degree of LSCD.

Goals and Principles of management

The limbal stem cells are limited in number and do not regenerate. This makes the deficiency of limbal stem cells impossible to treat by pharmacological means. The management of LSCD includes restoration of the damaged ocular surface followed by subsequent definitive visual rehabilitation, if required¹⁸.

Perhaps, the most important step in LSCD management is to minimize the initial damage during the acute phase of inflammation. Control of ocular surface inflammation with the use of topical steroids and preservative free lubricating eye drops is advocated³¹. The various benefits of amniotic membrane grafting in acute stage of chemical/thermal burn or Stevens Johnson Syndrome has been established beyond doubt³²⁻³⁸. In the authors experience, this simple surgical technique has a huge bearing on the long-term outcome of the ocular disease.

Active inflammation could be detrimental to the transplanted stem cells. Hence, any surgical treatment in an inflamed eye will not give desired results. The success of limbal transplantation further depends on concomitant lid pathology, dry eye and uncontrolled systemic disorders. Hence, the management of LSCD also involves the treatment of associated adnexal conditions, management of dry eye and management of systemic diseases¹⁸. A detailed description of these conditions is outside the scope of this review.

The deficiency of functional epithelial stem cells that occurs in these conditions is not met by corneal transplantation.

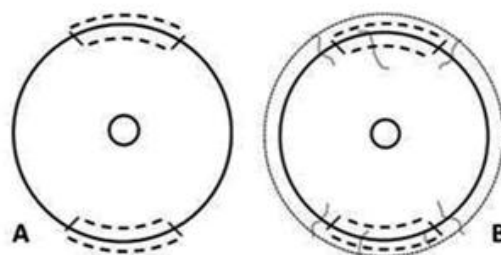


Figure 4: Slit lamp image of limbal auto grafting with outcome

(A): Schematic representation of the donor eye. The dotted lines represent the sites from which the donor conjunctival limbal auto graft is harvested (B): Schematic representation of the recipient eye- intra-operative appearance. The donor tissue is anchored to the recipient bed in the correct anatomical orientation with 10-0 monofilament nylon. Previous studies have found that only 33 to 46% of corneal grafts survive for one year and none survives after 3 years after transplantation in eyes with ocular surface damage³⁹. This is in contrast to more common indications like corneal scars or keratoconus where the one year corneal graft survival is more than 80%⁴⁰. The management of limbal stem cell deficiency depends on whether the condition is unilateral or bilateral, involving the visual axis and whether the ocular surface is wet or dry.

We describe below a review of the different cell based management strategies for ocular surface reconstruction.

Unilateral Limbal Stem Cell deficiency

1. **Limbal AUTOGRAFTING:** The discovery of putative epithelial stem cells in the palisades of Vogt located in the limbus marked the beginning of the era of cell based therapy for the ocular surface reconstruction¹¹⁻¹⁶. Tsai RJ, et al conducted the first pre-clinical animal trial comparing the outcome of limbal and conjunctival autograft transplantation in corneal surface reconstruction and proved that limbal transplantation had a better efficiency than conjunctival transplantation in restoring a destroyed corneal surface⁴¹. Subsequently, Kenyon and Tseng for the first time in 1989 transplanted two free limbal grafts that encompassed 8 clock hours of the recipient limbus from the apparently healthy contralateral eye to and proved that the corneal surface could be regenerated by performing limbal transplantation⁴². Multiple reports of limbal autografting for ocular surface disorders were then published⁴³. Table 2 describes the clinical outcomes and complications of different reports on limbal autografting. While autografting had the obvious advantage of no risk of immunological rejection and hence no need for long-term systemic immunosuppression, many reports of iatrogenic donor site LSCD were however published^{44,47} (Figure 4).

Table 2: Clinical OUTCOMES and complications reported in STUDIES on Limbal AUTO-GRAFTING							
Author	Year	N	Donor tissue (Clock hours)	Clinical Success (%)	2-line vision gain (%)	Complications (n)	Follow-up (years)
							Mean (Range)
Kenyon et al ⁴²	1989	26	4	77	65	None	18 (2 to 45)
Morgan et al ⁴³	1996	6	2 to 3	83	83	Donor site micro-perforation (1)	NA (3 to 24)
Tan et al ⁴²	1996	9	2 to 4	77	77	LSCD in donor eye (1)	27.1 (2.5 to 46)
Frucht-Pery et al ⁴⁵	1998	9	3 to 6	100	100	None	NA (15 to 60)
Basti et al ⁴⁶	1999	3	4 to 5	100	100	Donor site conjunctivalization (1)	NA (9 to 15)
Rao et al ⁴⁷	1999	16	2 to 3	94	82	None	19.3 (3 to 45)
Dua et al ⁴⁸	2000	6	2 to 4	100	83	Filmentary keratitis (1)	18.8 (14 to 31)
Ozdemir et al ⁴⁹	2004	15	NA	87	80	None	13.9 (3 to 24)
Santos et al ⁵⁰	2005	10	4	80	61	None	33 (NA)
Miri et al ⁵¹	2010	12	4	100	81.3	None	3.9 (1 to 10)

Miri et al ⁵²	2011	25	2 to 4	NA	NA	Filamentary keratitis (4), Donor site conjunctivalization (17)	41 (3 to 127)
Welder et al ⁵³	2012	4	1.5 to 2	100	100	Nil	1.8 (0.6-2.6)

2. *Ex-vivo CULTIVATION of AUTOLOGOUS limbal epithelial cells (CULTIVATED Limbal Epithelial Transplantation- CLET)*: The concerns regarding donor site complications prompted the possibility of obtaining smaller biopsy and expanding the cells ex-vivo on a suitable substrate before transplanting them onto the affected eye. Since Pellegrini and co-workers⁵⁴ first described their technique, several groups around the world have described various techniques of culturing limbal stem cells. The technique of cultivation could either be a suspension culture or an explant culture. Xenogenic constituents of a limbal culture system may be in the form of murine feeder cells⁵⁵⁻⁵⁷, fetal bovine serum (FBS)⁵⁵⁻⁵⁹ or animal-derived growth factors⁶⁰. Table 3 describes the clinical outcomes of reported studies on autologous cultivated limbal epithelial transplantation using such animal-derived growth factors. Animal derived products in a cell culture system always have a theoretical risk of infection, rejection

or acquisition of prion diseases. Elimination of feeder cells and use of autologous human serum as an alternative to FBS is therefore desirable. The authors have developed a cost-effective and safer xeno-free and feeder-free explant culture system that uses autologous serum, recombinant enzymes and human growth factors and is devoid of animal-derived products. It is a submerged culture technique which also promotes stem cell maintenance. *The surgery, in brief, consists of the following steps:* a 2x2 mm biopsy is taken from the superior limbus. The conjunctiva is incised and a sub-conjunctival dissection is continued until limbus is reached. Subsequently, a shallow dissection is carried out 1 mm into the clear cornea. The tissue is transported to the laboratory in human corneal epithelium (HCE) medium. Under strict aseptic conditions, the donor limbal tissue is shredded into small pieces. Indigenously prepared human amniotic membrane (hAM), is used as a carrier. It sheet is de-epithelised and the shredded

Table 3: Clinical OUTCOMES of reported STUDIES on AUTOLOGOUS CULTIVATED limbal epithelial transplantation USING Animal-derived growth factors

Author	Year	Culture Technique	Substrate	Eyes	Clinical Success (%)	2-line visual gain (%)	Follow-up (months) Mean (Range)	
Pellegrini et al ⁵⁴	1997	Suspension	3T3s	2	100	50	24	NA
Schawb et al ⁶⁰	1999	Suspension	hAM	17	76	16	10	2-24
Schawb et al ⁶¹	2000	Suspension	hAM	10	60	36	13	6-19
Tsai et al ⁶²	2000	Explant	hAM	6	100	50	15	12-18
Rama et al ⁶³	2001	Suspension	Fibrin	18	74	33	17.5	12-27
Grueterich et al ⁶⁴	2002	Explant	hAM	1	100	100	21	NA
Sangwan et al ⁶⁵	2003	Explant	hAM	2	100	50	29.5	25-34
Nakamura et al ⁶⁶	2004	Explant	hAM	1	100	100	19	NA
Sangwan et al ⁵⁸	2006	Explant	hAM	88	73	37	29.5	25-34
Kawashima et al ⁶⁷	2007	Explant	hAM	2	100	67	23	5-41
Shortt et al ⁶⁸	2008	Suspension	hAM	3	67	33	6	1-10
Gisoldi et al ⁶⁹	2010	Suspension	Fibrin	6	83	83	24	11-34
Rama et al ⁷⁰	2010	Suspension	Fibrin	107	68	54	35	12 to 120
Di Iorio et al ⁷¹	2010	Suspension	Fibrin	166	80	NA	29.9	6-50
Pauklin et al ⁷²	2010	Explant	hAM	30	77	73	28.5	10-72
Barandan-Rafii et al ⁷³	2010	Explant	hAM	8	88	63	34	6-48
Meller et al ⁷⁴	2010	*** (full text not available)	hAM	30	76.7	NA	28.9	NA
Thanos M, et al ⁷⁵	2010			1	100	100	28	NA
Prabhaswat et al ⁷⁶	2012	Explant	hAM	12	58.3	NA	25.8	6-46
Marchini et al ⁷⁷	2012	NA	Fibrin	16	71.3	50	NA	12-50
Sharma S et al ⁷⁸	2013	*** (full text not available)		4	100	# needed DALK	19.5	9-26

Table 4: Clinical OUTCOMES of reported STUDIES on AUTOLOGOUS CULTIVATED limbal epithelial transplantation USING completely xeno-free CULTIVATION TECHNIQUES

Author	Year	Culture Technique	Substrate	Eyes	Clinical Success (%)	2-line visual gain (%)	Follow-up (months)	
							Mean	Range
Nakamura et al ⁷⁹	2006	Explant	hAM	2	100	67	15	14-16
Shimakazi et al ⁸⁰	2007	Explant	hAM	16	50	37.5	30	6-86
Di Girolamo et al ⁸¹	2009	Explant	CL	2	100	50	10	8 - 13
Kolli et al ⁸²	2010	Explant	hAM	8	100	63	19	12-30
Sangwan et al ⁸³	2011	Explant	hAM	200	71	60.5	34	12-91
Subramaniam SV et al ⁸⁵	2013	Explant	hAM	40	NA*	NA*	33	1-87
Sejpal K et al ⁸⁶	2013	Explant	hAM	107	46.7	54.2	41.2	12-118

bits of limbal tissue are explanted over the centre of de-epithelised hAM with the basement membrane side up. A similar parallel culture is also prepared as a backup. The culture is incubated at 37⁰C with 5%

CO₂ and 95% air. The culture is completed when a monolayer of the cells growing from the explants became confluent, typically in 10 to 14 days^{83,84}. In the recipient eye, a 360⁰ peritomy is performed and

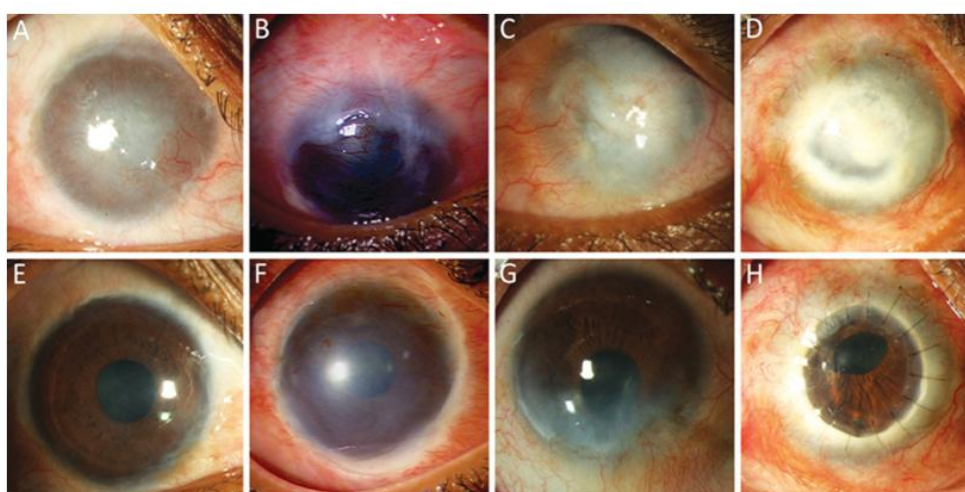


Figure 5: CLET - Clinical photographs of eyes before and after autologous cultivated limbal epithelial transplantation. Eyes of four different patients with total limbal stem cell deficiency and variable amounts of corneal stromal scarring (A to D); same eyes 1 year after limbal transplantation (E to H); Right eye of a 26-year-old female patient with a history of alkali injury showing a stable corneal surface, minimal stromal scarring and a best-corrected visual acuity (BCVA) of 20/30 (E). Right eye of a 19-year-old male patient with a history of acid injury showing a stable corneal surface with residual stromal scarring with a BCVA of 20/100 (F). Right eye of a 45-year-old male patient with a history of alkali injury showing recurrence of conjunctivalisation inferiorly (failure) between 4 and 7 o'clock at the limbus, with a BCVA of 20/40 (G). Right eye of a 37-year-old female patient with a history of acid injury showing a stable corneal surface and a clear corneal graft with a BCVA of 20/20 (H). Reproduced with permission from Br J Ophthalmol. 2011;5:1525-9.

the vascular pannus covering the cornea is removed. Bleeders are cauterized. Human amniotic membrane (hAM) graft is then placed over the bared ocular surface and is secured with fibrin glue (TISSEEL Kit from Baxter AG, Vienna, Austria). The donor tissue is then cut into eight to ten small pieces and these limbal transplants are placed, epithelial side up, on the hAM, sparing the visual axis. These transplants are also fixed in place with fibrin glue. A soft bandage contact lens is placed on the recipient eye.

Table 4 describes the outcomes of reported studies on autologous cultivated limbal epithelial transplantation using a completely xeno-free explant culture technique. Although, comparing success rates among different culture techniques may be misleading as the indications for surgery, sample size, and follow-up duration are variable among different studies; it does appear there is no clinical advantage that one technique has over the other (Figure 5).

3. In-vivo CULTIVATION of AUTOLOGOUS limbal epithelial cells: Sangwan et al⁸⁷ proposed a novel simplified technique of limbal transplantation, In-vivo Cultivation of autologous limbal epithelial cells (Simple Limbal

epithelial Transplantation -SLET), which combines the advantages of conjunctival limbal autografting (CLAU) and cultivated limbal epithelial transplantation (CLET) by being a single-stage, easily affordable procedure which utilizes a minimal donor tissue and does not need a stem cell laboratory for cultivation of limbal epithelial cells. The surgical steps were similar to those of CLET. A 2x2 mm limbal biopsy is harvested, in the similar fashion as described earlier, and is placed in balanced salt solution. In the recipient eye, human amniotic membrane (hAM) graft is then placed over the bared ocular surface and is secured with fibrin glue (TISSEEL Kit from Baxter AG, Vienna, Austria). The donor tissue is subsequently cut into eight to ten small pieces and these limbal transplants are placed, epithelial side up, on the hAM, sparing the visual axis. These transplants are also fixed in place with fibrin glue. A soft bandage contact lens is placed on the recipient eye (Figure 6).

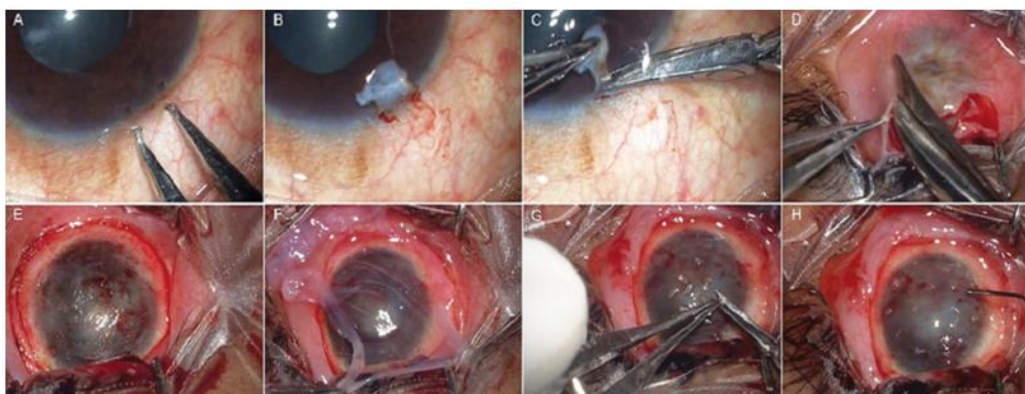


Figure 6: Composite of intra-operative photographs describing the surgical steps of Simple Limbal Epithelial Transplantation (SLET). (A): 2x2 mm area is marked in superior limbus of the donor eye; (B): sub-conjunctival dissection is carried out 1 mm into the clear cornea; (C): The limbal tissue is excised; (D, E): peritomy is performed and fibrovascular pannus is excised from the recipient ocular surface; (F): human amniotic membrane graft is placed on the bare ocular surface and secured with fibrin glue; (G, H): donor limbal tissue is cut into eight to ten small pieces and secured to amniotic membrane overlying the cornea with fibrin glue. (Reproduced with permission from

Br J phthalmol.2012;96(7):931-4)

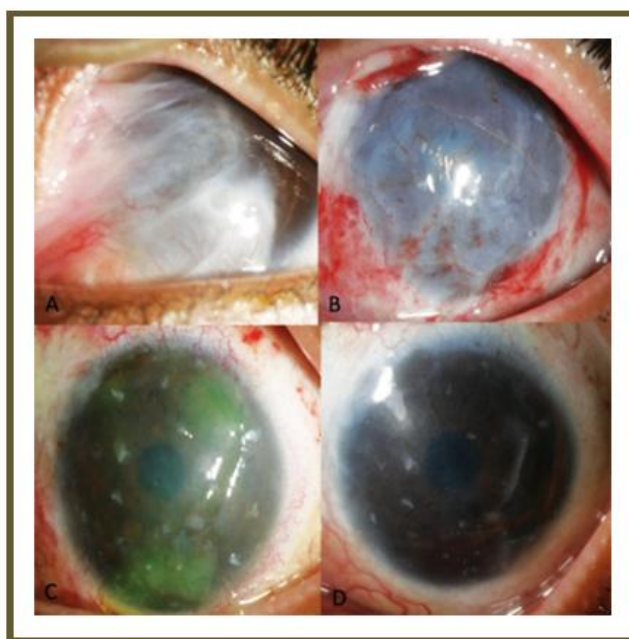


Figure 7: Composite showing a patient of chemical injury induced LSCD who underwent SLET. (A): Pre-operative image showing limbal stem cell deficiency with symblepharon formation; (B): In-vivo cultivation of limbal stem cells (SLET) - post-operative day 1 picture showing explants in place on an intact amniotic membrane; (C): post-operative day 14 picture showing explants in place, cornea getting clear and an amniotic membrane which is degenerating, best corrected visual acuity – 20/200; (D): post-operative 2 months image showing a relatively clear cornea with remnants of explants in place, best corrected visual acuity – 20/30

In the only study published on SLET thus far,⁸⁷ the authors treated 6 patients of unilateral and total limbal stem cell deficiency following ocular surface burns. A completely epithelialised, avascular and stable corneal surface was seen in all recipient eyes by 6 weeks and was maintained at a follow-up of 9.2 ± 1.9 months. Subsequently isolated case reports have been published for this technique⁸⁸⁻⁹⁰. Although long-term results are awaited, simple limbal epithelial transplantation promises to be an easy and effective technique for treating unilateral limbal stem cell deficiency following ocular burns (Figure 7).

Bilateral Limbal Stem Cell Deficiency

1. **Allogenic transplantation:** In eyes with bilateral LSCD, there is no autologous source of limbal cells which can be used for therapy. These patients can either be treated with allogenic limbal transplantation, from living (related or unrelated) or cadaveric donors, or with autologous transplantation of epithelial cells of a different lineage, like oral or nasal mucosa. Living donors are preferable as limbal cells obtained from cadavers have a lower proliferative rate in vitro⁹¹ and a poorer corneal epithelisation rate in vivo^{92,93}. Table 5 describes the clinical outcomes reported in studies on allogenic cultivated limbal epithelial transplantation (Figure 8). The advantage of autologous transplantation of oral or nasal mucosa is that there is no risk of immunological

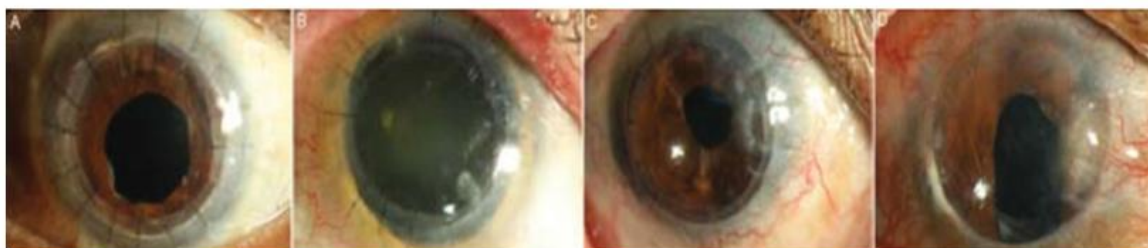

Figure 8: Postoperative clinical photographs of four eyes that underwent allogeneic cultivated limbal epithelial transplantation, followed by penetrating keratoplasty (PK) for limbal stem cell deficiency (LSCD). (Reproduced with permission from Br J Ophthalmol 2012;96:1504–1509)

Table 5: Clinical OUTCOMES reported in STUDIES on Allogenic CULTIVATED Limbal Epithelial Transplantation

Author	Year	Donor	Method	Xeno-Free	N	Success (%)	Follow-Up (months)
Tsai et al ⁹⁴	1994	Cadaveric	NA	NA	16	62.5	18.5 (NA)
Tan et al ⁹⁵	1996	Cadaveric	NA	NA	9	77.7	14.7
Schwabb, et al ⁶⁰	1999	LR	Suspension	No	2	50	13 (16-19)
Schwabb, et al ⁶¹	2000	LR	Suspension	No	4	100	10.5 (2-24)
Koizumi, et al ⁹⁶	2001	Cadaveric	Explant	No	13	92	11.2 (9-13)
Koizumi, et al ⁹⁷	2001	Cadaveric	Explant	No	3	100	6
Shimazaki et al ⁹⁸	2002	Cadaveric			13		
Nakamura, et al ⁹⁹	2003	Cadaveric	Explant	No	3	100	13 (12-14)
Sangwan, et al ¹⁰⁰	2005	LR	Explant	Yes	4	100	15.3 (7-24)
Daya, et al ¹⁰¹	2005	1 LR, 9 Cadaveric	Suspension	No	10	70	28 (12-50)
Nakamura, et al ⁷⁹	2006	Cadaveric	Suspension	No	7	100	14.6 (6-26)
Shimazaki, et al ¹⁰²	2007	7 LR, 7 Cadaveric	Explant	Yes	20	50	29 (6-85)
Ang, et al ¹⁰³	2007	Cadaveric	Suspension	No	1	100	48
Kawashima et al ⁶⁷	2007	LR 1, Cadaveric 3	Explant	Yes	4	100	26 (15-33)
Shortt, et al ⁶⁸	2008	Cadaveric	Explant	No	7	71	10 (6-13)
Meller, et al ¹⁰⁴	2009	HLA-Donor	Explant	Yes	1	100	31
Pauklin, et al ⁷²	2010	4 LR, 10 Cadaveric	Explant	No	14	50	28.5 (9-72)
Miri A et al ¹⁰⁵	2010	9 LR, 6 Cadaveric	Non cultivated, Allolimbal transplantation		15	NA	30.8 (13-96)
Basu S et al ¹⁰⁶	2011	LR	Explant	Yes	28	71.4	58 (2-114)

rejection and hence no need for systemic immunosuppression, unlike allogenic transplantation. However, these transplanted cells often maintain their original phenotype, invite vascularization and therefore provide poor visual outcomes.

2. **CULTIVATED Oral MUCOSAL Epithelial Transplantation (COMET):** There had been earlier attempts of autografting in bilateral LSCD with different non-corneal lineages¹⁰⁷⁻¹¹⁰ until Nakamura et al^{111,112} developed the cultivated oral mucosal epithelial transplantation (COMET) procedure. It is a safe and effective means of managing patients with severe bilateral LSCD following chemical injuries with good clinical outcome in terms of ocular surface stabilization, symptomatic relief and a marginal improvement in visual acuity. Table 6 enumerates the different studies published for COMET in bilateral LSCD.

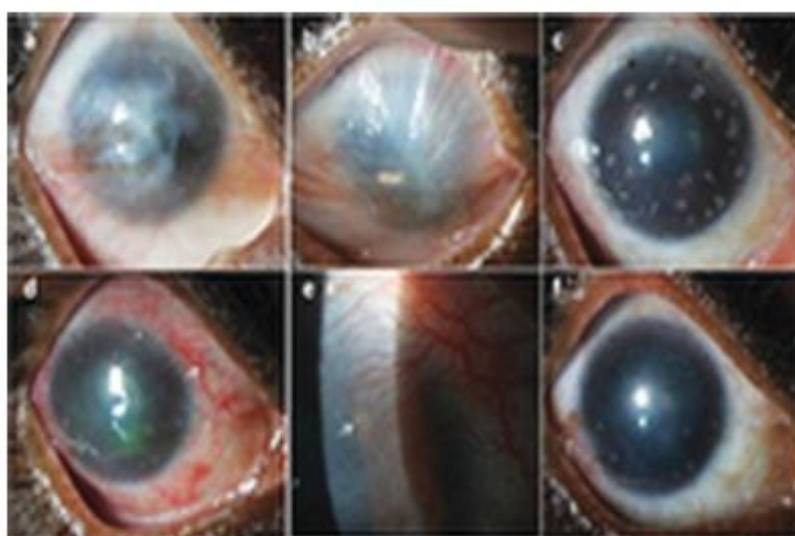


Figure 9: Preoperative (a,b): clinical photograph of right and left eye showing bilateral limbal stem cell deficiency. (c): Post-operative view of right eye showing an epithelialised central cornea with residual deep stromal scarring and few limbal transplants persisting over the cornea. (d): Circumcorneal congestion with engorged, tortuous perilimbal vessels

(arrow) and 360° peripheral superficial corneal neovascularisation. (e): Fine vascular ingrowths from the perilimbal area approaching the peripheral limbal transplants (arrow). (f): Well epithelialised ocular surface with decrease in congestion and persistence of neovascularisation following systemic immunosuppression.

(Reproduced with permission from BMJ Case Rep.

2013 Mar 14;2013.

Authors have earlier also performed allogenic (cadaveric) SLET for bilateral limbal stem cell deficiency⁹⁰. It was done in the right eye for a 41 year old female who presented one year following bilateral chemical injury with alkali. One month later her unaided visual acuity (VA) improved to 20/100 from hand-motions preoperatively with a stable, avascular and epithelialized corneal surface. Three months later, she presented with allograft rejection suggested by acute pain with peripheral corneal neovascularization encircling the transplants, engorged and tortuous peri- limbal vessels and diffuse epithelial haze. Rejection episode was reversed with pulse doses of intravenous methyl prednisolone with intensive topical steroids in a week. She recovered to her pre-rejection VA. She was later maintained on systemic immunosuppressive agents. This case describes the clinical features of allograft rejection following SLET and emphasizes the importance of continued immunosuppression in allogeneic limbal transplantation (Figure 9).

3. **Boston Keratoprosthesis:** is one of the non-cell based options in the management of bilateral LSCD. Boston type I keratoprosthesis gives superior visual outcomes in the management of corneal LSCD when compared with other treatment modalities¹²⁶. In spite of the different complications associated with this technique, like retroprosthetic membrane formation (26.7%), sterile corneal stromal necrosis (17.8%), and elevated intraocular pressure (13.9%)¹²⁷ the authors believe that it is still a safe and an effective long-term management.

Table 6: CULTIVATED Oral MUCOSAL Epithelial transplantation – COMET – for bilateral LSCD

Author	Year	Culture technique	Eyes	Clinical Success (%)	2-line visual gain (%)	Follow-up (months)	
						Mean	Range
Nakamura et al ¹¹³	2004		6	100	100	13.8	11-17
Nishida et al ¹¹⁴	2004	3t3 + MMC	4	100	100	14	13-15
Inatomi et al ¹¹⁵	2006	3t3 + MMC	15	67	67	20	3-34
Inatomi et al ¹¹⁶	2006	3t3 + MMC	2	100	0 (improved)	22.5	NA
Ma et al ¹¹⁷	2009		5	80	NA	29.6	26-34
Uchino et al ¹¹⁷	2009		1	100	100	12	NA
Chen HCJ et al ¹¹	2009		4	100	NA	14.2	10-22
Nakamura et al ¹²⁰	2011	3t3 + MMC	19	100	42	55	36-90
Satake et al ¹²¹	2011	3t3 + MMC	40	57.5	59	25.5	6-54.9
Takeda K et al ¹²²	2011	3t3 + MMC	3	67	0	30	NA
Hirayama et al ¹²³	2012	3t3 + MMC (Substrate free)	16	62.5	68.8	64	NA
Hirayama et al ¹²³	2012	3t3 + MMC (hAM)	16	37.5	43.8	85.5	NA
Burillon C et al ¹²⁴	2012		25	64	38.46	12	NA
Sotozono et al ¹²⁵	2013		46	NA	NA (Improvement in 48%)	28.7	(6.2 –85.6)

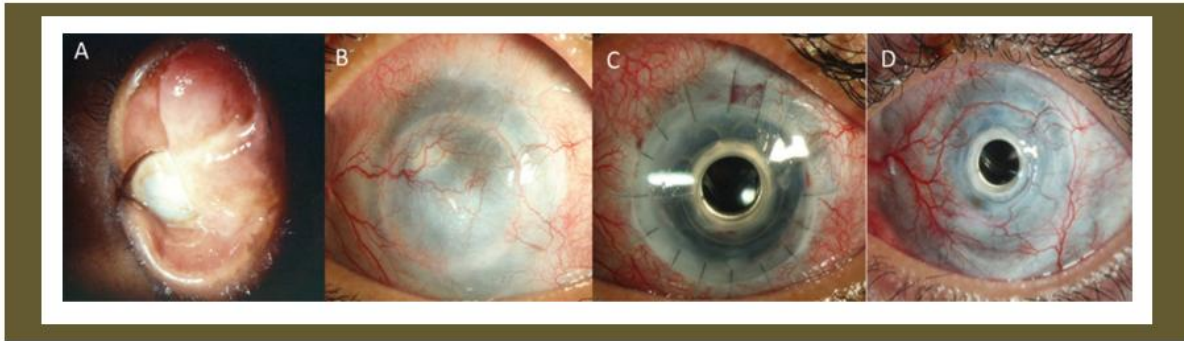


Figure 10: Composite showing a slit lamp image of left eye of a patient who had a bilateral LSCD due to chemical injury (A); image after the patient had undergone multiple penetrating keratoplasties and limbal transplantation (cadaveric and living related) procedures (B); post-operative day 1 picture after Boston Keratoprosthesis, BCVA 20/40 (C); post-operative 41 months picture after Boston Keratoprosthesis, BCVA 20/20. (D); (Reproduced with permission from BMJ Case reports 2013 May 29;2013).

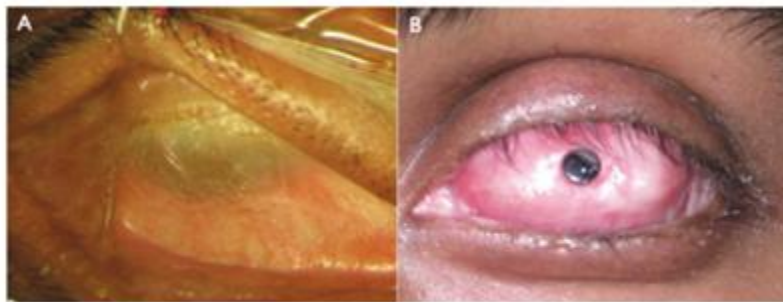


Figure 11 (A): Slit lamp image of a patient of SJS (B): who underwent MOOKP implantation

option for patients of bilateral non-immune-mediated limbal stem cell deficiency¹²⁸ (Figure 10).

4. **Osteo-Odonto Keratoprosthesis (OOKP):** For patients with bilateral LSCD with a severe dry ocular surface, Strampelli¹²⁹⁻¹³³ and Falcinelli¹³⁴ developed the OOKP. The principle of OOKP is the use of a single rooted tooth and surrounding intact alveolar bone to fashion

a plate as a carrier for a PMMA optical cylinder. The surgery involves different stages done over a period of 8-10 months. Details of the surgery are beyond the scope of this review. In a series of 234 patients, with a median follow-up from stage II of 9.4 + 5.7 years, an anatomic success of more than 94% was reported¹³⁵. Visual acuity was more than 6/18 in 52% (range 46- 72%) of the eyes with OOKP surgery. However, the most common intraoperative complication was vitreous hemorrhage (0-52%) and the most common long-term blinding complication was glaucoma (7- 47%). Endophthalmitis rates ranged from 2-8% (Figure 11).

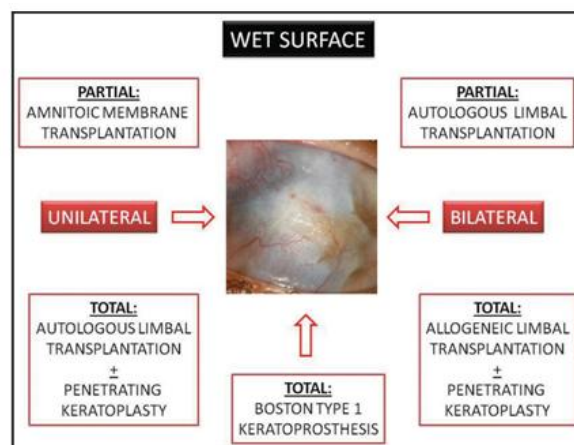


Figure 12: Authors' treatment algorithm for the management of unilateral or bilateral LSCD in a wet ocular surface

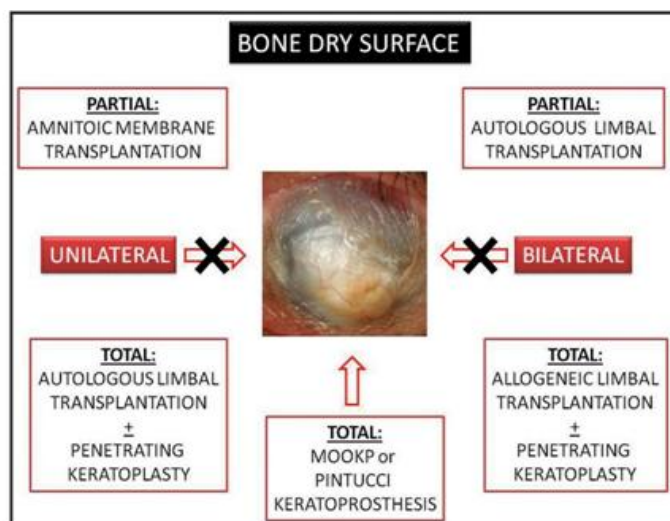


Figure 13: Authors' treatment algorithm for the management of unilateral or bilateral LSCD in an ocular surface with severe dry eye

Conclusion

Ocular surface reconstruction for the purpose of cosmetic and visual rehabilitation is a challenging prospect for both, the surgeon as well as the patient. Current knowledge of the ocular surface components and pathophysiological mechanisms has led to tremendous advancements in the management of ocular surface disorders (OSD).

The treatment algorithms given in (Figure 12&13) elucidate the authors' treatment protocols in these cases. Of the different management options discussed in this communication, In-vivo Cultivation of autologous limbal epithelial cells (SLET) and Boston Keratoprosthesis remain the authors' preference for the management of unilateral or bilateral LSCD respectively.

References

- [1]. Dua HS, Azuara-Blanco A. limbal stem cells of corneal epithelium. *Surv Ophthalmol.* 2000;44:415-25.
- [2]. Kinoshita S, Friend J, Thoft RA. Biphasic cell proliferation in transdifferentiation of conjunctival to corneal epithelium in rabbits. *Invest Ophthalmol Vis Sci.* 1983;24:1008-14.
- [3]. Leblond CP. The life history of cells in renewing systems. *Am J Anat.* 1981;160:114-158.
- [4]. Potten CS. Epithelial proliferative subpopulations. In *Stem Cells And Tissue Hemostasis*, Cambridge 1978, Cambridge university press, page 317.
- [5]. Potten CS, Leoffler M. Epithelial Cell Prolifration. Changes with time in the proportaion of isolated, paired and clustered labelled cells in sheets of murine epidermis. *Virchows Arch [B].* 1987;53:286:300.
- [6]. Potten CS, Morris RJ. Epithelial stem cells in vivo. *J Cell Sci.* 1988;10(supp):45-62.
- [7]. Pfister RR. Corneal stem cell disease: concepts, categorization and treatment by auto- and homo- transplantation of limbal stem cells. *CLAO J.* 1994;20:64-72.
- [8]. Davanger M, Evensen A. Role of pericorneal papillary structure in renewal of corneal epithelium. *Nature* 1971;229:560-1.
- [9]. Lee GA, Hirst LW. Ocular surface squamous neoplasia. *Surv Ophthalmol.* 1995;39:429-50.
- [10]. Schermer A, Galvin S, Sun TT. Differentiation-related expression of a major 64K corneal keratin in vivo and in culture suggests limbal location of corneal epithelial cells. *J Cell Biol.* 1986;103:49-62.
- [11]. Kurpakus MA, Stock EL, Jones JC. Expression of the 55-kD/64-kD corneal keratins in ocular surface epithelium. *Invest Ophthalmol Vis Sci.* 1990;31:448-56.
- [12]. Ebato B, Friend J, Thoft RA. Comparison of central and peripheral human corneal epithelium in tissue culture. *Invest Ophthalmol Vis Sci.* 1987;28:1450-6.
- [13]. Ebato B, Friend J, Thoft RA. Comparison of limbal and peripheral human corneal epithelium in tissue culture. *Invest Ophthalmol Vis Sci.* 1988;29:1533-7.
- [14]. Cotsarelis G, Cheng SZ, Dong G, Sun TT, Lavker RM. Existence of slow-cycling limbal epithelial basal cells that can be preferentially stimulated to proliferate: Implications of epithelial stem cells. *Cell* 1989;57:201-9.
- [15]. Schofield R. The stem cell system. *Biomed Pharamcother.* 1983;37:375-80.
- [16]. Schlotzer-Schrehardt U, Kruse FE. Identification and characterization of limbal stem cells. *Exp Eye Res.* 2005;81:247-64.
- [17]. Thoft RA, Friend J. The X,Y,Z hypothesis of corneal epithelial maintenance. *Invest Ophthal Vis Sci.* 1983;24:1442-3.
- [18]. Fernandes M, Sangwan VS, Rao SK, et al. Limbal Stem Cell Transplantation. *Indian J Ophthalmol.* 2004;52:5-22.
- [19]. Kruse EF. Stem cells and corneal regeneration. *Eye* 1994;8:170-83.
- [20]. Puangsricharern V, Tseng SC. Cytologic evidence of corneal disease with limbal stem cell deficiency. *Ophthalmology* 1995;102:1476- 85.
- [21]. Egbert PR, Lauber S, Maurice DM. A simple conjunctival biopsy. *Am J Ophthalmol.* 1977;84:798-80.
- [22]. Tsubota K, Toda I, Saito H, Shinozaki N, Shimazaki J. Reconstruction of the corneal epithelium by limbal allograft transplantation for severe ocular surface disorders. *Ophthalmology* 1995;102:1486-96.
- [23]. Chen JJ, Tseng SC. Corneal wound healing in partial limbal deficiency. *Invest Ophthalmol Vis Sci.* 1990;31:1301-14.
- [24]. Chen JJ, Tseng SC. Abnormal corneal epithelial wound healing in partial-thickness removal of limbal epithelium. *Invest*

- Ophthalmol Vis Sci. 1991;32:2219-33.
- [25]. Huang AJ, Tseng SC. Corneal epithelial wound healing in the absence of limbal epithelium. Invest Ophthalmol Vis Sci. 1991;32:96-105.
- [26]. Kruse FE, Chen JJ, Tsai RJ, Tseng SC. Conjunctival transdifferentiation is due to the incomplete removal of limbal basal epithelium. Invest Ophthalmol Vis Sci. 1990;31:1903-13.
- [27]. Dua HS, Gomes JA, Singh A. Corneal epithelial wound healing. Br J Ophthalmol. 1994;78:401-8.
- [28]. Dua HS, Forrester HV. The corneo-scleral limbus in human corneal epithelial wound healing. Am J Ophthalmol. 1990;110:646-56.
- [29]. Tseng SCG, Chen JJY, Huang AJW, et al. Classification of conjunctival surgeries for corneal disease based on stem cell concept. Ophthalmol Clin North Am. 1990;3:595-610.
- [30]. Kinoshita S, Kiritoshi A, Ohji M, et al. Disappearance of palisades of Vogt in ocular surface disease. Jpn J Clin Ophthalmol. 1986;40:363-66.
- [31]. Sangwan VS, Matalia HP, Vemuganti GK, et al. Early results of penetrating keratoplasty after cultivated limbal epithelial transplantation. Arch Ophthalmol. 2005;123(3):334-40.
- [32]. Tamhane A, Vajpayee RB, Biswas NR, et al. Evaluation of amniotic membrane transplantation as an adjunct to medical therapy as compared with medical therapy alone in acute ocular burns. Ophthalmology 2005;112:1963-9.
- [33]. Meller D, Pires RT, Mack RJ, et al. Amniotic membrane transplantation for acute chemical or thermal burns. Ophthalmology 2000;107:980-9.
- [34]. John T, Foulks GN, John Me, et al. Amniotic membrane in the surgical management of acute toxic epidermal necrolysis. Ophthalmology 2002;109:351-60.
- [35]. Kobayashi A, Yoshita T, Sugiyama K, et al. Amniotic membrane transplantation in acute phase of toxic epidermal necrolysis with severe corneal involvement. Ophthalmology 2006;113:126-32.
- [36]. Muqit M, Ellingham R, Daniel C. Technique of amniotic membrane transplant dressing in the management of acute Stevens-Johnson syndrome. Br J Ophthalmol. 2007;91:1536.
- [37]. Tandon A, Cackett P, Mulvihill A, Fleck B. Amniotic membrane grafting for conjunctival and lid surface disease in the acute phase of toxic epidermal necrolysis. J AAPOS 2007;11:612-3.
- [38]. Shay E, Khadem JJ, Tseng SC. Efficacy and limitation of sutureless amniotic membrane transplantation for acute toxic epidermal necrolysis. Cornea 2010;29:359-61.
- [39]. Brown SI, Bloomfield SE, Pearce DB. Follow-up report on transplantation of the alkali burned cornea. Am J Ophthalmol. 1974;77:538-42.
- [40]. Mahmood MA, Wagoner MD. Penetrating keratoplasty in eyes with keratoconus and vernal keratoconjunctivitis. Cornea 2000;19:468-70.
- [41]. Tsai RJ, Sun TT, Tseng SC. Comparison of limbal and conjunctival autograft transplantation in corneal surface reconstruction in rabbits. Ophthalmology 1990;97(4):446-55.
- [42]. Kenyon KR, Tseng SC. Limbal autograft transplantation for ocular surface disorders. Ophthalmology 1989;96(5):709-22.
- [43]. Morgan S, Murray A. Limbal autotransplantation in the acute and chronic phases of severe chemical injuries. Eye (Lond). 1996;10 (Pt 3):349-54.
- [44]. Tan DT, Ficker LA, Buckley RJ. Limbal transplantation. Ophthalmology 1996;103(1):29-36.
- [45]. Frucht-Pery J, Sigano CS, Solomon A, et al. Limbal cell autograft transplantation for severe ocular surface disorders. Graefes Arch Clin Exp Ophthalmol. 1998;236(8):582-7.
- [46]. Basti S, Mathur U. Unusual intermediate-term outcome in three cases of limbal autograft transplantation. Ophthalmology. 1999;106(5):958-63.
- [47]. Rao SK, Rajagopal R, Sitalakshmi G, Padmanabhan P. Limbal autografting: comparison of results in the acute and chronic phases of ocular surface burns. Cornea 1999;18(2):164-71.
- [48]. Dua HS, Azuara-Blanco A. Autologous limbal transplantation in patients with unilateral corneal stem cell deficiency. Br J Ophthalmol. 2000;84(3):273-8.
- [49]. Ozdemir O, Tekeli O, Ornek K, et al. Limbal autograft and allograft transplantations in patients with corneal burns. Eye (Lond). 2004;18(3):241-8.
- [50]. Santos MS, Gomes JA, Hofling-Lima AL, et al. Survival analysis of conjunctival limbal grafts and amniotic membrane transplantation in eyes with total limbalstem cell deficiency. Am J Ophthalmol. 2005;140(2):223-30.
- [51]. Miri A, Al-Deiri B, Dua HS. Long-term outcomes of autolimbal and allolimbal transplants. Ophthalmology 2010;117(6):1207-13.
- [52]. Miri A, Said DG, Dua HS. Donor site complications in autolimbal and living-related allolimbal transplantation. Ophthalmology 2011;118(7):1265-71.
- [53]. Welder JD, Pandya HK, Nassiri N, Djalilian AR. Conjunctival limbal autograft and allograft transplantation using fibrin glue. Ophthalmic Surg Lasers Imaging 2012;43(4):323-7.
- [54]. Pellegrini G, Traverso CE, Franzi AT, et al. Long-term restoration of damaged corneal surfaces with autologous cultivated corneal epithelium. Lancet 1997;349:990-3.
- [55]. Rama P, Matuska S, Paganoni G, et al. Limbal stem-cell therapy and long-term corneal regeneration. N Engl J Med. 2010;363:147-55.
- [56]. Di Iorio E, Ferrari S, Fasolo A, et al. Techniques for culture and assessment of limbal stem cell grafts. Ocul Surf. 2010;8:146-53.
- [57]. Baradaran-Rafii A, Ebrahimi M, Kanavi MR, et al. Midterm outcomes of autologous cultivated limbal stem cell transplantation with or without penetrating keratoplasty. Cornea 2010;29:502-9.
- [58]. Sangwan VS, Matalia HP, Vemuganti GK, et al. Clinical outcome of autologous cultivated limbal epithelium transplantation. Indian J Ophthalmology 2006;54:29-34.
- [59]. Pauklin M, Fuchsluger TA, Westekemper H, et al. Midterm results of cultivated autologous and allogeneic limbal epithelial transplantation in limbal stem cell deficiency. Dev Ophthalmology 2010;45:57-70.
- [60]. Schwab IR. Cultured corneal epithelia for ocular surface disease. Trans Am Ophthalmol Soc. 1999; 97:891-986.
- [61]. Schwab IR, Reyes M, Isseroff RR. Successful transplantation of bioengineered tissue replacements in patients with ocular surface disease. Cornea 2000;19:421-6.
- [62]. Tsai RJ, Li LM, Chen JK: Reconstruction of damaged corneas by transplantation of autologous limbal epithelial cells. N Engl J Med. 343:86-93, 2000.
- [63]. Rama P, Bonini S, Lambiase A, et al: Autologous fibrin-cultured limbal stem cells permanently restore the corneal surface of patients with total limbal stem cell deficiency. Transplantation 2001;72:1478-85.
- [64]. Grueterich M, Espana EM, Touhami A, et al. Phenotypic study of a case with successful transplantation of ex vivo expanded human limbal epithelium for unilateral total limbal stem cell deficiency. Ophthalmology 2002;109:1547-52.

- [65]. Sangwan VS, Vemuganti GK, Iftexhar G, et al. Use of autologous cultured limbal and conjunctival epithelium in a patient with severe bilateral ocular surface disease induced by acid injury: a case report of unique application. *Cornea* 22:478–81, 2003.
- [66]. Nakamura T, Inatomi T, Sotozono C, et al. Successful primary culture and autologous transplantation of corneal limbal epithelial cells from minimal biopsy for unilateral severe ocular surface disease. *Acta Ophthalmol Scand.* 2004;82:468-71.
- [67]. Kawashima M, Kawakita T, Satake Y, Higa K, Shimazaki J. Phenotypic study after cultivated limbal epithelial transplantation for limbal stem cell deficiency. *Arch Ophthalmol.* 2007;125:1337–44.
- [68]. Shortt AJ, Secker GA, Rajan MS, et al. Ex vivo expansion and transplantation of limbal epithelial stem cells. *Ophthalmology* 2008;115(11):1989-97.
- [69]. Gisoldi RAM C, Pocobelli A, Villani CM, Amato D, Pellegrini G. Evaluation of molecular markers in corneal regeneration by means of autologous cultures of limbal cells and keratoplasty. *Cornea* 2010;29:715–22.
- [70]. Rama P, Matuska S, Paganoni G, et al. Limbal stem-cell therapy and long-term corneal regeneration. *N Engl J Med.* 2010;363(2):147-155
- [71]. Di Iorio E, Ferrari S, Fasolo A, et al. Techniques for culture and assessment of limbal stem cell grafts. *Ocul Surf.* 2010;8(3):146-53.
- [72]. Pauklin M, Fuchsluger TA, Westekemper H, et al. Midterm results of cultivated autologous and allogeneic limbal epithelial transplantation in limbal stem cell deficiency. *Dev Ophthalmol.* 2010;45:57-70.
- [73]. Baradaran-Rafii A, Ebrahimi M, Kanavi MR, et al. Midterm outcomes of autologous cultivated limbal stem cell transplantation with or without penetrating keratoplasty. *Cornea* 2010;29:502–9.
- [74]. Meller D, Pauklin M, Westekemper H, et al. Autologous Transplantation of cultivated limbal epithelium. *Ophthalmologie.* 2010;107(12):1133-8 [Article in German].
- [75]. Thanos M, Pauklin M, Steuhl KP, et al. Ocular Surface Reconstruction With Cultivated Limbal Epithelium in a Patient With Unilateral Stem Cell Deficiency Caused by Epidermolysis Bullosa Dystrophica Hallopeau-Siemens. *Cornea* 2010;29:462–464.
- [76]. Prabhasawat P, Ekpo P, Uprasertkul M, et al. Efficacy of cultivated corneal epithelial stem cells for ocular surface reconstruction. *Clin Ophthalmol.* 2012;6:1483-92.
- [77]. Marchini G, Pedrotti E, Pedrotti M, et al. Long-term effectiveness of autologous cultured limbal stem cell grafts in patients with limbal stem cell deficiency due to chemical burns. *Clinical and Experimental Ophthalmology* 2012; 40: 255–67.
- [78]. Sharma S, Tandon R, Mohanty S, et al. Phenotypic evaluation of severely damaged ocular surface after reconstruction by cultured limbal epithelial cell transplantation. *Ophthalmic Res.* 2013;50(1):59-64.
- [79]. Nakamura T, Inatomi T, Sotozono C, et al. Transplantation of autologous serum-derived cultivated corneal epithelial equivalents for the treatment of severe ocular surface disease. *Ophthalmology* 2006;113:1765-72.
- [80]. Shimazaki J, Higa K, Morito F, et al. Factors influencing outcomes in cultivated limbal epithelial transplantation for chronic cicatricial ocular surface disorders. *Am J Ophthalmol.* 2007;143:945-53.
- [81]. Di Girolamo N, Bosch M, Zamora K, et al. A contact lens-based technique for expansion and transplantation of autologous epithelial progenitors for ocular surface reconstruction. *Transplantation* 2009;87:1571-8.
- [82]. Kolli S, Ahmad S, Lako M, et al. Successful clinical implementation of corneal epithelial stem cell therapy for treatment of unilateral limbal stem cell deficiency. *Stem Cells* 2010;28:597-610.
- [83]. Sangwan VS, Basu S, Vemuganti GK, et al. Clinical outcomes of xeno-free autologous cultivated limbal epithelial transplantation: a 10-year study. *Br J Ophthalmol.* 2011;95(11):1525-9.
- [84]. Mariappan I, Maddileti S, Savy S, et al. In vitro culture and expansion of human limbal epithelial cells. *Nature Protocols* 2010;5(8): 1470- 9.
- [85]. Subramaniam SV, Sejpal K, Fatima A, et al. Coculture of autologous limbal and conjunctival epithelial cells to treat severe ocular surface disorders: long-term survival analysis. *Indian J Ophthalmol.* 2013 May;61(5):202-7.
- [86]. Sejpal K, Ali MH, Maddileti S, Basu S, et al. Cultivated limbal epithelial transplantation in children with ocular surface burns. *JAMA Ophthalmol.* 2013;131(6):731-6.
- [87]. Sangwan VS, Basu S, MacNeil S, et al. Simple limbal epithelial transplantation (SLET): a novel surgical technique for the treatment of unilateral limbal stem cell deficiency. *BJO.* 2012;96(7):931-4.
- [88]. Lal I, Panchal BU, Basu S, Sangwan VS. In-vivo expansion of autologous limbal stem cell using simple limbal epithelial transplantation for treatment of limbal stem cell deficiency. *BMJ Case Rep.* 2013 May 22;2013.
- [89]. Bhalekar S, Basu S, Lal I, Sangwan VS. Successful autologous simple limbal epithelial transplantation (SLET) in previously failed paediatric limbal transplantation for ocular surface burns. *BMJ Case Rep.* 2013 May 10;2013.
- [90]. Bhalekar S, Basu S, Sangwan VS. Successful management of immunological rejection following allogenic simple limbal epithelial transplantation (SLET) for bilateral ocular burns. *BMJ Case Rep.* 2013 Mar 14;2013.
- [91]. Vemuganti GK, Kashyap S, Sangwan VS, et al. Ex-vivo potential of cadaveric and fresh limbal tissues to regenerate cultured epithelium. *Ind J Ophthalmol.* 2004;52:113–20.
- [92]. Shimazaki J, Higa K, Morito F, et al. Factors influencing outcomes in cultivated limbal epithelial transplantation for chronic cicatricial ocular surface disorders. *Am J Ophthalmol.* 2007;143:945–53.
- [93]. Baylis O, Figueiredo F, Henein C, et al. 13 Years of cultured limbal epithelial cell therapy: a review of the outcomes. *J Cell Biochem.* 2011;112:993–1002.
- [94]. Jui-Fang Tsai R, Tseng SCG. Human Allograft Limbal Transplantation for Corneal Surface Reconstruction. *Cornea* 1994; 13(5): 389-400.
- [95]. Tan DTH, Ficker LA, Buckley RJ. Limbal transplantation. *Ophthalmology* 1996;103:29–36.
- [96]. Koizumi N, Inatomi T, Suzuki T, et al: Cultivated corneal epithelial stem cell transplantation in ocular surface disorders. *Ophthalmology* 2001;108:1569-74.
- [97]. Koizumi N, Inatomi T, Suzuki T, et al: Cultivated corneal epithelial transplantation for ocular surface reconstruction in acute phase of Stevens-Johnson syndrome. *Arch Ophthalmol.* 2001;119:298-300.
- [98]. Shimazaki J, Aiba M, Goto E, et al: Transplantation of human limbal epithelium cultivated on amniotic membrane for the treatment of severe ocular surface disorders. *Ophthalmology* 109:1285--90, 2002.
- [99]. Nakamura T, Ishikawa F, Sonoda KH, et al: Characterization and distribution of bone marrow-derived cells in mouse cornea. *Invest Ophthalmol Vis Sci.* 46:497--503, 2005.
- [100]. Sangwan VS, Matalia HP, Vemuganti GK, et al. Early results of penetrating keratoplasty after cultivated limbal epithelium transplantation. *Arch Ophthalmol.* 2005 Mar;123(3):334-40.
- [101]. Daya SM, Watson A, Sharpe JR, et al: Outcomes and DNA analysis of ex vivo expanded stem cell allograft for ocular surface reconstruction. *Ophthalmology* 112:470--7, 2005.
- [102]. Shimazaki J, Higa K, Morito F, et al. Factors influencing outcomes in cultivated limbal epithelial transplantation for chronic cicatricial ocular surface disorders. *Am J Ophthalmol.* 2007;143:945–53.

- [103]. Ang LPK, Sotozono C, Koizumi N, et al. A Comparison Between Cultivated and Conventional Limbal Stem Cell Transplantation for Stevens-Johnson Syndrome. *Am J Ophthalmol*. 2007;143:178–180.
- [104]. Meller D, Fuchsluger T, Pauklin M, Steuhl KP. Ocular surface reconstruction in graft-versus-host disease with HLA-identical living-related allogeneic cultivated limbal epithelium after hematopoietic stem cell transplantation from the same donor. *Cornea* 2009 Feb;28(2):233-6.
- [105]. Miri A, Al-Deiri B, Dua HS. Long-term Outcomes of Autolimbial and Allolimbial Transplants. *Ophthalmology* 2010;117:1207–13.
- [106]. Basu S, Fernandez MM, Das S, et al. Clinical outcomes of xeno-free allogeneic cultivated limbal epithelial transplantation for bilateral limbal stem cell deficiency. *Br J Ophthalmol*. 2012;96:1504–9.
- [107]. Mannor GE, Mathers WD, Wolfley DE, Martinez JA. Hardpalate mucosa graft in Stevens-Johnson Syndrome. *Am J Ophthalmol*. 1994;118:786–791.
- [108]. Fry TL, Wood CI. Readily available full-thickness mucous membrane graft. *Arch Otolaryngol Head Neck Surg*. 1987;113:770–771.
- [109]. Naumann GO, Lang GK, Rummelt V, Wigand ME. Autologous nasal mucosa transplantation in severe bilateral conjunctival mucus deficiency syndrome. *Ophthalmology* 1990;97:1011–1017.
- [110]. Wenkel H, Rummelt V, Naumann GO. Long-term results after autologous nasal mucosal transplantation in severe mucus deficiency syndromes. *Br J Ophthalmol*. 2000;84:279–284.
- [111]. Nakamura T, Endo K, Cooper LJ, et al. The successful culture and autologous transplantation of rabbit oral mucosal epithelial cells on amniotic membrane. *Invest Ophthalmol Vis Sci*. 2003;44:106–16.
- [112]. Nakamura T, Inatomi T, Cooper LJ, et al. Phenotypic Investigation of Human Eyes with Transplanted Autologous Cultivated Oral Mucosal Epithelial Sheets for Severe Ocular Surface Diseases. *Ophthalmology* 2007;114:1080–8.
- [113]. Nakamura T, Inatomi T, Sotozono C, et al. Transplantation of cultivated autologous oral mucosal epithelial cells in patients with severe ocular surface disorders. *Br J Ophthalmol*. 2004;88:1280–4.
- [114]. Nishida K, Yamato M, Hayashida Y, et al. Corneal Reconstruction with Tissue Engineered Cell Sheets Composed of Autologous Oral Mucosal Epithelium. *N Engl J Med*. 2004;351:1187-96.
- [115]. Inatomi T, Nakamura T, Koizumi N, et al: Midterm results on ocular surface reconstruction using cultivated autologous oral mucosal epithelial transplantation. *Am J Ophthalmol*. 2006;141:267-75.
- [116]. Inatomi T, Nakamura T, Kojyo M, et al. Ocular Surface Reconstruction With Combination of Cultivated Autologous Oral Mucosal Epithelial Transplantation and Penetrating Keratoplasty. *AJO*. 2006;142:757- 64.
- [117]. Ma DH, Kuo MT, Tsai YJ, et al. Transplantation of cultivated oral mucosal epithelial cells for severe corneal burn. *Eye (Lond)*. 2009;23(6):1442-50.
- [118]. Uchino Y, Uchino M, Shimazaki J. Combination treatment of intravenous immunoglobulin and cultivated oral mucosal epithelial transplantation for ocular cicatricial pemphigoid. *BMJ Case Rep*. 2009; 2009: bcr09.2008.0979.
- [119]. Chen H CJ, Chen HL, Lai JY, et al. Persistence of transplanted oral mucosal epithelial cells in human cornea. *Invest Ophthalmol Vis Sci*. 2009 Oct;50(10):4660-8.
- [120]. Nakamura, T, Takeda K, Inatomi T, et al. Long-term results of autologous cultivated oral mucosal epithelial transplantation in the scar phase of severe ocular surface disorders. *Br J Ophthalmol*. 2011;95:942-6.
- [121]. Satake Y, Higa K, Tsubota K, et al. Long-term Outcome of Cultivated Oral Mucosal Epithelial Sheet Transplantation in Treatment of Total Limbal Stem Cell Deficiency. *Ophthalmology* 2011;118:1524-30
- [122]. Takeda K, Nakamura T, Inatomi T, et al. Ocular surface reconstruction using the combination of autologous cultivated oral mucosal epithelial transplantation and eyelid surgery for severe ocular surface disease. *Am J Ophthalmol*. 2011 Aug;152(2):195-20
- [123]. Hirayama M, Satake Y, Higa K, Yamaguchi T, Shimazaki J. Transplantation of cultivated oral mucosal epithelium prepared in fibrin-coated culture dishes. *Invest Ophthalmol Vis Sci*. 2012 Mar 21;53(3):1602-9. doi: 10.1167/iovs.11-7847.
- [124]. Burillon C, Huot L, Justin V, et al. Cultured autologous oral mucosal epithelial cell sheet (CAOMECS) transplantation for the treatment of corneal limbal epithelial stem cell deficiency. *Invest Ophthalmol Vis Sci*. 2012 Mar 13;53(3):1325-31.
- [125]. Sotozono C, Inatomi T, Nakamura T, et al. Visual Improvement after Cultivated Oral Mucosal Epithelial Transplantation. *Ophthalmology* 2013;120:193–200.
- [126]. Chan CC, Holland EJ. Infectious Keratitis After Boston Type 1 Keratoprosthesis Implantation. *Cornea* 2012;31:1128–1134.
- [127]. Aldave AJ, Sangwan VS, Basu S, et al. International results with the Boston Type I keratoprosthesis. *Ophthalmology* 2012;119:1530–8.
- [128]. Jain R, Sangwan VS. Childhood bilateral limbal stem cell deficiency: long-term management and outcome. *BMJ Case Rep*. 2013 May 29;2013. pii: bcr2013009508. doi: 10.1136/bcr-2013-009508.
- [129]. Strampelli B. Nouvelle orientation biologique dans la kératoplastie. *Bull Mem Soc Fr Ophthalmol*. 1964;77:145–61.
- [130]. Strampelli B, Valvo A, Tusa E. Osteo-odonto-cheratoprotesi in un caso trattato per anchiloblefarone e simblefarone totale. *Ann Ottalmol Clin Ocul*. 1965;91:462–79.
- [131]. Strampelli B. Perfezionamenti tecnici della osteo-odonto cheratoprotesi. *Ann Ottalmol*. 1966;92:155–78.
- [132]. Strampelli B. Osteo-condro-cheratoprotesi in sostituzione della osteo-odonto cheratoprotesi nei pazienti edentuli. *Ann Ottalmol Clin Ocul*. 1967;93:975-8.
- [133]. Strampelli B. Osteo-odonto-cheratoprotesi. *An Inst Barraquer (Barc)*. 1974;75:12–21.
- [134]. Falcinelli GC, Missiroli A, Petitti V, et al. Osteo-odonto- keratoprosthesis up-to-date. *Acta XXV Concil Ophthalmol Milan*. 1987;2:2772–6.
- [135]. Falcinelli G, Falsini B, Taloni M, et al. Modified osteo-odonto- keratoprosthesis for treatment of corneal blindness: long-term anatomical and functional outcomes in 181 cases. *Arch Ophthalmol*. 2005 Oct;123(10):1319-29.