

## Free Fibula Osseomyocutaneous Flap Used For Reconstruction in a Series of Four Cases of Ameloblastoma of the Mandible

Sweta Verma<sup>1</sup>, Neeta Sharma<sup>2</sup> Anirudh Mene<sup>3</sup>

<sup>1</sup>(Department Of Otorhinolaryngology And Head Neck Surgery, JLN hospital and research centre, Bhilai, Chattisgarh )

<sup>2</sup>(Department Of Otorhinolaryngology And Head Neck Surgery, JLN hospital and research centre, Bhilai, Chattisgarh )

<sup>3</sup>(Department Of Otorhinolaryngology And Head Neck Surgery, JLN hospital and research centre, Bhilai, Chattisgarh )

Corresponding author: Dr. Sweta Verma

### Abstract:

Ameloblastoma are most common odontogenic neoplasm. These are rare slowly growing, locally invasive tumour with high recurrence rate. We report four cases in this article and has discussed about the surgical management and their reconstruction .These four cases of Ameloblastoma Mandible presented in JLNH&RC Bhilai, Chattisgarh , a tertiary care hospital from 2015 to 2018 with jaw swelling who were further investigated by Orthopantomogram and Ct scan and were treated with wide local excision and fibular graft reconstruction. All cases showed no recurrence in approximately two years of follow up. Radical resection with reconstruction is main treatment of choice for majority of lesion.

**Key Word:** Ameloblastoma, Free Fibula Osseomyocutaneous Flap , Orthopantomogram.

Date of Submission: 20-12-2020

Date of Acceptance: 03-01-2021

### I. Introduction

Ameloblastoma is the most common Odontogenic neoplasm. Conventional Solid Multicystic Ameloblastoma is the most common type among them. They usually present with painless swelling of the jaw, delayed eruption or loosening of teeth. Radiologically, a uni / multilocular radiolucency is generally seen. Microscopic examination shows two cell types (outer tall columnar cells and central angular epithelial cells) forming islands or interlacing strands within a fibrous stroma. Cystic changes are commonly seen. Treatment includes either Conservative enucleation and curettage or radical treatment like Surgical Resection and Reconstruction.

In our study we describe the clinical presentation and management of a series of four patients of ameloblastoma of mandible in whom we performed segmental mandibulectomy and reconstructed the resultant defect with free fibula osseomyocutaneous flap.

### II. Case report

#### Case I:

34 year old male, presented with Swelling on the left side of face since 4months. Swelling was insidious in onset and gradually progressive in nature. History of loosening of tooth was present. Swelling was not associated with pain . patient had no addiction history. On clinical examination, a globular swelling with smooth surface and well defined margins was noted on the left cheek with intra-oral mucosa covered bulge. (Figure I) Orthopantomogram was done which showed a well-defined expansile lesion over the left side of mandible. (Figure II ) Computed tomography scan demonstrated large multiseptate cystic mass in left mandible involving body and angle. The mass was closely abutting left temporalis and masseter muscle with maintained fat planes.(Figure III ) Fine needle aspiration cytology of the swelling was done which revealed benign odontogenic neoplasm. Treatment considered was surgical excision with reconstruction. A multidisciplinary team of otolaryngologists and plastic surgeons carried out the procedure. Segmental mandibulectomy was performed on the left side from the first premolar till angle of mandible. (Figure IV) and the defect was reconstructed with free fibula flap ( Figure V ). Patient did not require a tracheostomy. Meticulous flap monitoring was done in the first 48 hours and there were no signs of arterial or venous congestion. Patient was kept on nasogastric tube feeding for about a week following which oral trial was given. Patient had near normal oral competence with minimal morbidity. Patient was discharged on fourteenth post-operative day. At 1 week follow-up , histopathology report was looked into which revealed islands of odontogenic epithelium showing

tall columnar cells with peripheral palisading , reverse polarity and sub nuclear vacuoles. Matrix revealed connective tissue stroma with fibroblast and collagen fibres. Findings were consistent with ameloblastoma. ( Figure VI ). Patient was kept under follow-up. Now at 2 years follow-up the patient is symptom and disease free with minimal treatment related morbidity.

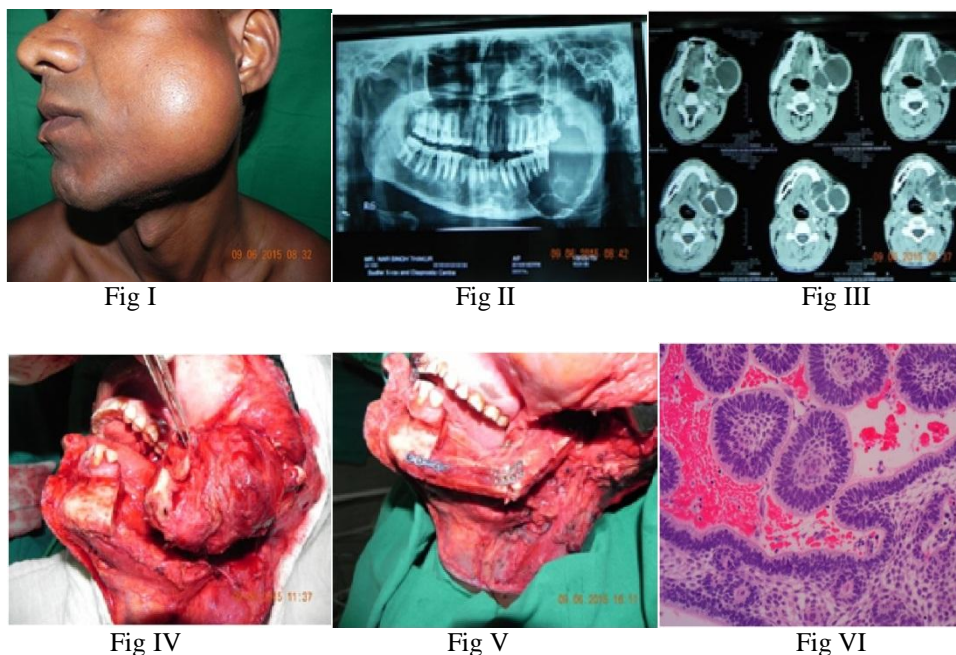


Fig I- Clinical image

Fig II- Orthopantomogram showing well defined expansile lesion .

Fig III- CT scan showing large multiseptate cystic mass in left mandible region involving body and angle.

Fig IV- Intraoperative picture showing large tumour over left side of mandible.

Fig V- Intraoperative picture showing large tumour over left side of mandible.

Fig VI- HPE showing islands of odontogenic epithelium showing tall columnar cells with peripheral palisading and reverse polarity and subnuclear vacuoles

It also shows marked transformation of star shaped stellate reticulum like cells to round or ovoid eosinophilic granular cells at the centre of tumour island

#### **Case II:**

52 year old female presented with swelling over Left lower jaw for 1 year, insidious in onset , progressive in nature with dragging type of pain. Toothache on and off since last 1 year. She was known hypertensive and type II DM on medications. CT scan showed mass lesion over left mandible. Patient was treated with en bloc resection with final reconstruction with free fibular graft. On follow up patient did not show any recurrence.

#### **Case III:**

49 year old female presented with swelling over left lower jaw since 1 year, pain since 2 months .She also presented with toothache in left lower central Incisor since 1 month. She was operated for Mandibular Bony overgrowth 20 years back. Orthopantomogram showed well defined, expansile lesion over left mandible. CT scan showed mass lesion over left mandible. Patient was treated with en bloc resection with final reconstruction with free fibular graft.

#### **Case IV:**

51 year old male, entitled, resident of bhilai presented with swelling over right side of lower jaw since 3 months and pain over the swelling. History of dental extraction from right side of lower jaw was in 2009. OPG showed well defined expansile lesion in right side of mandible. CT scan showed expansile soft tissue mass in body of mandible with resorption of root and cortical breach. Patient was operated wide local excision of tumour with approximately 2cm healthy margin and free fibular graft reconstruction.

### III. Discussion

Most common odontogenic jaw tumour which constitutes about 1% of all oral tumour is ameloblastoma. [1,2] The word ameloblastoma is derived from English word “amel” that means enamel and Greek word “blastos” that means the germ[3]. It arises from the dental lamina epithelium and it has a locally aggressive behaviour. It also has a high recurrence rate. Ameloblastoma was first described by Cusack in 1827[4]. It is mostly found in third and fourth decades of life but can vary in presentation in any age group and it has equal gender predilection. [1,2,5-7].It presents in mandible more than maxilla and most commonly found in molar ramus area. It is generally slow growing and it leads to expansion of jaw which is painless and causes thinning of cortical plate. In advanced cases of ameloblastoma, root resorption, mobility of tooth and paraesthesia are mostly seen. It can be unicystic, multicystic, peripheral or solid type radiographically. Its six subtypes found histologically are follicular, plexiform, acanthomatous, granular, desmoplastic, and basilar [8].

Treatment of ameloblastoma is primarily surgical. It includes either conservative approach which are curettage, enucleation ,cryosurgery or radical treatment which includes marginal, segmental and hemimandibulectomy. Here are two different school of thoughts for its treatment. It depends on its size ,anatomical location and histologic variant[9,10] .One school advocates major segmental or en bloc resection with removing 1 to 1.5 cm of normal healthy bone and uninvolved margins. On the other hand, other school goes with more conservative surgical management by enucleation with adjacent bone [9]. The rate of recurrence ranges from 17.7% for en bloc resection to 34.7% for conservative therapy. Wide en bloc resection of the tumour with a safety margin of clinically and radiographically healthy bone to prevent local recurrence were preferred.[2].

### IV. Conclusion

Ameloblastoma is most common odontogenic tumour of all jaw tumour. Though benign it is locally aggressive tumour so enbloc resection of tumour with approximately 2 cm wide margin of surrounding healthy bone along with reconstruction of defect with free fibular flap is one of the best modality of treatment in our institute to treat these lesions. It gives good functional and aesthetic results with free fibular flap reconstruction. All our cases have good functional and aesthetic result with this reconstruction in our 30 months of follow up.

**Conflicts of interest:** None

**Financial support and sponsorship :** None.

**Patients’ consent :** The authors certify that they have obtained all appropriate patient consent forms. In the form the patient(s) has/have given his/her/their consent for his/her/their images and other clinical information to be reported in the journal. The patients understand that their names and initials will not be published and due efforts will be made to conceal their identity, but anonymity cannot be guaranteed

### References

- [1]. Kahairi A, Ahmad RL, Islah Wan L, et al(2008) Management of large mandibular ameloblastoma a case report and literature reviews. Arch OrofacSci .2013:52–5
- [2]. Giraddi GB, Bimleshwar, Singh C, et al(2011) Ameloblastoma:series of 7 treated cases and review of literature.Arch Oral Sci Res.2013:152–5
- [3]. Brazis PW, Miller NR, Lee AG, Holliday MJ(1995). Neuro-ophthalmologic Aspects of Ameloblastoma. Skull Base Surg.5:233–44.
- [4]. Cusack JW(1827). Report of the amputations of the lower jaw. DUBLHosp Rec.4:1–38.
- [5]. Vohra FA, Hussain M, MudassirMS(2009). Ameloblastomas and their management: a review. Pak J Surg. 2013:136–42.
- [6]. Varkhede A, Tupkari JV, Mandale MS, et al(2010). Plexiformameloblastoma of mandible case report. J ClinExp Dent 2013:146–8
- [7]. Pizer ME, Page DG, SvirskyJA(2002). Thirteen year follow-up of large recurrent unicysticameloblastoma of the mandible in a 15-year old boy. J Oral Maxillofac Surg;2013:211–15.
- [8]. W. Zemann, M. Feichtinger, E. Kowatsch, and H. Kärcher,(2007) Extensive ameloblastoma of the jaws: surgical management and immediate reconstruction using microvascular flaps. Oral Surgery, Oral Medicine, Oral Pathology, Oral Radiology and Endodontics103:190–196.
- [9]. Escande, A. Chaîne, P. Menard et al.(2009)A treatment algorithmn for adult ameloblastomas according to the Pitié-Salpêtrière Hospital experience. Journal of Cranio-Maxillofacial Surgery 37:363–369.
- [10]. D. E. Sampson and M. A. Pogrel (1999)Management of mandibular ameloblastoma: the clinical basis for a treatment algorithm. Journal of Oral and Maxillofacial Surgery 57:1074–1077.

Dr. Sweta Verma, et. al. “Free Fibula Osseomyocutaneous Flap Used For Reconstruction in a Series of Four Cases of Ameloblastoma of the Mandible.” *IOSR Journal of Dental and Medical Sciences (IOSR-JDMS)*, 20(01), 2021, pp. 53-55.