

En-Mass Excision and Reconstruction of GCT in 1st Metatarsal in Incidentally Diagnosed Young Patient: A Case Report

Dr Tanmay Datta, Dr.santu sarkar

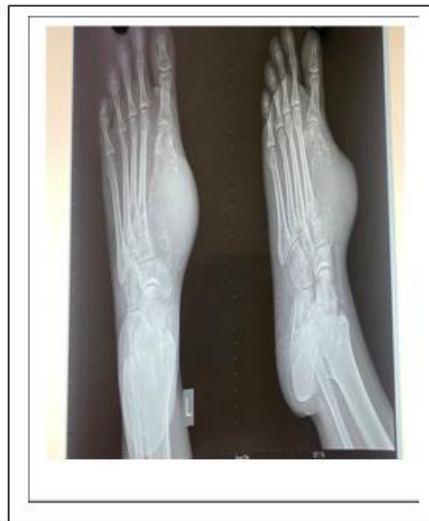Institute Of Postgraduate Medical Education And Research

Abstract

Giant Cell Tumour (GCT) which is a locally aggressive benign bone tumour with malignant potential rarely occurs in metatarsal. We present a case of GCT of first metatarsal bone in a 26 year old female with incidentally diagnosed diabetes mellitus. She was treated with excision of entire first metatarsal and reconstruction of the defect with freshly harvested autogenous ipsilateral fibula graft and its arthrodesis with medial cuneiform proximally & proximal phalanx distally. Regular follow up shows incorporation of fibular graft with good functional outcome of foot and no recurrence.

I. Introduction

World Health Organization has classified Giant Cell Tumour (GCT) as an aggressive and potentially malignant lesion with tendency for recurrence. Approximately 5% of bone tumours are GCTs and they occur in epiphyseo-metaphysis of long bone usually in 20-40 years of life. 50% of them affect around the knee but are rarely found in metatarsal bones. Higher incidence of multi-centricity, more aggressive behavior than those in other bones & appearance in younger age typifies GCTs of hand and feet.

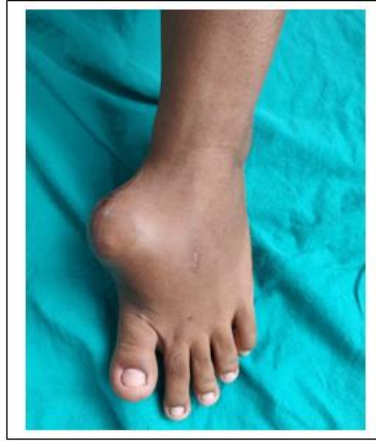

II. Case Report

A 26 years old female patient presented with history of one year duration of swelling in the left foot on the dorsal aspect which progressively increased in size and because of the swelling, it was difficult to wear footwear. He had h/o pain, first experienced following a history of trauma that occurred while playing football. Pain was dull aching type, mild to moderate intensity with no history of night pain. She had no systemic features.

On examination, a tender, ovoid swelling of size approximately 10 cm x 8 cm was noted on the dorsum of the Left foot, corresponding to 1st metatarsal location. The swelling was fixed to the underlying bone but was not adherent to skin and subcutaneous tissue. The skin was shiny in appearance but no evidence of sinus, ulcer, fistula or discharge.

X-ray revealed an expansile destructive osteolytic lesion involving almost whole of 1st metatarsal (except the proximal end) but not involving the articular surface of cuneiform-1st metatarsal joint and metatarsophalangeal joint. There were trabeculaions in the wall of lesion. The lesion had replaced the 1st metatarsal and had infiltrated the surrounding soft tissue. Chest x ray did not show any abnormality.



MRI showed 7.7 cmX5.6 cm sizes, well marginated lobulated expansile destructive lesion with marked signal heterogeneity of 1st metatarsal of left foot, where it revealed e/o cystic necrosis. The features were reported to be suggestive of GCT/Osteosarcoma of 1st Metatarsal left foot. (Fig. 3)

The patient was also incidentally diagnosed as Diabetic mellitus on routine preoperative work up and immediately initiated on Insulin on supervision of physician. Once normoglycemic status was achieved, incisional biopsy was done which confirmed the lesion as GCT. (Fig. 9)

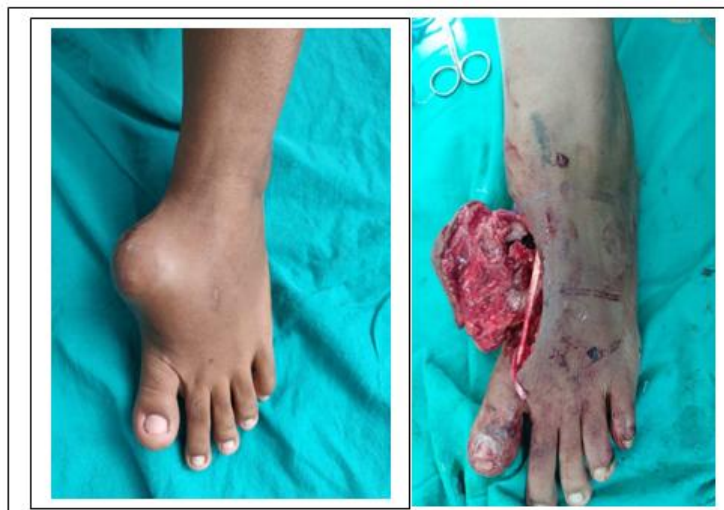Radical resection of the tumor by excision of the whole of the 1st metatarsal was done. (Fig. 4) Extension of surgical margin was attempted by application of hydrogen peroxide. The articular cartilages of medial cuneiform & proximal phalanx of great toe were denuded and slots were made in these bones to prepare host bone for arthrodesis. (Fig. 5, 6) The reconstruction of the bone defect was done with primary bone grafting with freshly harvested autogenous strut fibula graft from the patient. A 2mm Kirschner wire was passed intramedullary through the graft and transfixed with medial cuneiform proximally and phalanges distally. (Fig. 7) The excised specimen was sent for histopathological examination which confirmed the diagnosis of GCT. (Fig. 10) Wound was closed over the drain and posterior below knee POP slab was applied.

Care of wound as per standard dressing protocol was followed. Following removal of stitches on 14th post-operative day, a below knee POP cast was applied. Non weight bearing crutch aided ambulation was started as soon as post-operative pain subsided. This progressed to partial weight bearing ambulation & then finally to full weight bearing.

The clinicoradiological follow up has been done at 6 weeks, 3, 6, 9 & 12 month

There has been no h/o recurrence of localized pain /swelling or any other complains including that of chest symptoms. The normal size & shape of left foot including arches have been restored. Although inversion & eversion of left foot is restricted as compared to the normal side, yet patient can do painless full weight bearing ambulation.

Whereas the left foot x-ray and CT 3D shows union of the graft into the host bone, chest x-ray does not show any abnormality. (Fig. 8a, b, 9)



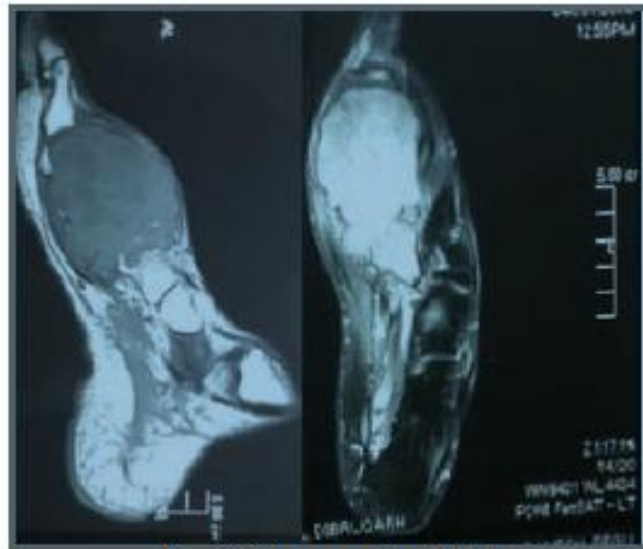


Fig. 3: Pre-operative MRI

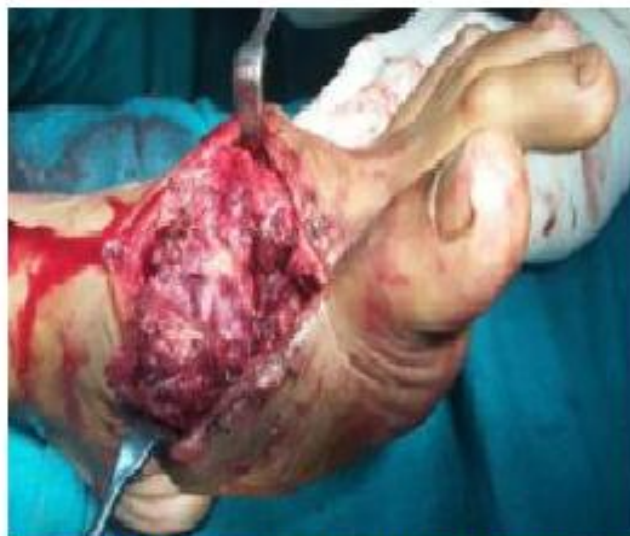

Fig. 4: Exposure and Excision of the tumour

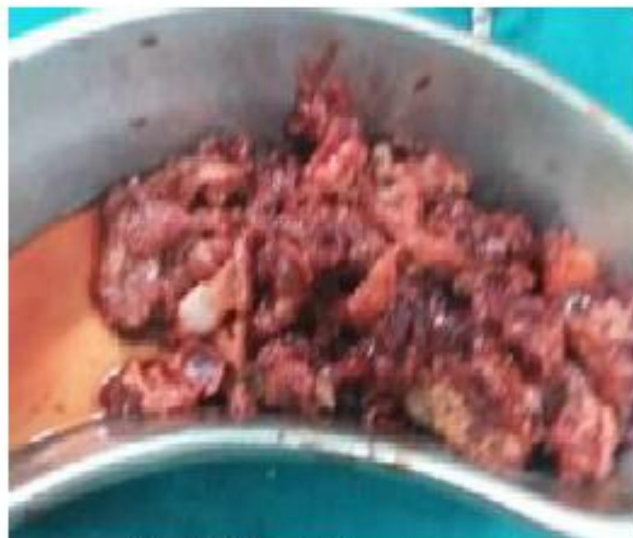

Fig. 5: Resected tumour mass

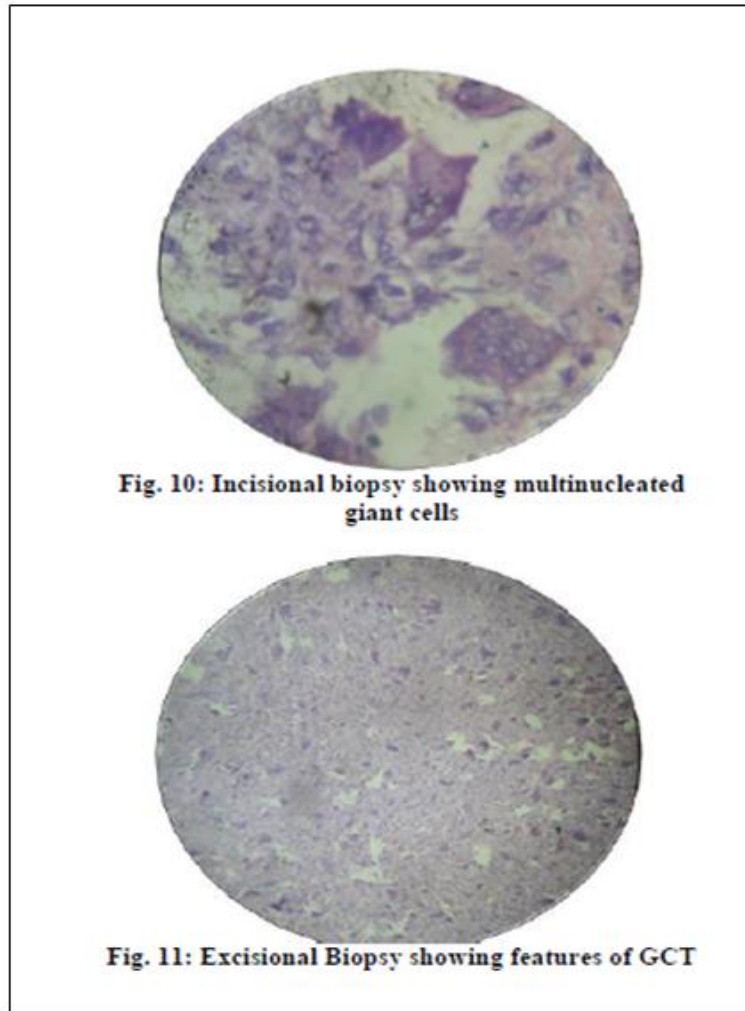


Fig. 10: Incisional biopsy showing multinucleated giant cells

Fig. 11: Excisional Biopsy showing features of GCT

III. Discussion

GCTs account for approximately 20% of benign bone tumours. However, in some Asian populations, this percentage is reportedly higher. Although they typically occur in epiphyseo-metaphysis of long bones (nearly 85-90%) but in skeletally immature patients, GCTs tend to occur in metaphysis. The second to fourth decades of life have the highest incidence with peak in the third. Only about 1% of them affects the first decade of life.

50% of GCTs occur around the knee, in the decreasing sequence of distal femur and proximal tibia followed by distal radius amongst the long bones and then sacrum in spine. The phalanx, metacarpal, maxilla and metatarsal are rarely affected.

Tuli et al 1984, Khanna et al 1990.(11) Baker et al,(2) Siddiqui et al(1) etc.

GCTs are reported to be malignant initially in 1-3% cases and also a small percentage of them become malignant later. Such malignant changes usually occur in recurrent cases or after radiotherapy.

Swelling, warmth or erythemas are usual presentations of GCTs. Pain may occur independently of weight bearing and in about 15% of cases, pathological fracture may be the presenting feature. The early diagnosis of GCT in metatarsal bone is difficult because of the rarity of its location and the attribution of symptoms primarily to vague foot pathology. The compact structure of foot may delay the diagnosis and therefore a high index of suspicion is essential during workup of any tumours of foot. The findings of GCT in plain X-ray at sites other than long bones are non-specific. MRI is a more sensitive non-invasive diagnostic tool in delineating the character and extent of tumour and may aid in distinguishing GCT from other pathologies. As clinical presentation and radiological images are not conclusive, biopsy of the lesion is necessary for histological confirmation of the diagnosis.

Amongst the established modalities of treatment, resection of the affected metatarsal & reconstruction with strut autograft or allograft with arthrodesis with medial cuneiform proximally and proximal phalanx distally is one of the surgical treatment. Fibula matches the size and shape of the metatarsal & therefore it is

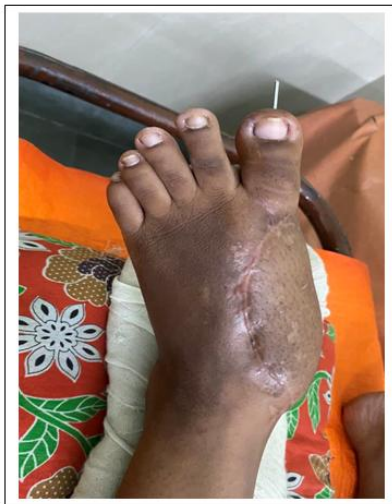chosen as strut graft for reconstruction of the bony gap following its resection. The another advantage of using fibula as strut graft is the strength it provides by virtue of being a cortical graft and hence it is possible to ensure appropriate weight transfer.

The tumours of the foot whether benign or malignant grow faster than in other bones. The hind foot and midfoot is classified as one single compartment in The Enneking staging system and therefore in cases with delayed diagnosis, radical resection & reconstruction for salvage of the foot is impossible to achieve and amputation becomes necessary in such cases. Therefore, to avoid amputation, early diagnosis is important in management any kind of foot tumours.

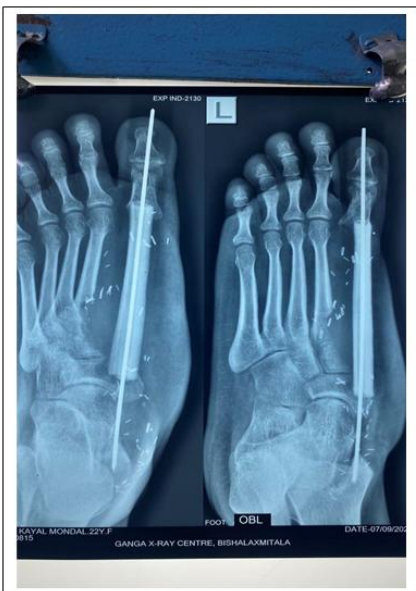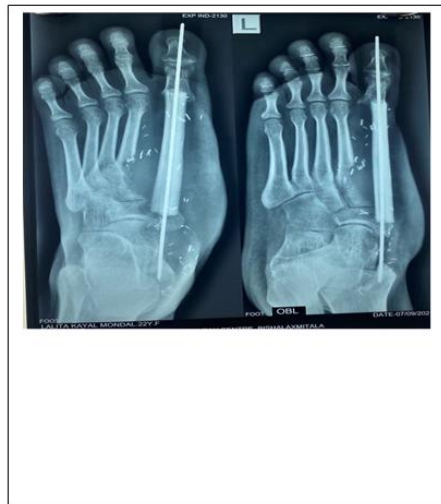IV. Conclusion

GCT, being aggressive benign bone tumour with malignant potential needs early and accurate diagnosis. This is more so in GCT's of foot as because hind foot and midfoot is classified as one compartment the Enneking staging system and therefore in late cases, radical resection & reconstruction for foot salvage becomes impossible to achieve, necessitating amputation.

Early and accurate diagnosis allows salvage procedure and prevents amputation. Resection of the affected metatarsal and reconstruction with autogenous fibula with arthrodesis with host bone proximally & distally minimizes the risk of recurrence & provides good functional outcome. As GCTs have tendency for recurrence, regular follow up of operated patient is necessary to detect recurrence at the earliest and institute appropriate treatment



3rd Follow up shows good wound healing and only mild swelling which gradually reduced overtime



5th follow up Shows improved functional outcome reduced pain



