

“LISSENCEPHALY” → the Smooth Brain → Life with Tough Journey: A Case Report

Dr. Rebecca Akhter¹, Dr. Salma Hossain²

¹Assistant Professor, Department of Pediatrics & Neonatology, Ashiyan Medical College Hospital, Dhaka, Bangladesh.

¹Assistant Professor, Department of Pediatrics & Neonatology, Ashiyan Medical College Hospital, Dhaka, Bangladesh.

Abstract

Lissencephaly or agyria is a rare disorder that is characterized by the absence of cerebral convolutions and a poorly formed Sylvian fissure giving the appearance of a 3-4 months fetal brain. The condition is probably a result of faulty neuroblast migration during early embryonic life. There is a four-layered cortex, rather than the usual six and a thin rim of periventricular white matter by microscopic examination. Here we report a case who is 8 months old female baby presented with repeated convulsion, microcephaly failure to thrive and ocular abnormalities. CT scan of the brain showed typical agyria.

Key words: Lissencephaly, Agyria; Neuronal migration; Intractable seizures.

Date of Submission: 04-10-2021

Date of Acceptance: 18-10-2021

I. Introduction

Lissencephaly, meaning a "smooth brain," is an uncommon, gene-linked brain malformation characterized by the lack of typical convolutions and abnormally small head (microcephaly) [1]. The term "Lissencephaly" is derived from the Greek word for "smooth brain". There are five major types of lissencephaly, with type 1 (classical) being the most common. Spontaneous mutations in LIS1, which encodes a WD-repeat protein involved in cytoplasmic dynein regulation, mitosis, and nuclear migration, cause classical lissencephaly [2]. The LIS1 gene has been found to be deleted or mutated in approximately 60% of patients with classical lissencephaly [3]. Histologically, it is distinguished by arrested neuronal migration, such that the brain resembles that of a fetus before 23–24 weeks gestation [4]. One of the most critical stages in brain development is the migration of post-mitotic neurons from the ventricular zone to the cortical plate during embryogenesis. This process is frequently defective, resulting in major brain malformations such as lissencephaly.

II. Signs & Symptoms

Newborns with Lissencephaly types 1 who have no underlying syndrome are said to have isolated LIS Sequence. Other linked brain deformities, such as lack or underdevelopment of the corpus callosum, the thick band of nerve fibres that join and convey signals between the two brain hemispheres. Infants often suffer microcephaly, seizures and severe or deep disabilities. Additionally, the disorder might have a normal facial appearance or minor modifications in the face, such as a relatively small jaw (micrognathia), (bitemporal hollowing). Feeding difficulties, growth failure, unusually decreased muscle tone (hypotonia) early in life and enhanced muscle tone (hypertonia) later throughout infancy, and impaired motor skills may also involve additional symptoms. Type 1 is frequently associated with hereditary abnormalities, such as Miller-Dieker and Norman-Roberts syndrome. Apart from classical signs and symptoms of lissencephaly, infants with Miller-Dieker syndrome may also experience malformations such as microcephaly with a broad, high forehead; bitemporal hollowing; a relatively wide face; micrognathia; a long, thin upper lip; a short nose with the upright nose; low-set, malformed ears; polydactyly; abnormal palmar crease; heart failures and/or heart defects. Lissencephaly type 1 is also marked by various craniofacial anomalies such as the low, pitching forehead; an abnormally high back portion of the head; wide, prominent nasal bridge; and wide-set eyes (hypertelorism).

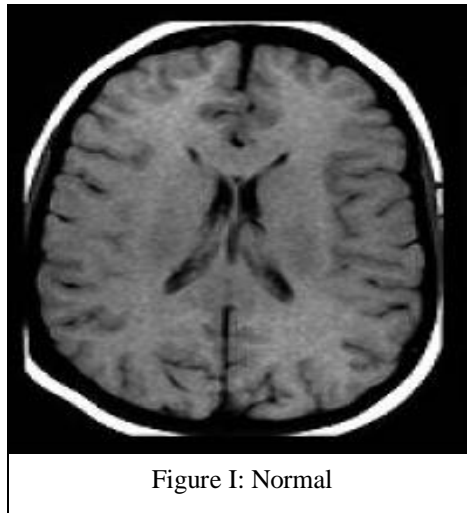


Figure I: Normal

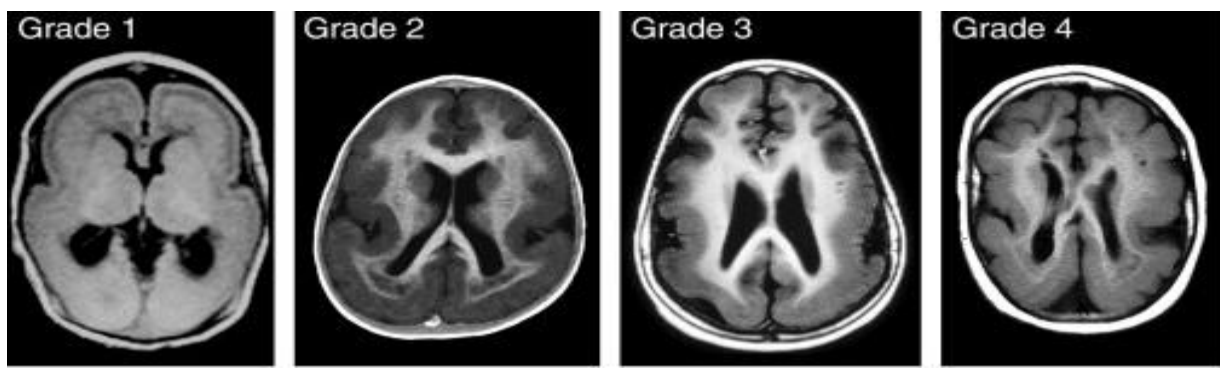


Figure II: Types of Lissencephaly

III. Case Report

Khadiza an eight months old infant girl, the only issue of non-consanguineous parents got admitted in the hospital with the complaints of repeated episodes of seizure disorder, feeding difficulties, growth failure and no neck control. Patients develop repeated generalized tonic convulsions in the forms of extension of all limbs, rolling eyes and occasional jerky movements. Convulsion occurs 4-5 times per day persisted few seconds to a minute. She still did not achieve neck control and other milestones were also delayed. She had no H/O fever, rash, offensive body or urine odour or H/O trauma.

The patient was delivered by NVD at terms and AGA. Her weight was 2-5 kg but treated in NICU from the 2nd day of her age due to repeated convulsion. Hypoglycemia and EONS for 7 days and discharged with an anticonvulsant. Her journey with tough life begins. She had H/o repeated admission in different hospitals due to intractable seizures and feeding difficulties.

Mother of Khadiza, a 21 years old lady. (BG- “O” +ve) was in regular ANC. She had no DM, HTN, Hypothyroidism or any other medical illness, but H/O 1 abortion at 3 months of gestation.

On examination, she was conscious, not interested to surroundings, vital signs were within normal limit. Anthropometrically wight 6 kg (expected 8.5 kg and 5th to 10 centiles) length 63cm (in 5th to 10 centiles (8.5kg) expected 67.8 cm), OFC =39 cm expected 43.8 cm (Microcephaly). She was underweight with stunted. On nervous system examination, hypertonia with exaggerated deep tendon reflexes was present in all four limbs. Developmental examination revealed global developmental delay, the persistence of primitive reflexes. Gross motor function corresponding to 3 months fine motor at 2 months vision and social development at birth with fisting. Other systemic examinations revealed no abnormality. Routine investigations were normal. Torch screening was negative ON CT brain cerebrum show shallow Sylvian fissure with the smooth grey-white interface. The cortex was thick with the virtual absence of sulci suggestive of lissencephaly. From old infract with focal atrophy as a result of cortical laminin necrosis involution gyri of both posterior parietal and in the occipital lobe. EEG Report showed abnormalities with polymorphic background activities and epileptic form discharges area of the brain.

The patient was managed by conventional anti-epileptic drugs including phenobarbitone, phenytoin. Due to uncontrol seizure IV injection of midazolam was also given routinely. The patient was discharged with oral antiepileptic drugs and advise for follow-up and to attend the child development centre.

IV. Discussion

Congenital structural defects of the central nervous system (CNS) constitute part of the 3% of severe malformations encountered in newborns. Whereas some may be due to hereditary abnormal development; others may arise from iatrogenic factors such as infections and teratogens. A prototype of the disorders of neuronal migration is lissencephaly or agyria. Currently, it is defined as a brain malformation manifested by a smooth cerebral surface, thickened cortical mantle with microscopic evidence of incomplete neuronal migration [5]. The incidence of classical lissencephaly has been estimated to be 1.2 in 100,000 births. Five major groups of lissencephaly can be recognized: i) Classic lissencephaly (previously known as type 1 lissencephaly), which include: lissencephaly due to LIS1 gene mutation (type 1 isolated lissencephaly and Miller-Dieker syndrome), lissencephaly due to doublecortin (DCX) gene mutation, lissencephaly type 1, isolated, without known genetic defects, ii) Lissencephaly X-linked with agenesis of the corpus callosum (ARX gene), iii) Lissencephaly with cerebellar hypoplasia, iv) Micro-lissencephaly, v) Cobblestone lissencephaly or cobblestone dysplasia (also known as type 2 lissencephaly), which includes Walker-Warburg syndrome or HARD(E) syndrome, Fukuyama syndrome and Muscle-Eye-Brain (MEB) disease [6]. The normal duration of gestation, absence of grotesque dysmorphic features and development of microcephaly in the first year of life, are suggestive of Lissencephaly type 1. As with the case being presented, a large majority of patients with lissencephaly have seizures during the first year of life and more than half of these present with infantile spasms. Other neurological manifestations include profound mental retardation and hypotonia that evolves to spasticity with time [2]. Radiologically, the CT scan and MRI features can be divided into primary or secondary findings. The primary finding is usually indicative of a neuronal migration defect which consists of a completely smooth brain that is agyricus or areas of pachygyria. The Sylvian grooves may be shallow and the distribution of white matter throughout the brain may be scanty. Secondary features include hydrocephalus, colpocephaly (dilatation of posterior horns of lateral ventricles), absent corpus callosum and Dandy-Walker malformation [7]. Treatment of children with lissencephaly is essentially symptomatic. This may consist of physiotherapy, the use of appropriate antiepileptic drugs and the introduction of affected children to appropriate rehabilitative programs. Genetic evaluation and counselling are indicated for families of children with lissencephaly [2]. Lissencephaly associated with abnormalities of the LIS1 gene usually results in severe clinical sequelae. These include severe or profound mental retardation, early-onset intractable epilepsy, early and persistent hypotonia that may progress to mild spastic quadriplegia, and major feeding problems. Early data suggested that lifespan is usually shortened with few patients surviving beyond the first decade, the major causes of death being aspiration pneumonia and sepsis.[3] Lissencephaly is a neurological disorder, which carries a bad prognosis because of poorly controlled seizures and mental retardation [8].

References

- [1]. Behrman RE, et al, eds. Nelson Textbook of Pediatrics. 16th ed. Philadelphia, PA: W.B. Saunders Company; 2000:1807.
- [2]. Jones KL. Smith's Recognizable Patterns of Human Malformation. 5th ed. Philadelphia, PA: W.B. Saunders Company; 1997:194-95.
- [3]. Gorlin RJ, et al, eds. Syndromes of the Head and Neck. 3rd ed. New York, NY: Oxford University Press; 1990:590-92.
- [4]. Buyse ML. Birth Defects Encyclopedia. Dover, MA; Blackwell Scientific Publications, Inc.; 1990:1074-75, 1774-75.
- [5]. Romero DM, Bahi-Buisson N and Francis F. Genetics and mechanisms leading to human cortical malformations. Semin Cell Dev Biol. 2017 Oct 10. pii: S1084-9521(17)30239-2. Tanaka T, et al. Lis1 and doublecortin function with dynein to mediate coupling of the nucleus to the centrosome in neuronal migration. J Cell Biol. 2004; 165:709-721.
- [6]. Kitamura K et al. Mutation of ARX causes abnormal development of forebrain and testes in mice and X-linked lissencephaly with abnormal genitalia in humans. Nat Genet 2002; 32:359-369.
- [7]. Pedersen LB, Rompolas P, Christensen ST, Rosenbaum JL, King SM: The lissencephaly protein Lis1 is present in motile mammalian cilia and requires outer arm dynein for targeting to Chlamydomonas flagella. J Cell Science. 2006; 120:858-67.
- [8]. Jouini S, Al-Awashiz AS, Izuora GI: An infant with isolated lissencephaly. Neurosciences. 2001;6(4):250-52.
- [9]. Cardoso C, Leventer RJ, Dowling JJ, Ward HL, Chung J, Petras KS, et al: Clinical and Molecular Basis of Classical Lissencephaly: Mutations in the LIS1 Gene (PAFAH1B1). Human mutation. 2002; 19:4-15.
- [10]. Rollins N, Reyes T, Chia J: Diffusion tensor imaging in lissencephaly. Am J Neuroradiol. 2005; 26:1583-6.
- [11]. Kato M, Dobyns WB: Lissencephaly and the molecular basis of neuronal migration. Human Mol Genetics. 2003;12(1):89-96.
- [12]. Verloes A. Lissencephaly, generic term. Orphanet Encyclopedia. March 2004. <http://www.orpha.net/data/path/GB/uk-lissencephaly.pdf>, accessed on 18th Oct. 2013.
- [13]. Thong MK, Lim CT, Koh MT, Kumar GG: The lissencephalic syndromes. MedJMalaysia. 1996;51(3):353-7.
- [14]. Gupta BV, Verma S, Raina VP, Irvathy GK: Lissencephaly child showing FISH negative and mutation in DCX gene with normal parental genetic makeup. Indian J Hum Genetics. 2006;12(2):93-5.