

Gingival fibromatosis associated with Zimmerman-Laband syndrome: about an observation

Dr Fatima zohra Maachou¹ Dr Nadjat Kadoun²

¹ Lecturer in Oral Pathology and Surgery. Dentistry department .Sidi Bel Abbes .Algeria

² Master Assistant in Periodontology. Dentistry department .Sidi Bel Abbes .Algeria

Abstract:

Gingival fibromatosis (GF) is a rare and benign genetic pathology, characterized by a slow and progressive fibrous hyperplasia of the marginal, attached and papillary gingiva. Its appearance is most often related to the eruption of temporary and/or permanent teeth. It is pathology with variable severity; it can partially or totally cover the dental crowns, generating an aesthetic prejudice and numerous functional problems such as malocclusions, difficulties in mastication and traumatic ulcerations. It can be isolated (autosomal dominant transmission) or associated with several individualized syndromes to which are added numerous extra-oral signs (mental retardation, hypertrichosis, hepatosplenomegaly, epilepsy...). The dental surgeon plays a key role in its diagnosis and management. The treatment of this disorder is mainly surgical. This work aims to describe this little known pathology and its management through the illustration of a case managed at the University Hospital of Sidi bel Abbes.

Keywords: gingival fibromatosis, genetic pathology, aesthetic and functional damage, surgery.

Date of Submission: 14-11-2021

Date of Acceptance: 29-11-2021

I. Introduction

Gingival fibromatosis, known previously as gingival elephantiasis, is a rare disease classified by ARMITAGE in 1999 as a gingival disease with genetic origin [1]. Gingival fibromatosis can be hereditary (FGH) and appear as an isolated entity or associated with various syndromes [2,3]. Different studies carried out on individuals from different affected families as well as within the same family have implicated several responsible factors, but none is systematically found, which is why the exact origin of the disease remains undetermined. It should also be mentioned that in 20% of cases, gingival fibromatosis appears isolated, without any family background[3]. Some authors therefore refer to idiopathic gingival fibromatosis (IGF) rather than GFH when the origin of the disease remains undetermined and no antecedent could be described [4, 5]. However, IGF can be the result of a neo-mutation or a recessively transmitted GFH. According to ORPHANET: "It can happen that a recent mutation, or neo-mutation, occurs in a sex cell of one of the two parents. If this mutation is the origin of a dominant pathological allele, although neither parent is affected, one or more of their children may be ill and transmit the mutation to their descendants. «This is why in this work we will speak of gingival fibromatosis (GF) without specifying whether it is a hereditary or idiopathic form, even if it is associated with Zimmerman-Laband syndrome, because the clinical and histological aspects are identical. FG is a rare disease affecting both boys and girls with a prevalence of 1/750,000 [6] Rarely found since birth [7,8], FG most often coincides with the eruption of the first permanent teeth, in mixed dentition [9] but it can also appear in temporary dentition [10]. An orthopantomogramme is necessary to establish the dental formula and to exclude possible agenesis or supernumerary teeth [11]. A surgical intervention by gingivectomy must be planned when fibromatosis is responsible of important psychological, functional and aesthetic disorders.

Clinical observation and treatment decision

A 12-year-old female patient presented to the clinic on October 28, 2019 for gum growth involving both dental arches. According to the mother, the gingival enlargement dates to birth, causing a delay in the eruption of the temporary and permanent teeth. No general history of gingival hyperplasia was found with no consanguinity between the parents. The patient underwent a tonsillectomy at the age of 5 years. The mother reported a delayed eruption of the temporary teeth (eruption of 51-61 at the age of 3 years and a half), but no learning difficulties or schooling delays were reported. The notion of Hirsutism is absent. The extra-oral examination (fig. 01 A and B) revealed a peculiar facial feature with maxillary vertical excess, a wide base of the nose and bulbous nose, thick lips, thick earlobes with keloid scars and hypertelorism, slightly thick hair, with normal implantation. The fingers of the hands are long with hypoplasia of the thumb nail of the left hand

(fig. 02), apart from any onychophagia mania. The patient does not present the mania. On the other hand the toes are of unequal length but the nails are without anomalies (fig. 03).

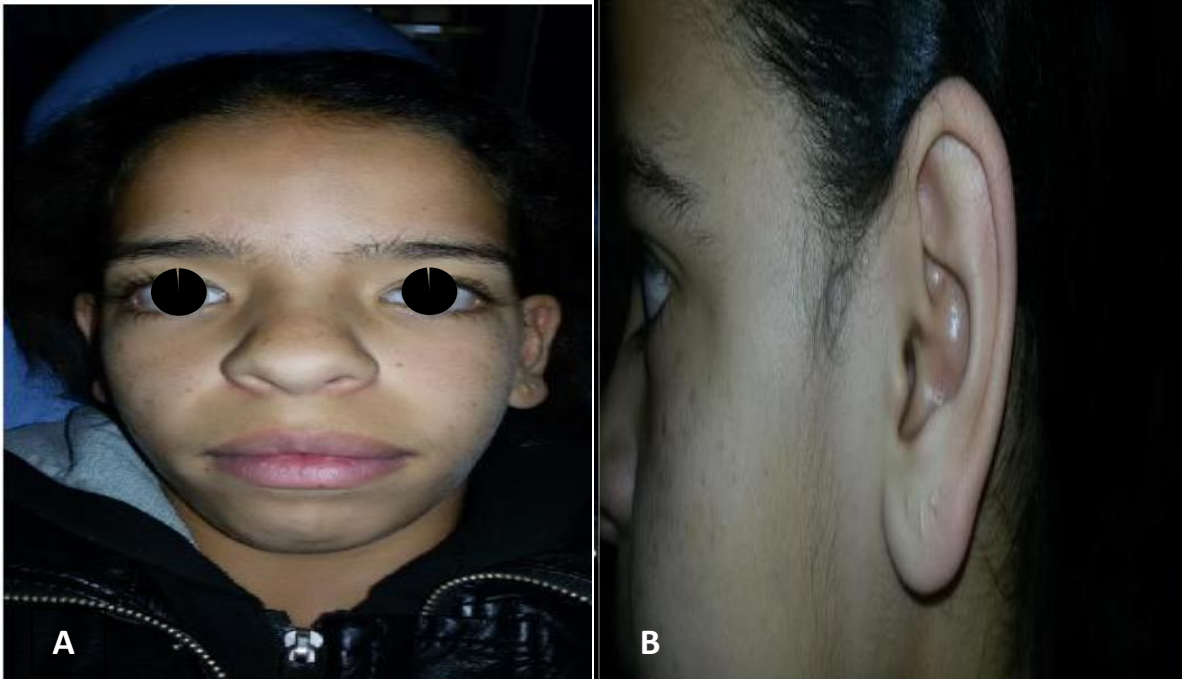


Fig. 01(A, B): photograph of extra-oral examination of Front and side view (keloscar of the ear)

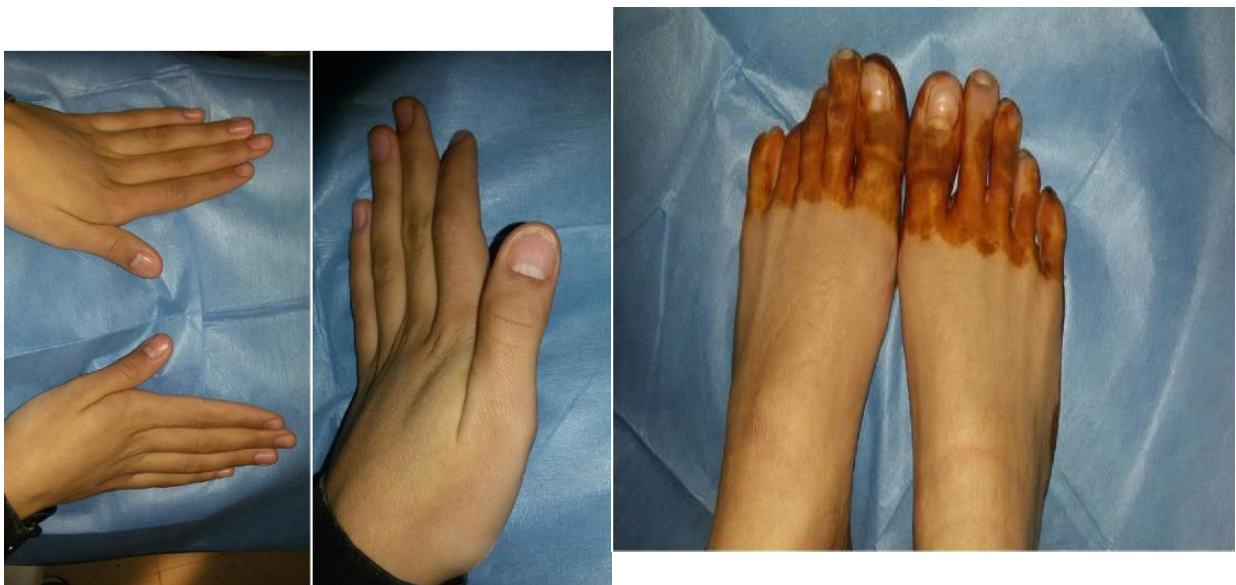

Fig. 02: Photographs of the hands (long fingers and hypoplasia of the thumb nail of the left hand)

Fig. 03: unequal lengths of the toes

The intraoral examination (fig. 04) revealed a good oral opening, an ogival-shaped palate, a generalized increase in gingiva in the two dental arches covering in places totally and in others partially the teeth giving an appearance of irregular crest at the level of the teeth. Lower molar blocks. The color of the gums is pink with the presence of brown spots of melanin; their consistency is firm with preservation of the orange peel picket in the attached gum. Palpation was painless without any spontaneous or induced bleeding. Periodontal probing revealed false pockets up to 10mm deep. The saliva was particularly viscous without any food intake (fig. 05).

At the dental examination (fig. 06) we noted an evaluative mixed dentition, an uncontrolled hygiene with presence of plaque.

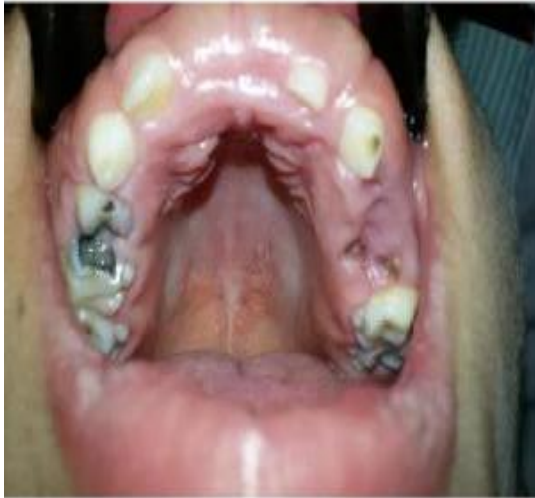

Fig 04 : photograph of the intraoral examination

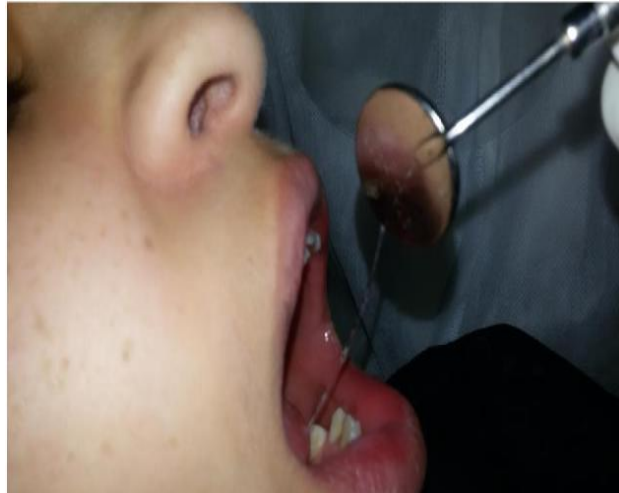

Fig 05 : photograph showing the slimy appearance of saliva

The dental formula was as follows: 12-53-54-55-16-62-63-64-65-26-31-32-33-34-35 (impacted)-41-42-83-84-44-45 (impacted), with several caries on the temporary teeth with little or no mobility (Fig. 06). An enamel hypoplasia was noted on 24 and 45 which is atypical in shape (Fig. 07).

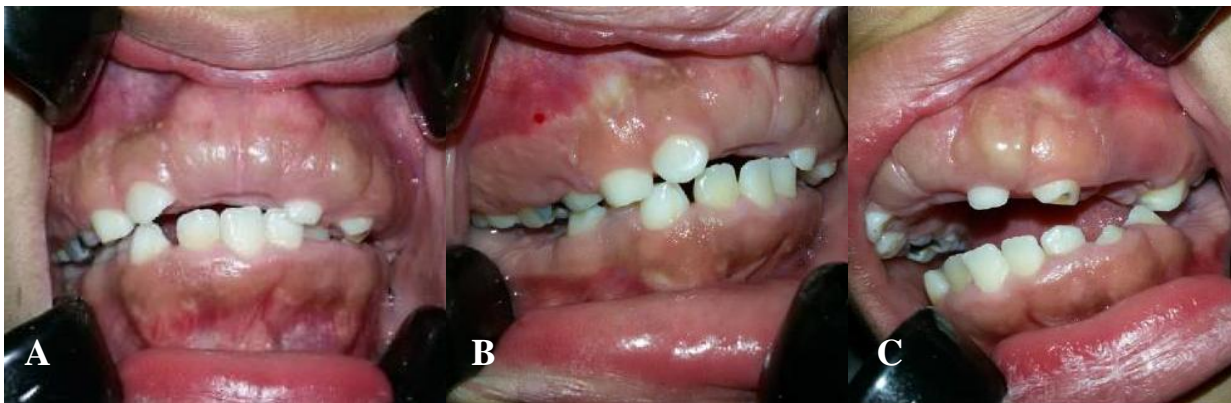

Fig. 06: photograph of intra oral view (A)Frontal , (B)right and (C) left

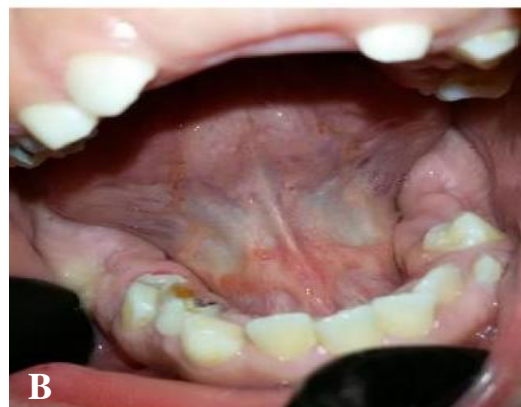
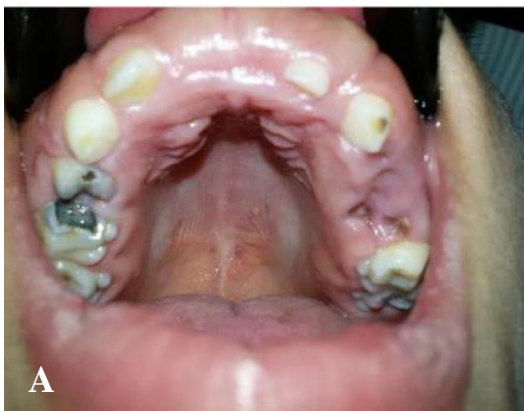
Fig.07 : photograph showing an enamel hypoplasia on 24 and 45 which is atypical in shape

The patient's parents presented old panoramic radiographs dating from 2016 and 2017. The first one showing supernumerary teeth (fig. 08) and a radiopaque image suspecting pulp calcification of the 84. The 2017 one (fig 09) showing the 11 and 21 in included position.

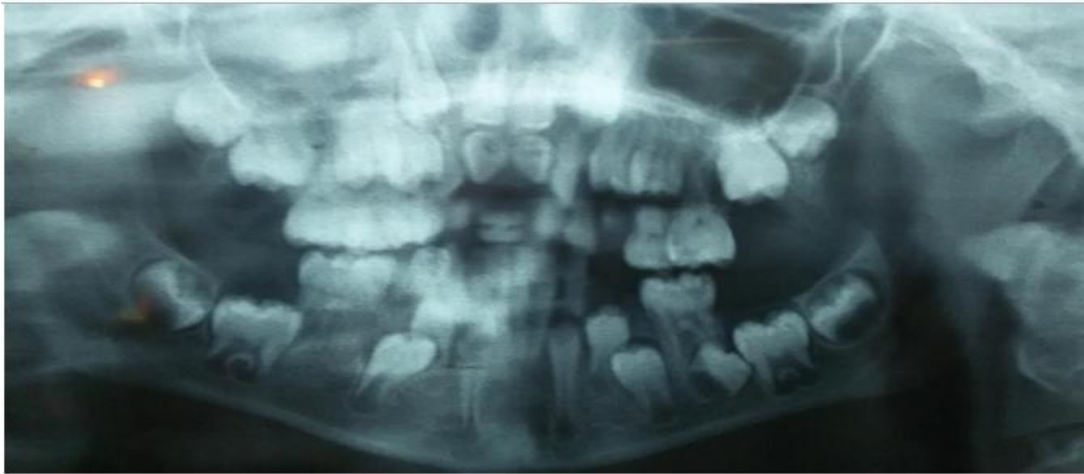


Fig 08: panoramic radiograph (2016) showing supernumerary teeth

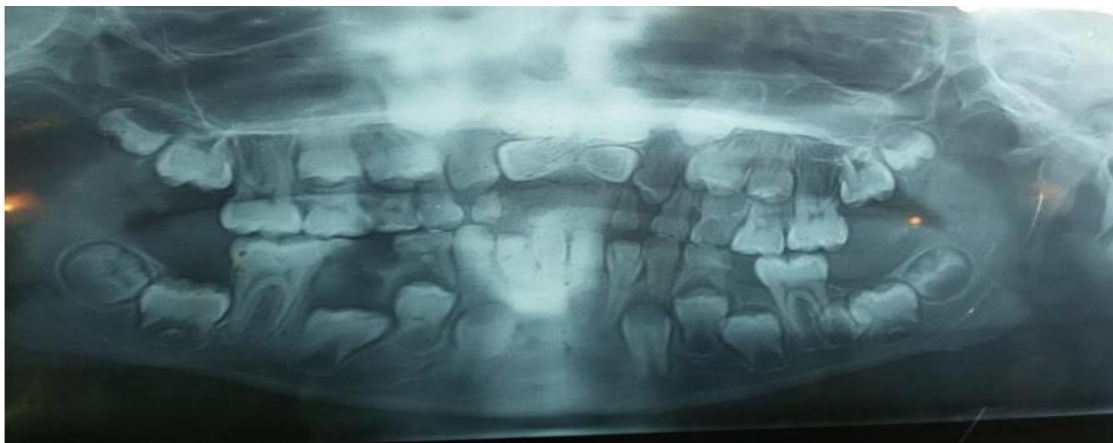

Fig.09 : panoramic radiograph showing 11 and 12 are included

A new panoramic radiography (Fig. 10) performed in the first instance had revealed rhytized temporary teeth retained by the fibro-mucosa and thus constituting an additional obstacle to the retention of the permanent teeth (sub gingival inclusion of 11, 13, 14, 15, 17, 21, 22, 23, 24, 25, 27, 37, 43, 47). The 46 and the 36 were probably extracted.

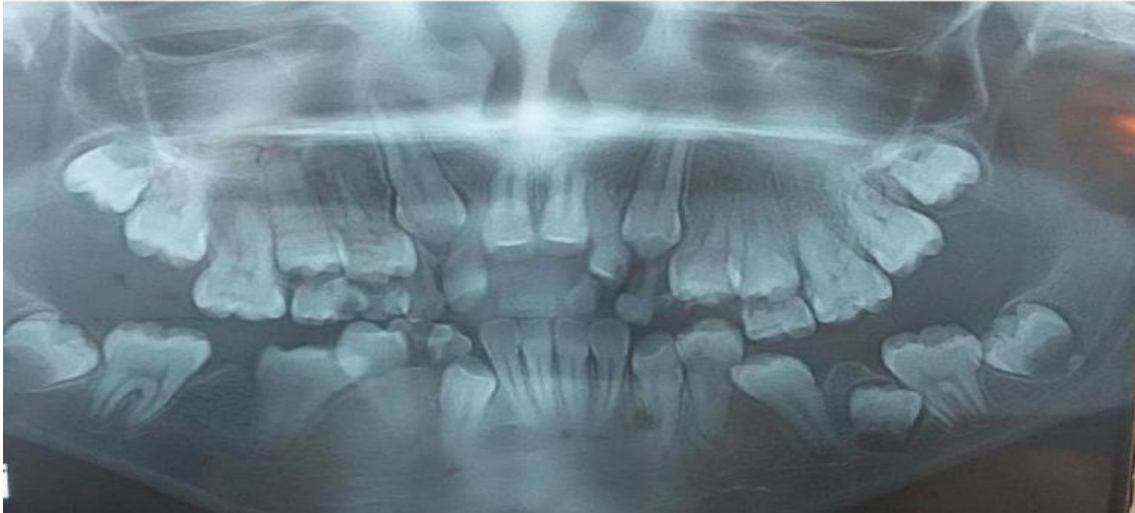

Fig.10 : A new panoramic radiograph : rhytized temporary teeth retained by the fibro-mucosa and thus constituting an additionalE obstacle to the retention of the permanent teeth

A new panoramic radiography (fig 11) taken in December 2020 (at the age of 14 years) showed radiopaque images suspecting pulp calcifications of (37, 38,48).

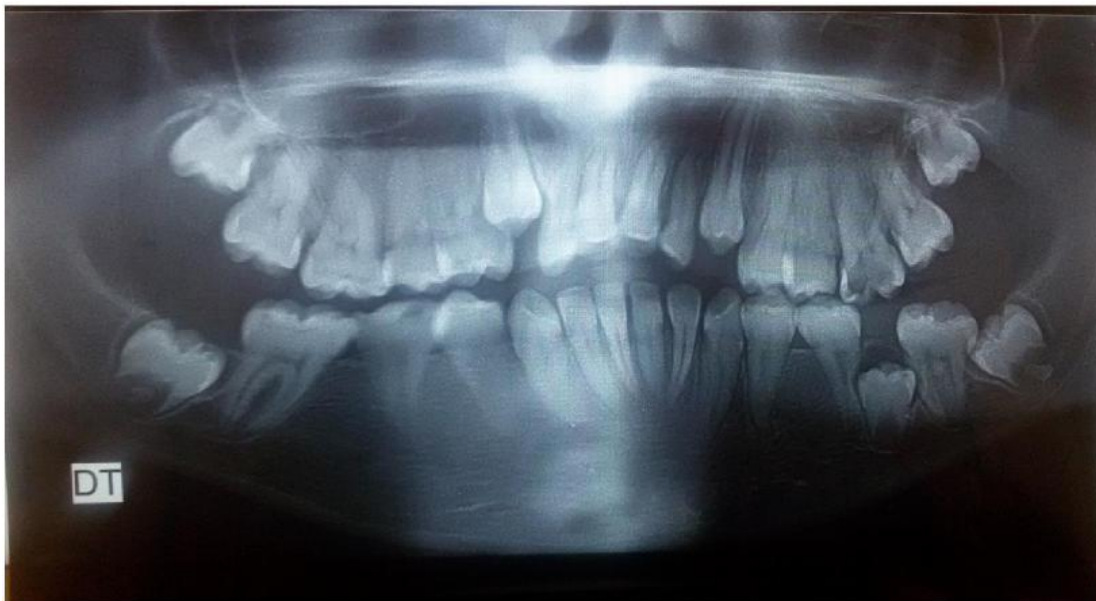

Fig.11 : panoramic radiograph taken in December 2020 (at the age of 14 years) showed radiopaque images suspecting pulp calcifications of (37, 38,48).

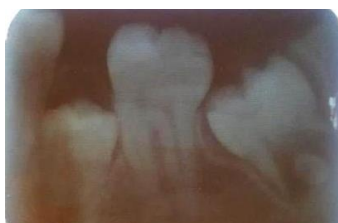

Fig. 12: Retro alveolar radiograph showing pulp calcification of 38

The child's somatic clinical examination (except for a particular facies) was eutrophic. The teguments and conjunctiva were normo-colored. The cardiovascular, pleuropulmonary and neurological examination was unremarkable. The abdomen was soft with no organomegaly.

The frontal radiography of the hands and feet (fig.13) made in search of aplasia, hypoplasia or deformation of the distal phalanges did not reveal any abnormality (normal aspect of the phalanges).

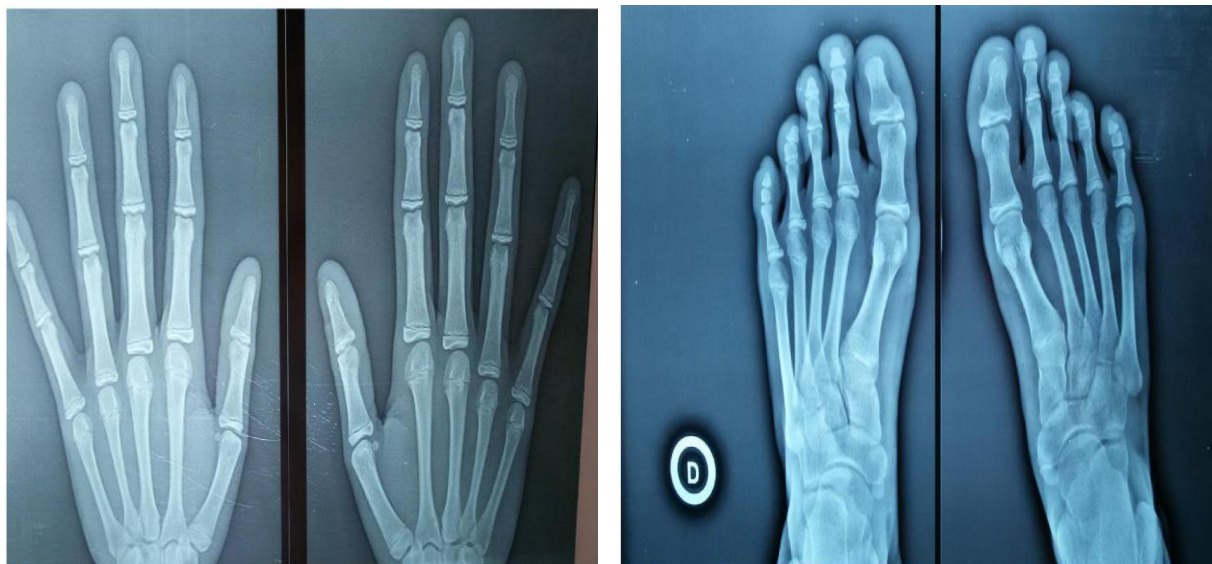


Fig. 13: radiograph of the hands and feet

An abdominal ultrasound was done to look for hepatosplenomegaly, but no abnormality was found. The FNS performed was unremarkable (except for a mild leukopenia), as well as the fasting blood glucose. The hormonal balance (TSH, T3, T4) was also normal. In view of the clinical and para-clinical findings, we made a presumptive diagnosis of gingival fibromatosis associated with Zimmerman-Laband syndrome.

Our therapeutic approach was conducted in three steps:

The first step consisted in learning plaque control techniques through hygiene motivation sessions, as gingival hyperplasia interferes with the control of bacterial plaque, which is a source of gingival inflammation and plays an important role in the frequency of recurrences [13], followed by the extraction of persistent temporary teeth on the arch, thus causing an additional obstacle to the eruption of the permanent teeth. Shortly after the extractions, the premolars emerged on the arch (fig.14 A and B).

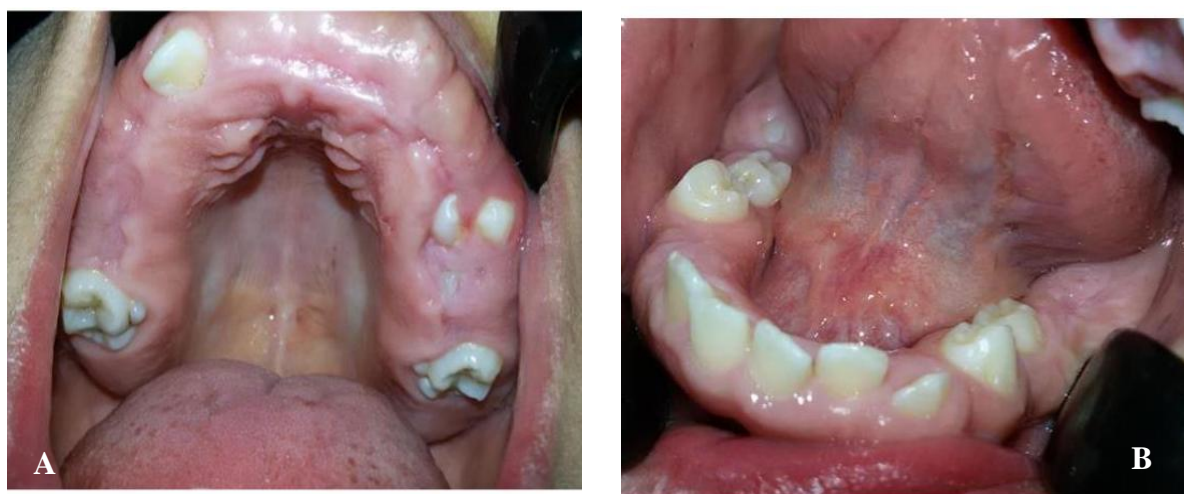

Fig. 14: Photograph of premolar eruption in the maxilla and mandible

The second therapeutic step was surgical performed quadrant by quadrant:

1. External bevel gingivectomy of the lower incisivo-canine block followed by gingivoplasty (this allowed correction of the gingival architecture and exposure of the crown of 43 retained by thick gingiva) (Fig. 15 A and B). The surgical specimens were sent for anatomo-pathological examination for histological diagnosis.

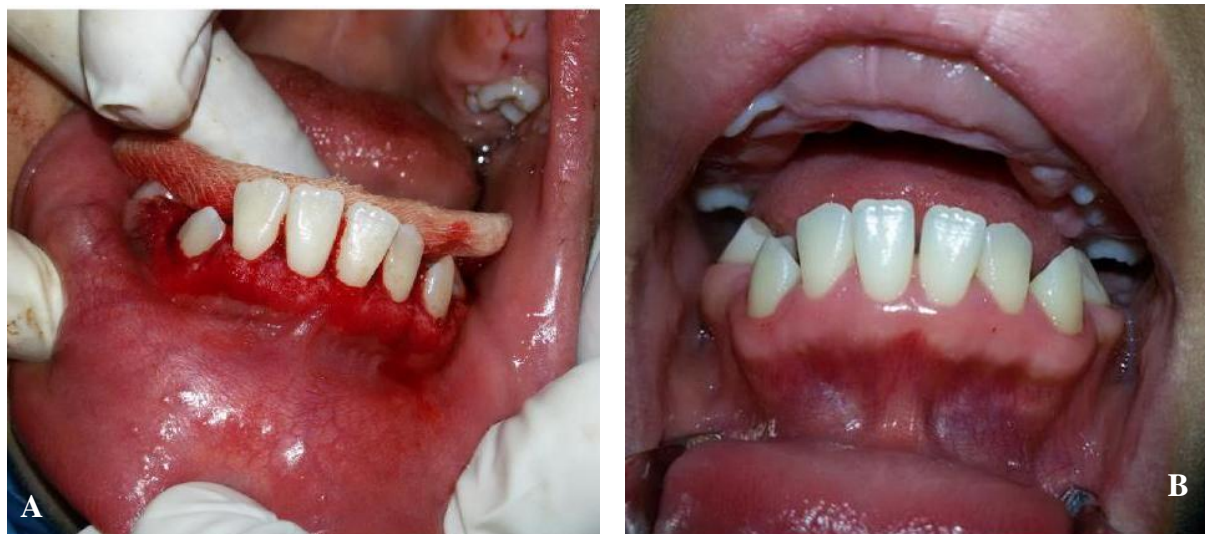

Fig. 15(A and B): Photograph of the external bevel gingivectomy of the lower incisivo-canine bloollowed by a gingivoplasty

2. Apically displaced flap for the désinclusion of 11-21 (sub gingival inclusion) and the creation of a band of attached gingiva at their level (high inclusion) (fig. 16 A and B)

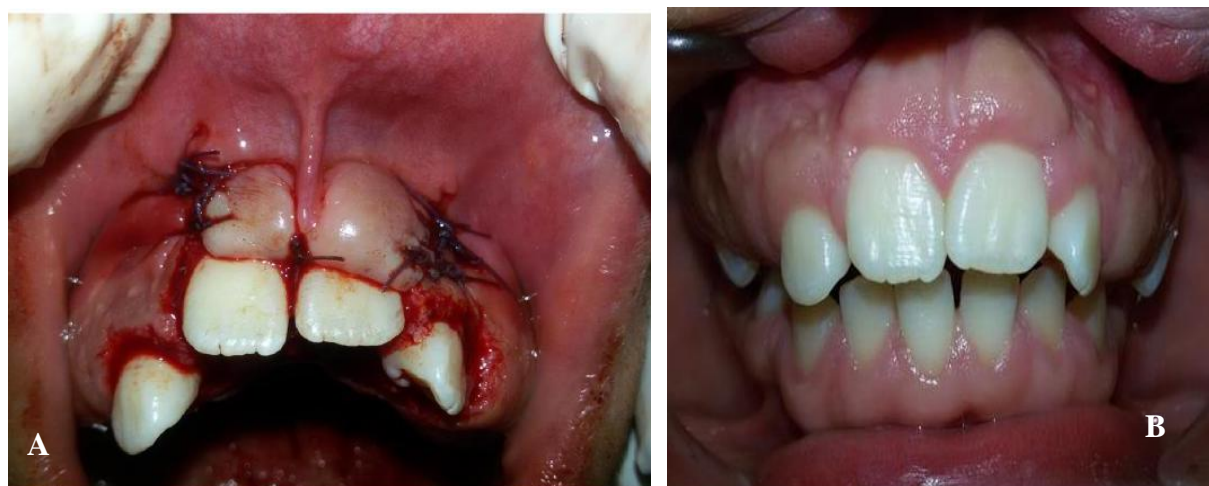

Fig.16 : Photographs of Apically displaced flap for the disinclusion of 11-21and the creation of a band of attached gingiva at their level

3. Two apically displaced flaps at the level of 13-23 (included subgingivally) for their disinclusion ; and external bevel gingivectomy at the level of the incisors (Fig. 17 A and B) .

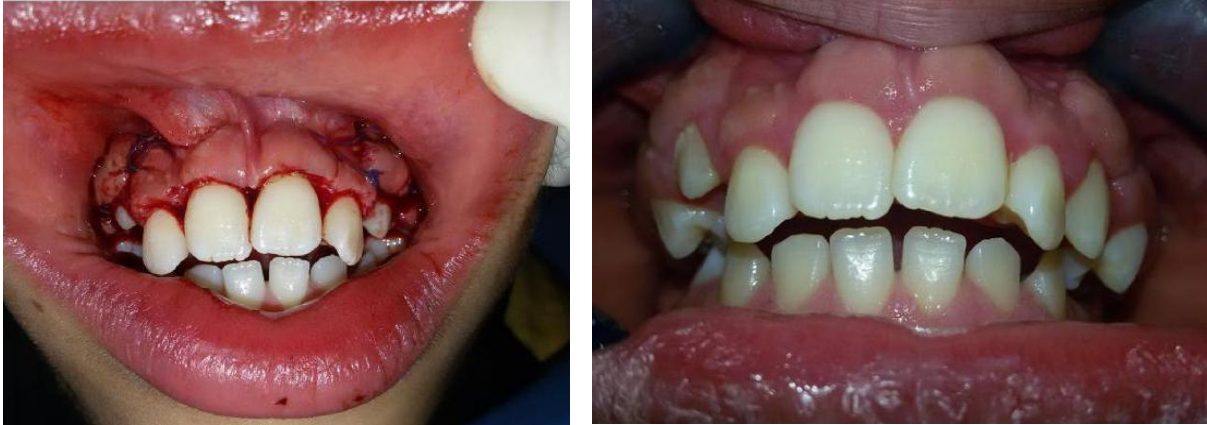

Fig.17 :photographs of the apically displaced flaps at the level of 13-23(before and after)

The results obtained in the short term were very satisfying and allowed the correction of the smile of our young patient who had a complex about the appearance of her gum and the improvement of her phonation (fig 18). The histopathological result confirmed the diagnosis of a gingival fibromatosis.

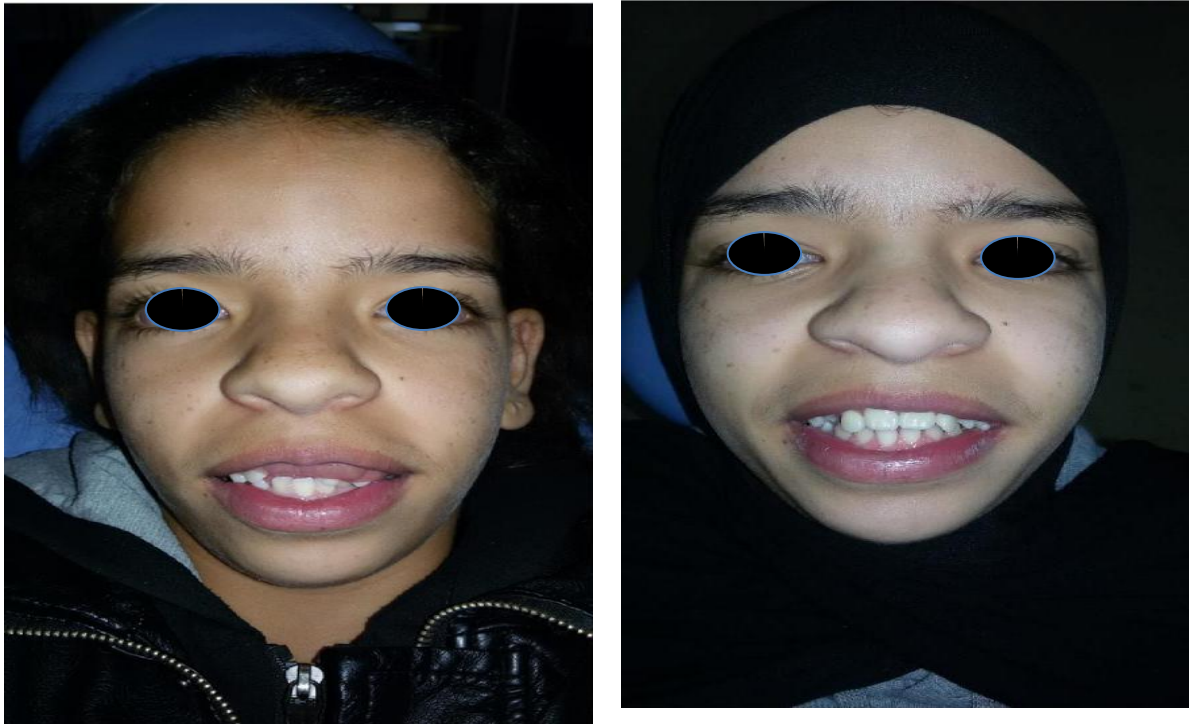

Fig.18 : pre-operative photograph (A) and post-operative photograph showing the correction of the smile

At the medium term and after 6 months, a partial recurrence of the gingival growth was observed in the 33-43 sector (fig 19). It should be noted that gingival fibromatosis is a recurrent pathology and therefore our patient will require a lifelong follow-up for gingival correction which will aim to facilitate oral hygiene, to avoid the appearance of concomitant gingival inflammation and therefore to achieve an aesthetic, functional and psychological goal.

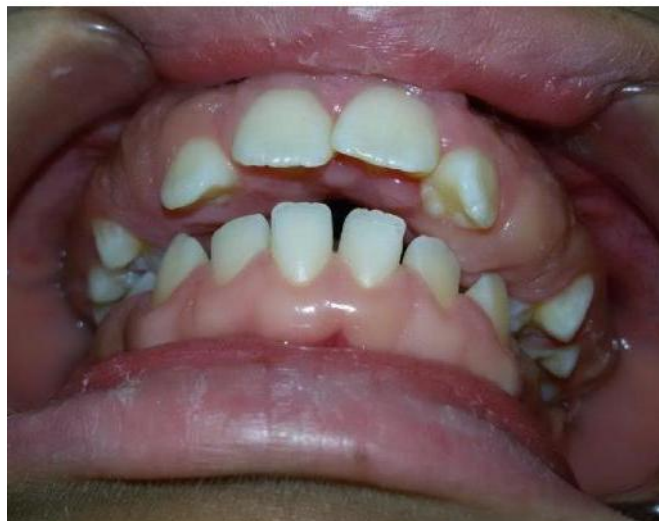

Fig.19 : photograph of the results at the medium term showing a partial recurrence of the gingival growth

II. Discussion

Zimmermann-Laband syndrome is a rare syndrome characterized by fibromatosis of the gingiva, facial dysmorphism, and absence or hypoplasia of the nails or distal phalanges of the hands and feet. Currently, very few cases have been reported. Facial dysmorphism includes a specific appearance with a bulbous nose, thick lips, large ears with thick lobes and gingival fibromatosis. This syndrome presents a great phenotypic variability, and other signs are less constant: hyper extensibility of the small articulations, hepatic splenomegaly, hypertrichosis and deafness. "(ORPHANET). This rare syndrome (1/750,000) [6] presents wide phenotypic variability; our patient presents several of its symptoms: thick lines, enlarged lips and nose, thick ear lobes, hypoplasia of one nail outside of any onychophagy mania and inequality in the length of the toes associated with gingival hypertrophy, amelar dysplasia and pulpal calcification. Another sign detected in this patient and not reported in the literature is the very high viscosity of the saliva. The differential diagnosis must lead to the evocation of gingival hyperplasia associated with various factors, which must be distinguished from FG [12, 13]:

- Inflammatory: gingivitis where the affected gingival tissues are soft in consistency, edematous and hemorrhagic unlike FG [14]. In our case, oral hygiene is defective but the gingiva is firm and non-inflammatory.
- Medication: Three main pharmacological classes are known to induce this type of lesion [13]. Immunosuppressants (cyclosporine, tacrolimus), anticonvulsants (phenitone, phenobarbital, valproic acid, vigabatrin), and antihypertensive drugs (only calcium channel blockers: nifedipine, amlodipine, felodipine, nifedipine, nitrendipine, diltiazem, verapamil). A diagnosis of drug-induced gingival swelling can be made if the edema coincides with the administration of one of these drugs, but no such drugs were taken by our patient.
- Conditioned either
 - by hormonal change where the impregnation of estrogens and progesterone is associated with significant changes in the proliferation of epithelial cells and fibroblasts. These changes can be observed during puberty, menstruation, pregnancy, oral contraceptives, or menopause [13]. Our patient has been pubertal since the age of 13 years but her problem of gingival growth dates back to her birth according to her mother. The nipple ultrasound associated with hormonal measurements did not reveal any hormonal problem.
 - by nutritional deficiencies, especially vitamin C (scurvy). Certainly, difficulties in eating are present but our patient does not seem to be in a state of malnutrition.
- Systemic: represented by
 - Acute leukemia: One of the signs of acute leukemia is hypertrophic gingival involvement, with spontaneous bleeding or bleeding upon contact, but there are gingival manifestations without visible inflammation or bleeding on clinical examination [12].

A NFS allows us to quickly and simply exclude this diagnosis, (this examination was performed in the first instance, as the prognosis could be life threatening) . Our patient's results were normal with a slight leukopenia.

- Crohn's disease: with abdominal pain, accompanied by intestinal disorders [15]. Our patient has no gastrointestinal disorders in her history.
- Wegener's granulomatosis, is discarded in this case because of the non-inflammatory and non-granular aspect of the gum[16] .

- Neurofibromatosis type I: We do not find any criteria on which the diagnosis could be based the " coffee milk" spots, learning and concentration difficulties, bone deformations, etc.). The gingival hypertrophy would in most cases be localized, not diffuse. Again, histological analysis confirmed our diagnosis of FG[16] .

III. Conclusion

Gingival fibromatosis, is a gingival rare disease having a genetic origin and various etiologies. It most often coincides with the eruption of teeth and can be either isolated or associated with syndromes, requiring a multidisciplinary management. Its genetic heterogeneity does not allow us to determine the responsible genes, although the SOS-1 gene is found several times in the autosomal dominant form of isolated FG. Its diagnosis is mainly a diagnosis of exclusion based on medical history, clinical and histopathological examination. Whether isolated or related to a syndrome, it is characterized by an accumulation of type I collagen in the ECM. The exact mechanisms responsible for this accumulation remain undetermined. Surgical intervention by gingivectomy should be considered when fibromatosis is responsible for significant psychological, functional and aesthetic problems. Maintaining good oral hygiene is essential to limit the risk of recurrence.

Bibliography

- [1]. Almiñana-Pastor.PJ , Buitrago-Vera.PJ ,Alpiste-Illueca .FM , Pizarro.MC . Hereditary gingival fibromatosis: Characteristics and treatment approach. *J Clin Exp Dent.* 2017;9(4):e599-602. PubMed
- [2]. Gawron K, Bereta G, Nowakowska Z, Łazarz-Bartyzel K, Potempa J, Chomyszyn-Gajewska M, et al. Analysis of mutations in the SOS-1 gene in two Polish families with hereditary gingival fibromatosis. *Oral Dis.* 2017;23(7):983-9. PubMed
- [3]. Fang L, Wang Y, Chen X. Gene expression profiling and bioinformatics analysis of hereditary gingival fibromatosis. *Biomed Rep.* 2018;8(2):133-7. PubMed
- [4]. Yadav VS, Chakraborty S, Tewari S, Sharma RK. An unusual case of idiopathic gingival fibromatosis. *Contemp Clin Dent.* 2013;4(1):102-4. PubMed
- [5]. Dani NH, Khanna DP, Bhatt VH, Joshi CP. Idiopathic gingival fibromatosis. *J Indian Soc Periodontol.* 2015;19(6):698-700. PubMed
- [6]. Pego SPB, de Faria PR, Santos LAN, Coletta RD, de Aquino SN, Martelli-Júnior H. Ultrastructural evaluation of gingival connective tissue in hereditary gingival fibromatosis. *Oral Surg Oral Med Oral Pathol Oral Radiol.* 2016;122(1):81-88. PubMed
- [7]. Gao H, Liang J, Xia X, Deng Z, Zhang Z. Unusual clinical and histologic findings in a child with mixed dentition with hereditary gingival fibromatosis: a case report. *Transl Pediatr.* 2020 Feb;9(1):74-80. doi: 10.21037/tp.2019.12.01. PubMed
- [8]. Pego S-P-B, Coletta RD, Mendes D-C, de Faria P-R, Melo-Filho MR, Alves L-R, et al. Hereditary gingival fibromatosis: Clinical and ultrastructural features of a new family. *Med Oral Patol Oral Cir Bucal.* 2015;20(2):e150-5. PubMed
- [9]. Dhadse PV, Yeltiwar RK, Pandilwar PK, Gosavi SR. Hereditary gingival fibromatosis. *J Indian Soc Periodontol.* 2012;16(4):606-9. PubMed
- [10]. Gawron K, Łazarz-Bartyzel K, Fertala A, Plakwicz P, Potempa J, Chomyszyn-Gajewska M. Gingival Fibromatosis with Significant De Novo Formation of Fibrotic Tissue and a High Rate of Recurrence. *Am J Case Rep.* 2016a;17:655-9. PubMed
- [11]. Gandhi M, Tandon S, Sharma M, Vijay A. Nonsyndromic Gingival Fibromatosis: A Rare Case Report. *Int J Clin Pediatr Dent.* 2018;11(3):250-3. PubMed
- [12]. Cherkaoui Jaouad I, El Alloussi M, Chafai El Alaoui S, Laarabi FZ, Lyahyai J, Sefiani A. Further evidence for causal FAM20A mutations and first case of amelogenesis imperfecta and gingival hyperplasia syndrome in Morocco: a case report. *BMC Oral Health.* 2015;15:14
- [13]. Pouloupoulos A, Kittas D, Sarigelou A. Current concepts on gingival fibromatosis-related syndromes. *J Investig Clin Dent.* 2011;2:156-161
- [14]. Kasaboglu O, Tumer C, Balci S. Hereditary gingival fibromatosis and sensorineural hearing loss in a 42-year old man with Jones syndrome. *Genet Couns.* 2004;15(2):213-218. – PubMed
- [15]. Zuckin SJ, Weisberger D. Hereditary gingival fibromatosis. Report of a family. *Oral Surg Oral Med Oral Pathol.* 1961 Jul;14(7):828-836. - PubMed
- [16]. Ruokonen H, Helve T, Arola J, Hietanen J, Lindqvist C, Hagstrom J. « Strawberry like » gingivitis being the first sign of Wegener's granulomatosis. *Eur J Intern Med.* 2009;20(6):651-3.

Dr Fatima zohra Maachou, et. al. "Gingival fibromatosis associated with Zimmerman-Laband syndrome: about an observation." *IOSR Journal of Dental and Medical Sciences (IOSR-JDMS)*, 20(11), 2021, pp. 12-21.