

“Multiparametric Magnetic Resonance Imaging In Prostate Malignancy And PI-RADS Correlation”

Dr. Asutosh Dave

(Professor and Head of Radio-diagnosis Department, GCS Medical College, Hospital and Research Centre, Ahmedabad).

Dr. Anand H Patel

(3rd year Resident in GCS medical college, Ahmedabad).

Dr. Nikunj Desai

(Associate Professor of Radio-diagnosis Department, GCS Medical College, Hospital and Research Centre, Ahmedabad).

Dr. Harsh V Thakrar, Dr. Ashutosh Agarwal and Dr. Radhika Patel

(3rd year Resident in GCS medical college, Ahmedabad).

Date of Submission: 10-11-2021

Date of Acceptance: 26-11-2021

I. Introduction:

Most common genitourinary malignancy in men & the third most common known cause of death in men – **“Prostate cancer”** (1). The multiparametric (Mp-MRI) approach using 3 different techniques, **T2-weighted (T2W) MRI, diffusion-weighted imaging (DWI), and dynamic contrast-enhanced MRI (DCE-MRI)** improve the diagnostic accuracy (3). Prostate Imaging Reporting and Data System (PI-RADS) has been purposed by **European Society of Urogenital Radiology (ESUR)**, the body has called a panel of experts in February 2012 and published a guideline providing recommendations for the performance of mp-MRI investigations and a structured reporting scheme. Aims of PI-RADS are to allow comparison of inter-observer interpretation variability; to enhance communication with clinicians in a uniform way; to facilitate quality assurance and research; and to improve patient outcome (5). The PI-RADS scoring committee of the American College of Radiology (ACR) and the European Society of Urogenital Radiology (ESUR) prostate MRI working group have diligently developed a revised version called **PIRADS 2.0** which was made public in early 2015. PI-RADS 2.0 provides extensive information on how to acquire, interpret, and report Mp-MRI of the prostate (6). The specific aims of PI-RADS 2.0 were to establish guidelines for minimum acceptable technical parameters for prostate Mp-MRI, to simplify and standardize the terminology and content of Mp-MRI reports, and to develop assessment categories that summarize the levels of suspicion or risk of having significant prostatic cancer. **This study aimed to assess the value of Mp-MRI with PI RADS 2.0 scoring system in differentiation between malignant and benign prostatic lesions.**

II. Material And Methods:

The current study is a prospective study conducted in the department of radio diagnosis at **GCS Hospital, Ahmedabad, includes 55 Male patients** with suspicious prostatic lesions underwent PR examination, PSA tests, TRU/S, and Mp-MRI prostate **over a period of 12 months from January 2020 to December 2020, Their imaging findings of “Mp-MRI” done using 1.5 Signa explorer are assessed for evaluation of matter in interest.**

INCLUSION & EXCLUSION CRITERIA:

- ✓ **Inclusion criteria:** The patients suspicious of prostatic nodule or enlargement.
- ✓ **Exclusion criteria :**

- Implanted electric and electronic devices are a relative contraindication to the magnetic resonance imaging, and in particular.
- Heart pacemakers (especially older types) ,Insulin pumps, implanted hearing aids, neurostimulators .
- Intracranial metal clips, metallic bodies in the eye.
- Renal impairment.

III. MRI Protocol And Its Important Features:–

MRI examinations were done on **1.5 Tesla MRI (1.5 Signa explorer)** with **body coil** in the **supine position**, and the protocol was as follows: T2WI and T1WI Axial and coronal, FOV, 350, slice thickness 3 mm and interval, 0.3 mm. **DCE-MRI Gad DETPA (gadolinium-Diethy lenetriaminepenta-acetic acid)** dose of **0.2 mmol/kg** (maximum dose 15 mmol) injected IV at a rate of 3 mL/s and Post Gad study were taken at the **early and delayed phases** (after 2 min to assess enhancement pattern and delayed after 5 min to assess washout). DWI with ADC values measurements: - DW images obtained at b0, 500, 1000 s/mm² gradients. (TR, 1570 ms; TE, 75, FOV 160 mm and slice thickness 3 mm); the region of interests (ROI), was placed on lesion to measure ADC values. ADC maps obtained from DW images at b0, b500 and b1000 s/mm² gradients. Lesions were assessed by using ESUR/PI-RADS criteria for DWI, T2WI, DCE-MRI, and by using the sum of these scores. Zonal dominant parameters corresponding to the score of DWI for PZ lesions and to T2WI for TZ lesions were calculated. PI-RAD V2 classification was used to define the total summation of the different Mp-MRI findings (DWI, T2, CDE) for differentiation between malignant and benign prostatic lesions (8).

Lesion assessment

All the lesions were evaluated by team of radiologists; all patients underwent TR U/S biopsy from the detected MRI focal lesion, shortly after the MRI examination (at a period ranging from few days to a maximum 2 weeks). All sequences were reviewed during a single session. The prostate was divided into 18 regions for purposes of review, 12 in the PZ and 6 in the TZ. First, the readers assigned a PI-RADS 2.0 score to each region. Briefly, this system entails assignment of a separate score from 1 to 5 to each region for each of the DW imaging, T2-weighted imaging, and DCE MRI sequences. For DCE MR Images, a binary scale was used (0 = no focal early enhancement; 1 = presence of early focal enhancement). In addition, the overall score consisted of the score for the dominant sequence (DWI for PZ lesions and T2-weighted for TZ lesions) plus one point added to the overall score for DCE MR imaging results that were positive for cancer.

Histopathologic examination

The prostatic biopsy was fixed in 4% buffered formaldehyde for approximately 48 h and was handled according to local clinical histopathologic routines for diagnostic purposes. A pathologist who was blinded to the imaging results examined the hematoxylin eosin and saffron stained slides, outlined cancer foci and described cancer location, and determined the cancer grade according to the Gleason grading system; Higher grade prostate cancer was defined as lesions showing a primary Gleason score pattern of 4 or higher(9).

Table.1 : - Analysis of final diagnosis of the 55 patients according to the histopathologic result.

Histopathology	No. of lesions	Percentage (%)
Adenocarcinoma	38	69.10
Benign prostate hypertrophy	11	20.00
Focal adenoma	04	07.20
Prostatitis	02	03.60
TOTAL	55	100.0

Table.2 : -Gleason score at biopsy for 38 malignant lesions.

Tumor Gleason score at TRUS biopsy (%)	No. of lesions (%)
6	13 (34.20 %)
7	12 (31.50 %)
8	08 (21.00 %)

Statistical analysis

Quantitative data were presented by mean and standard deviation, while qualitative data were presented by frequency distribution. The ADC values between malignant and benign groups were compared using Mann–Whitney test. $P < 0.05$ was considered statistically significant. The sensitivity, specificity, negative and positive predictive values (PPV) were assessed. Also, the ROC curve analysis was performed.

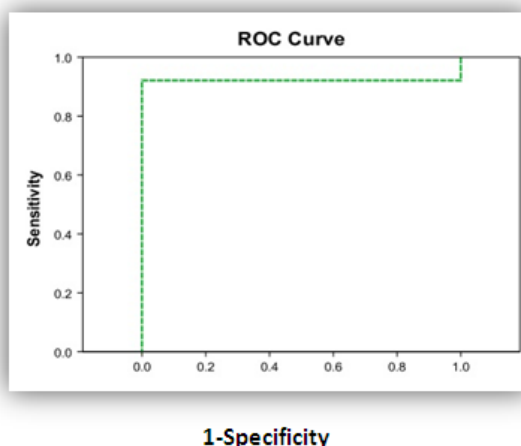


Fig. 1 ROC curve for the sensitivity and specificity of Mp-MRI with PI-RAD2.0 scoring system. “Assessment of the accuracy of multi-parametric MRI”

Table.3 : DWI with ADC value in 37 PZ lesions and T2WI in 18TZ lesions with DCE-MRI findings and PI-RADS 2.0 Scoring system.

PI-RADS Score	DWI PZ findings	No & Percentages	T2 TZ findings	No & Percentages
1	No abnormality	04 (10.80%)	No abnormality	06 (33.30%)
2	Indistinct area on ADC map	03 (08.10%)	Well defined hypo-intense/heterogonous	05 (27.70%)
3	Moderate diffusion restriction	06 (16.30%)	Heterogonous with obscured margin	03 (16.70%)
4	Marked diffusion restriction	16 (43.20%)	Non circumscribed hypo-heterogeneous	01 (05.60%)
5	>1.5 cm with marked restricted diffusion or invasive behavior	08 (21.60%)	>1.5 cm non circumscribed or invasive behavior	03 (16.70%)
ADC p < 0.001	Benign	-	-	30 (81.00%) 07(19.00%)
DCE-MRI				
Positive ----->	Malignant	28 PZ	08 PZ	65.50%
Negative ----->	Benign	09 PZ	10 PZ	34.50%

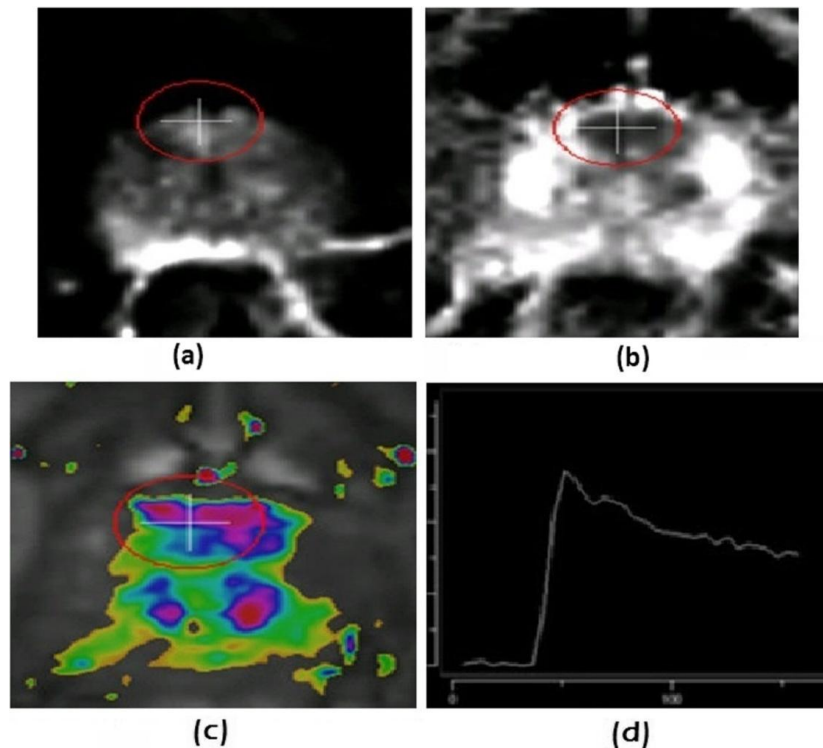


Fig. 2 : 58yrs old patient, with felt P/R hard suspicious prostate nodule, (a and b) DWI and ADC map revealed nodular lesion at the anterior aspect of PZ with significant diffusion restriction, ADC value measuring “0.8763”, (c and d) DCE-MRI revealed moderate enhancement with **type III enhancement curve** (PI-RADS 2.0, score = 4. All MP-MRI findings are collectively diagnostic of Malignant lesion. **Histo-pathology: Adeno-Ca. (Gleason score 8).**

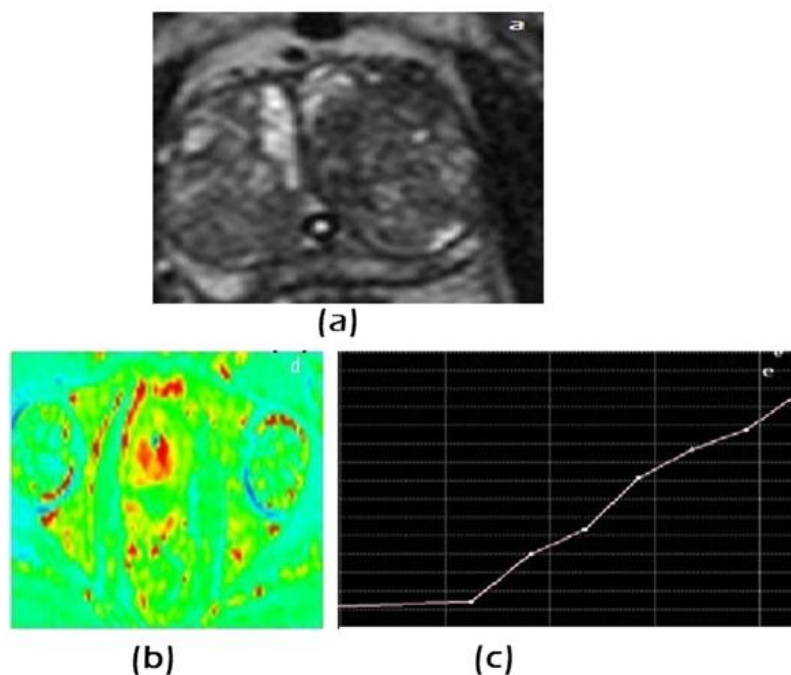


Fig. 3 68 yrs old patient, c/o : enlarged prostate with suspicious nodular gland felt by P/R (a) T2WI, showed heterogeneous texture with no definite well defined focal lesion, (b and c) DCE-MRI revealed gradual enhancement with persistent rising type I enhancement curve. All MP-MRI findings are diagnostic of Benign prostatic lesion: PI-RADS 2.0 score = 1, Histopathology: **Benign prostate hypertrophy, no malignancy.**

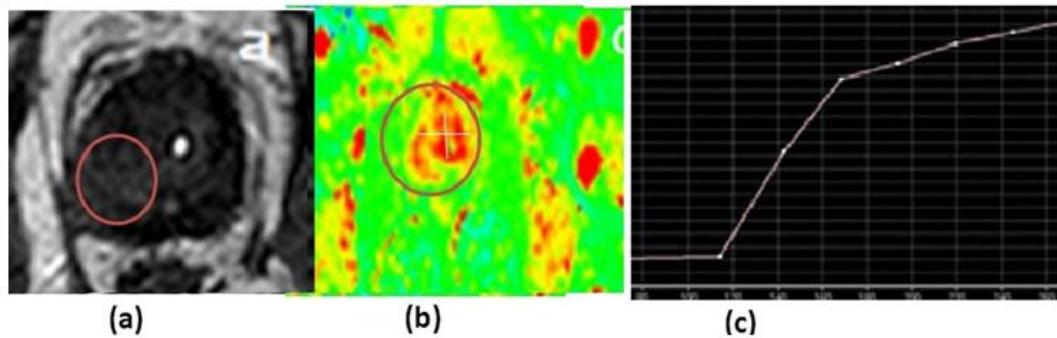


Fig. 4 60 yrs old patient, with hard suspicious Rt. prostatic nodule felt by at P/R examination. (a) T2WI, showed a non-homogenous poorly defined focal area at the Rt. sided TZ lesion (red circle). (b and c) DCE-MRI revealed early enhancement with type II enhancement curve. PI-RADS 2.0, score = 4 All MP-MRI findings are collectively diagnostic of Malignant lesion, **Histopathology: Adeno-Ca. (Gleason score 7)**.

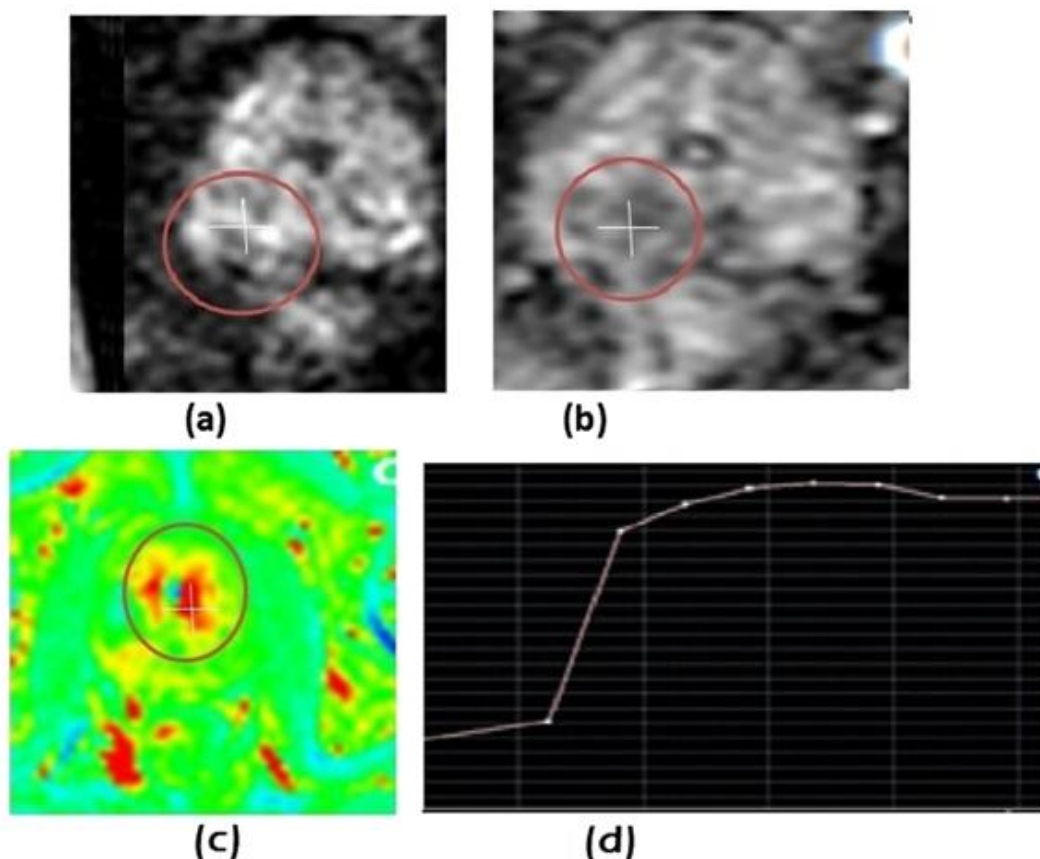


Fig. 5 69 yrs old patient, with hard suspicious Rt. prostatic nodule felt by P/R (a and b) DWI and ADC map revealed moderate diffusion restriction at Rt. side peripheral zone lesion (red circle), ADC value “0.958.93”, (c and d) DCE-MRI revealed mild enhancement with type II enhancement curve. PI-RADS 2.0 score = 3. All MP-MRI findings are collectively diagnostic of mostly Malignant lesion. **Histo-pathology: Adeno-Ca. (Gleason score 8)**.

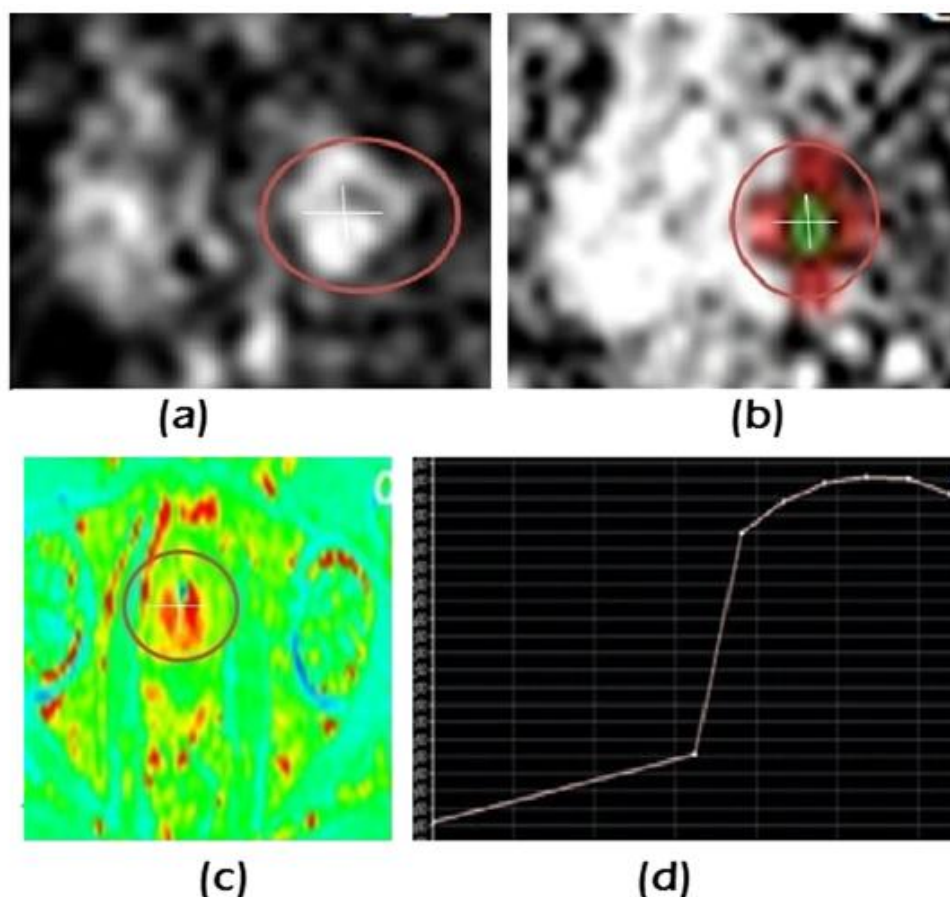


Fig. 6 66 yrs old patient with hard suspicious Lt. prostatic nodule at P/R examination. (a) DWI showed a moderate diffusion restriction of the lesion (red circle), (b) ADC map revealed, ADC value “0.641”, (c and d) DCE-MRI revealed early moderate enhancement (red circle),with type II enhancement curve). The total PI-RADS 2.0 score given to this lesion, was = 4. All Mp-MRI findings are collectively diagnostic of Malignant lesion. **Histopathology: Adeno-Ca. (Gleason score 8).**

IV. Results:-

Out of the 55 lesions included in this study, 38 lesions proved to be malignant: 30 lesions in the PZ and 8 in the TZ (Histopathology: Adenocarcinoma), while 17 lesions proved to be benign prostatic lesions; 7 in the PZ and 10 in the TZ (Histopathology: 11 benign prostate hypertrophy, 4 adenoma and 2 prostatitis) (Table 1 and 2). Mp-MRI {DWI with ADC value measurements for PZ lesions (37)} followed by Post Gad dynamic MRI findings and PI-RADS 2.0 scoring of the included prostatic suspicious lesions:-

I- DWI:-it showed focal moderate-marked diffusion restriction (scores 3 and 4) in 22 (6 and 16) lesions while score 5 was given to 8 lesions more than 1.5 cm or with invasive behavior; Mean ADC value was $0.89 \pm 0.24 \text{ lm}^2/\text{ms}$ for the lesions that proved to be malignant (see Fig.1). No abnormality/hypo-intense areas at ADC map were noted in 7 benign lesions. The ADC values of benign prostatic lesions were $1.34 \pm 0.21 \text{ lm}^2/\text{ms}$ which were statistically significantly higher than those of malignant lesion ($P < 0.001$) (Table3).

II-DCE-MRI, revealed focal enhancing lesion that showed early enhancement and early washout (+ve) in 28 lesions. Adding DCE MRI to DWI score in the 6 lesions with score 3 in lesions raises it to score 4 in 4/6 lesions that aid in the diagnosis of malignant lesions. No enhancement/gradual rising enhancement pattern(-ve) was noted in 9 (7 benign and 2 indeterminate) lesions (Table 3) (Figure. 2,5 and 6).Mp-MRI (T2 for TZ lesions) (10) followed by Post Gad dynamic MRI findings and PI-RAD2 scoring of the included prostatic suspicious lesions:-

III-T2WI of the TZ lesions detected 3 lesions that appeared as ill-defined heterogeneous signal intensity area (score 3) and non-circumscribed hypo-heterogeneous area (score 4)

in 1 lesion while lesions >1.5 cm or with invasive behavior diagnosed in 3 lesions. Eleven lesions with benign score (1–2) that appeared as normal or well defined hypo-intense/heterogeneous 6/5 lesions were detected in T2 WI (Table 3). DCEMRI, revealed focal enhancing lesion that showed early enhancement and early washout (+ve), in 8 lesions. Adding DCE MRI to T2WI score in score 3 in lesions raises it to score 4 in 2/3 lesions that aid in the diagnosis of malignant lesions. No enhancement/gradual enhancement pattern (-ve) was noted in 10 lesions (Table 3, Figures 3 and 4).

The total PI-RADS 2.0 score of Mp-MRI for the 55 suspicious prostatic lesions revealed 36 malignant lesions (scores, 4–5) and 16 benign lesions (scores 1–2) while indeterminate lesions were 3 (score 3) that pathologically proved to be 2 malignant and 1 benign lesions. The sensitivity, specificity and accuracy of MP-MRI in diagnosis of prostatic focal lesions using new PI-RADS score were 92.11%, 94.12% and 92.7% respectively (Table 4).

Table 4. Sensitivity, specificity and accuracy of Mp-MRI with PI-RADS 2.0 in diagnosis of prostatic focal lesions.

Sensitivity	92.11 %
Specificity	94.12 %
Positive Predictive value	97.22 %
Accuracy	92.72 %

V. Discussion:-

Prostate MR imaging provides the potential to assist clinical management of prostate cancer. Most recently, PI-RADS standardized interpretation scheme that facilitates greater clinical use of prostate MR imaging (11).

The histopathologic results were the gold standard for this work, it revealed 38 malignant “adenocarcinoma” and 17 benign lesions and the multi-parametric MRI examination of the prostate was the selected technique for lesion evaluation. This was concealed with Schlemmer et al. and Franiel who stated that the procedure of choice for diagnosing prostate cancer is the multi-parametric MRI (12,13).

This work used Mp-MRI findings with PI-RAD score V2 to differentiate malignant from benign lesions of the prostatic. For the PZ we considered DWI to be the primary determining sequence (dominant technique), while for the TZ, T2W is the primary determining sequence. This was in agreement with Leonardo et al. who introduced the concept of a zonal dominant parameter in an attempt to incorporate to ESUR/PI-RADS criteria the performance of different techniques applied to peripheral and transitional zone lesions (14). Also, Baur et al. reported that assigning a PI-RADS score on the basis of DWI for PZ lesions and a PI-RADS score on the basis of T2-weighted imaging for TZ lesions was sufficient for stratification of patients for further diagnostic workup (15).

For the 37 lesions located in PZ we considered DWI that categorized 6 lesions with score 3, 16 lesions with score 4 and 8 lesions were given score 5; Mean ADC value was $0.89 \pm 0.24 \text{ lm}^2/\text{ms}$ for the lesions that proved to be malignant. However, no abnormality/hypo-intense areas at ADC map were noted in 7 benign lesions. The ADC values of benign prostatic lesions were $1.34 \pm 0.21 \text{ lm}^2/\text{ms}$ which were statistically significantly higher than that of malignant lesion ($P < 0.001$).

The total PI-RAD score V2 of Mp-MRI for the 55 suspicious prostatic lesions revealed 36 malignant lesions (scores, 4–5) and 16 benign lesions (scores 1–2) while indeterminate lesions were 3 (score 3) that pathologically proved to be 2 malignant and 1 benign lesions.

This matched results of other studies regarding the PI-RADS classification system which suggests high reliability for Mp-MRI interpretation and its sum-score shows a strong relation to tumor incidence and malignancy in the routine setting for prostate cancer diagnosis (25,26). At present, Mp-MRI is the most sensitive and specific imaging technique for localizing prostate cancer (27).

The statistical results of this study revealed that, Sensitivity, Specificity and Accuracy of MP-MRI in diagnosis of prostatic focal lesions using new PI-RAD2.0 score were, 92.11%, 94.12% and 92.7% respectively. This was in concordance with results of Daniel who found that the sum PI-RAD score is reliable for cancer detection (sensitivity 90%, specificity 62%)

(28) and Alistair et al. found that 2 out of 88 men with Pi-RAD score of 1 or 2 had significant prostate cancer, giving a sensitivity of 97% and a specificity of 60% at this threshold (29) while Portalez et al. results showed that the sensitivity is 73.5%; specificity is 81.5%; and accuracy is 95.2% (26).

VI. Conclusions :-

PI-RAD V2 scoring of the Multi-parametric MRI, including DWI with ADC measurements, T2WI added to DCE-MRI, was proved to be a sensitive, non invasive and accurate tool for characterization of prostatic focal lesions and distinguishing between malignant and benign lesions.

References :-

- [1]. Dickinson L, Ahmed HU, Allen C, et al. Magnetic resonance imaging for the detection, localization, and characterization of prostate cancer: recommendations from a European consensus meeting. *Eur Urol* 2011;59:477–94.
- [2]. Daniel J, Georg S, Michael E, et al. Evaluation of the PI-RADS Scoring System for classifying mpMRI findings in men with suspicion of prostate cancer. *BioMed Res Int* 2013;9: 252939.
- [3]. Barentsz JO, Richenberg J, Clements R, et al. ESUR prostate MR guidelines 2012. *Eur Radiol* 2012;22:746–57.
- [4]. Joyce GR, Jelle OB. Standardization of multiparametric prostate MR imaging using PI-RADS (Review Article). *BioMed Res Int Vol* 2014;9: 431680.
- [5]. Hamoen EH, de Rooij M, Witjes JA, et al. Use of the prostate imaging reporting and data system (PI-RADS) for prostate cancer detection with multiparametric magnetic resonance imaging: a diagnostic meta-analysis. *Euro Urol* 2015;67:1112–21.
- [6]. Jelle OB, Jeffrey CW, Sathna V, et al. Synopsis of the PI-RADS v2 guidelines for multiparametric prostate magnetic resonance imaging and recommendations for use. *Euro Urol* 2016;69:41–9.
- [7]. Muller BG, Shih JH, Sankineni S, et al. Prostate cancer: interobserver agreement and accuracy with the revised prostate imaging reporting and data system at multiparametric MR imaging. *Radiology* 2015;277(3):741–50.
- [8]. Rothke M, Blondin D, Schlemmer HP, et al. PI-RADS classification: structured reporting for MRI of the prostate. *Clin Men's Health* 2013, MAGNETOM Flash | 4 / www.siemens.com/magnetom-world.
- [9]. Meltem E, Mehmet R, Nusret A, et al. Utility of ADC measurement on diffusion-weighted MRI in differentiation of prostate cancer, normal prostate and prostatitis. *Quant Imag Med Surg* 2013;3(4):210–6.
- [10]. Rosenkrantz AB, Kim S, Lim RP, et al. Prostate cancer localization using multiparametric MR imaging: comparison of Prostate Imaging Reporting and Data System (PI-RADS) and Likert scales. *Radiology* 2013;269(2):482–92.
- [11]. Schlemmer HP. Multiparametric MRI of the prostate: method for early detection of prostate cancer. *Fortschr Röntgenstr* 2010;182:1067–75.
- [12]. Franiel T. Multiparametric magnetic resonance imaging of the prostate – technique and clinical applications. *Fortschr Röntgenstr* 2011:607–17.
- [13]. Leonardo KB, Geert L, Christina AH, et al. Prostate cancer: the european society of urogenital radiology prostate imaging reporting and data system criteria for predicting extra-prostatic extension by using 3-T multiparametric MR imaging. *Radiology* 2015;2:479–89. August.
- [14]. Baur AD, Maxeiner A, Franiel T, et al. Evaluation of the prostate imaging reporting and data system for the detection of prostate cancer by the results of targeted biopsy of the prostate. *Invest Radiol* 2014;49(6):411–20.
- [15]. Zelhof B, Pickles M, Liney G, et al. Correlation of diffusion weighted magnetic resonance data with cellularity in prostate cancer. *BJU Int* 2009;103(7):883–8.
- [16]. Koo JH, Kim CK, Choi D, et al. Diffusion-weighted magnetic resonance imaging for the evaluation of prostate cancer: optimal B value at 3T. *Korean J Radiol* 2013;14:61–9.
- [17]. Noha MA, Hytham HE, Essam AA. The role of diffusion-Weighted MRI in evaluation of prostate cancer. *Egypt J Radiol Nucl Med* 2013. Available online 23 December 2013.
- [18]. Sato C, Naganawa S, Nakamura T, et al. Differentiation of non-cancerous tissue and cancer lesions by apparent diffusion coefficient values in transition and peripheral zones of the prostate. *J Magn Reson Imag* 2005;21:258–62.
- [19]. Akin O, Sala E, Moskowitz CS, et al. Transition zone prostate cancers: features, detection, localization, and staging at endorectal MR imaging. *Radiology* 2006;239:784–92.
- [20]. Sandeep S, Murat O, Peter LC. Functional MRI in prostate cancer detection. *BioMed Res Int Vol* 2014;8: 590638.
- [21]. Alonzi R, Padhani AR, Allen C. Dynamic contrast enhanced MRI in prostate cancer. *Eur J Radiol* 2007;63:335–50.
- [22]. Sciarra A, Panebianco V, Ciccariello M, et al. Magnetic resonance spectroscopic imaging (1H-MRSI) and dynamic contrast enhanced magnetic resonance (DCE-MRI): pattern changes from inflammation to prostate cancer. *Cancer Invest* 2010;28:424–32 (51, 52).
- [23]. Hara N, Okuizumi M, Koike H, et al. Dynamic contrast-enhanced magnetic resonance imaging (DCEMRI) is a useful modality for the precise detection and staging of early prostate cancer. *Prostate* 2005;62:140–7.
- [24]. Schimmoller L, Quentin M, Arsov C, et al. Inter-reader agreement of the ESUR score for prostate MRI using inbore MRI-guided biopsies as the reference standard. *Euro Radiol* 2013;23 (11):3185–90.
- [25]. Portalez D, Mozer P, Cornud F, et al. Validation of the European Society of Urogenital Radiology scoring system for prostate cancer diagnosis on multiparametric magnetic resonance imaging in a cohort of repeat biopsy patients. *Euro Urol* 2012;62 (6):986–96.
- [26]. Sciarra A, Barentsz J, Bjartell A, et al. Advances in magnetic resonance imaging: how they are changing the

- management of prostate cancer. *Eur Urol* 2011;59(6):962–77.
- [27]. Daniel JA, Margolis. Multiparametric MRI for localized prostate cancer: lesion detection and staging (Review Article). *BioMed Res Int* 2014;11 684127.
- [28]. Alistair DR, Manik SC, Rick P, et al. Diagnostic accuracy of magnetic resonance imaging (MRI) prostate imaging reporting and data system (PI-RADS) scores in a transperineal prostate biopsy setting. *BJU Int* 2015;115(5):728–35.
- [29]. (29) Alistair DR, Manik SC, Rick P, et al. Diagnostic accuracy of magnetic resonance imaging (MRI) prostate imaging reporting and data system (PI-RADS) scores in a transperineal prostate biopsy setting. *BJU Int* 2015;115(5):728–35.

Dr. Asutosh Dave, et. al. “Multiparametric Magnatic Resonance Imaging In Prostate Malignancy And Pi-Rads Correlation.” *IOSR Journal of Dental and Medical Sciences (IOSR-JDMS)*, 20(11), 2021, pp. 62-70.