

Role of Diffusion Weighted MRI of Cervical Lymph Nodes in Head and Neck Malignancies

Dr. Arvinder Singh*, Dr. Aditi Kundan**, Dr. Bikramjit Singh***
Dr. Manjeet kaur****

*Professor and Head, Department of Radiology,

** Junior Resident, Department of Radiology,

*** Associate Professor, Department of Surgery,
Govt. Medical College, Amritsar.

****Professor, Department of Physiology, SGRDUHS, Amritsar.

Corresponding Author : Dr. Aditi Kundan, Junior Resident, Department of Radiology, Govt. Medical College, Amritsar (Punjab)

Abstract:

Introduction: Cervical lymph node metastasis is one of the important prognostic factor in staging and management of head and neck malignancy. The definitive diagnostic method for lymph node analysis is histopathology which is invasive. However, Diffusion weighted MRI has emerged as good alternative for the characterization of cervical lymph nodes in head and neck malignancy. A differential diagnosis of benign and malignant lesions of the head and neck is critical as it enables clinicians to implement appropriate management strategies for malignant lesions.

Aims and objectives: To assess the diagnostic utility of diffusion weighted MRI sequence and ADC values for the characterization of cervical lymph nodes in head and neck malignancies.

Material and Methods: Fifty patients with clinically suspected or newly diagnosed head and neck malignancies were subjected to MRI neck or MRI face and neck. The study assessed cervical lymph nodes in patients with head and neck malignancies by characterizing them into benign and malignant using DWI MRI and ADC value calculation with histopathology/cytology reference study. The findings were compared and analysed statistically.

Results: Majority of patients studied were in the age group of less than 60 years. The study included head and neck malignancies like buccal mucosa, tongue cancer, hypopharyngeal and laryngeal cancers, alveolus cancer, thyroid cancer etc. Most of patients in our study presented with complaint of dysphagia and non healing ulcer in mouth with/without trismus with pain or bleeding from ulcer. About 84% patients had past history of chronic smoking out of which 62% were chronic alcoholic. A total of 311 cervical lymph nodes seen in these malignancies were assessed on DWI and ADC values. Out of 311 cervical lymph nodes, 103 nodes showed metastasis (33.1%) and the rest 208 cervical lymph nodes were negative for metastasis (66.9 %). Majority of metastatic cervical lymph nodes observed in head and neck malignancies in our study were squamous cell carcinoma. The mean ADC value of $0.594 \times 10^{-3} \text{ mm}^2/\text{s} \pm 0.197$ was observed in metastatic lymph nodes and value of $1.04 \times 10^{-3} \text{ mm}^2/\text{s} \pm 0.710$ in non-metastatic lymph nodes with p value less than 0.001 which was statistically significant. DWI and quantitative analysis of ADC values revealed that mean ADC value of metastatic nodes was significantly lower than that of the non-metastatic nodes.

Conclusion: DWI sequence of MRI has been the advantage for detecting micro structural changes in the tissue. Hence, Diffusion-weighted MR imaging is an effective assist in differentiating benign and malignant cervical lymph nodes in patients of head and neck malignancies. It has been considered as a cancer biomarker. It is non invasive technique and does not have any radiation exposure.

Keywords: Apparent diffusion coefficient, Diffusion weighted magnetic resonance imaging, Receiver operating characteristic, Region of interest, fine needle aspiration biopsy, histopathology, squamous cell carcinoma.

Date of Submission: 10-02-2021

Date of Acceptance: 24-02-2021

I. Introduction:

Head and neck cancers account for the sixth most common type of cancer worldwide¹, with betel, tobacco and alcohol consumption being important risk factors causing significant morbidity and mortality.^{2, 3} Squamous cell carcinoma (SCC) is the most common malignant histology in the head and neck region and originates from the epithelial lining of the upper aero digestive tract.^{4,5} These tumors are characterized by a multiphase and multifactorial etiopathogenesis.⁶ Approximately two-thirds of patients with head and neck

cancers present with advanced stage disease, commonly involving regional lymph nodes, which require an amplified and aggressive treatment regimen consisting of neoadjuvant therapy and extensive surgery.⁷ Depending on the primary site, up to 80% of patients with upper aero digestive mucosal malignancy will have cervical nodal metastasis at presentation. Cervical nodal metastases are therefore a very common clinical problem. Radiologists should be familiar with the simplified level classification system currently used by both head and neck surgeons and pathologists who use the same system, when they report on the involvement of cervical nodes in radical neck dissection specimens.

Cervical lymph nodes classification system -

Rouviere classified cervical nodes into a collar of nodes surrounding the upper aero digestive tract (sub mental, facial, submandibular, parotid, mastoid, occipital and retropharyngeal) and two groups along the long axis of the neck (anterior cervical and postero-lateral cervical groups).⁸ Surgeons, however, make use of the simplified level system advocated by Shah, *et al.* at the Memorial Sloan-Kettering Cancer Center, New York.^{9,10} correlates the simplified level system and the corresponding anatomical location of cervical nodes.

Posterior boundary of submandibular gland

Sternocleidomastoid muscle

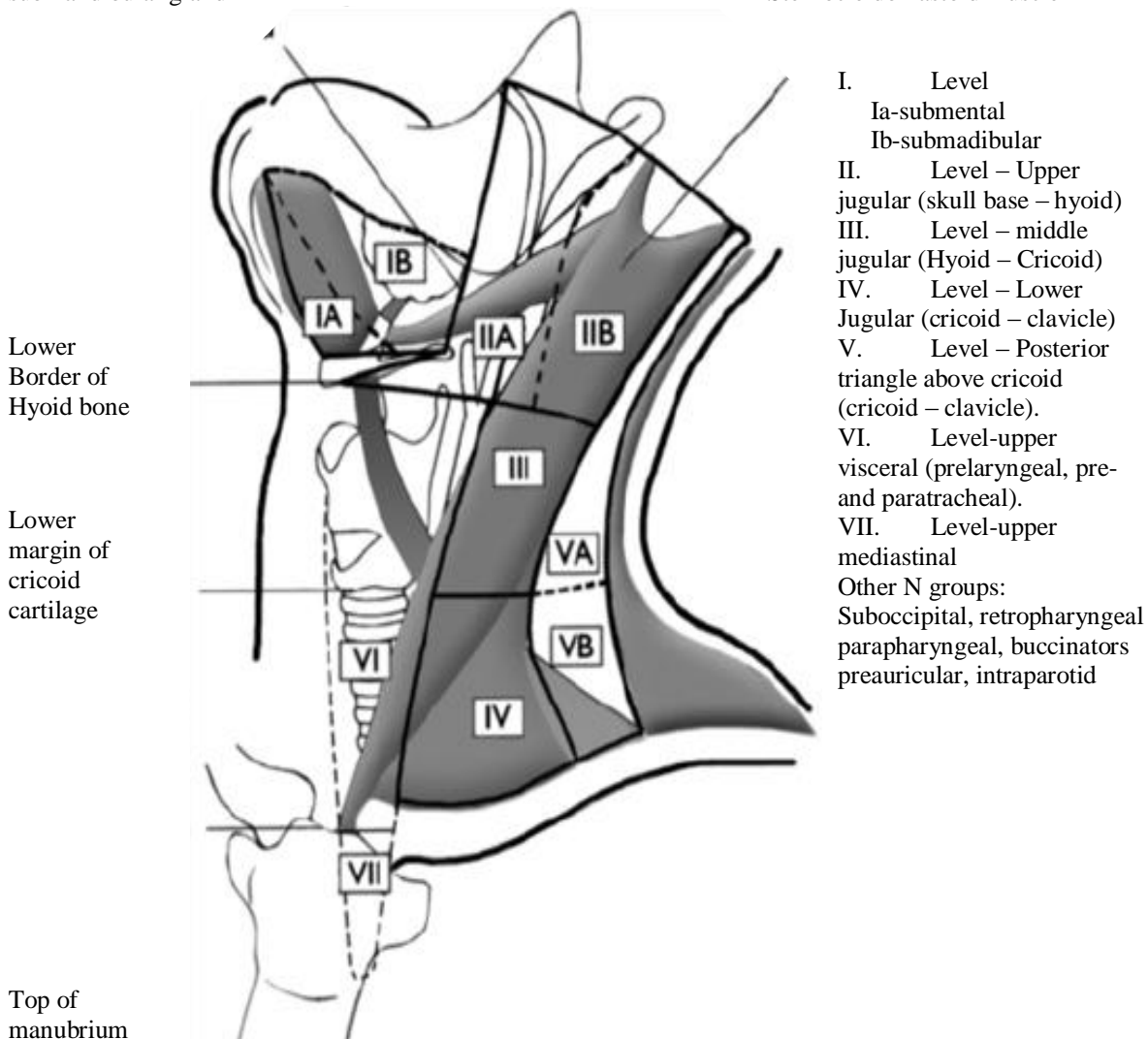


Fig.1. Rouviere H. Anatomy of the Human Lymphatic System. Ann Arbor, MI: Edward Brothers; 1938.

The nodal metastases have a great impact on treatment and prognosis in head and neck cancer.

Detection of nodal metastasis by imaging is more accurate than clinical examination. Recently, DWI has also been proposed as a sensitive marker for monitoring treatment response and metastasis in head and neck cancer. The standard work-up for patients with SCC of the head and neck includes evaluation of pathological lymph nodes along with staging of the primary tumor and evaluation of the presence of distant metastasis before

making a decision regarding the appropriate treatment regimen (chemo radiation therapy versus surgery), as lymphatic metastasis is an important mechanism of tumor spread.¹¹

Metastatic SCC lymph nodes are heterogeneous in nature and contain variable degrees of necrotic parts and keratin protein contents.^{12,13} Based on these features, lymph nodes are associated with alterations in water diffusivity and thus, DWI may play an important role in their characterization. Several studies have reported the ability of DWI to discriminate malignant from benign lymph nodes in the neck^{14,15}, with the metastatic nodes exhibiting lower ADC values compared with benign lymph nodes. DWI has been demonstrated to have improved sensitivity in the detection of subcentimeter nodal metastases.^{16,17}

II. Material And Methods

The study was conducted in the Department of Radio-diagnosis & Imaging, Guru Nanak Dev Hospital/ Govt. Medical College Amritsar, Punjab from June 2018 to November 2020 in which fifty patients with clinically suspected or newly diagnosed head and neck malignancies were included in the study. Patients not subjected subsequently to FNAC/histopathology correlation of cervical lymph nodes or patients undergoing preoperative chemotherapy or radiotherapy for any head and neck malignancy or patients with contraindications for MRI eg. cardiac pacemakers or defibrillators, metallic foreign bodies, cochlear implants, magnetic dental implants, MRI incompatible prosthetic heart valves or MRI incompatible clips were excluded from the study.

Imaging Technique: The data was analyzed using Siemens machine having software NUMARIS/4 – MR 52149 and NUMARIS/4 syngo MR D13.

Cervical lymph nodes on either side of neck on T1W and T2W images were selected. Each lymph node was then compared with axial DWI showing bright signals in corresponding region. ROI was placed manually on bright lymph node excluding necrotic areas wherever possible. Automatic ADC values were shown after placing the ROI. Correlation between DW MRI in cervical lymph nodes characterization (into benign and malignant) and histopathology/cytology diagnosis as gold standard reference was done. ROC curve was drawn and area under curve (AUC) was used to calculate cut off ADC value for differentiating benign and malignant nodes. These values were tabulated and further analyzed statistically.

III. Results:

In our study, 84% were males and 16% were females, their ages ranged between 25 years to 80 years with a mean age of 54.8 years.

Out of 50 patients in our study, 21 (42%) patients presented with dysphagia, 16 (32%) patients with non healing ulcer in mouth with/without trismus, 5 (10%) with neck swelling, 4 (8%) with complaint of hoarseness of voice, 3 (6%) with bleeding from mouth, 2 (4%) with odynophagia and 1 (2%) patient presented with sore throat.(Table I) *One patient presented with bleeding from mouth along with dysphagia and one patient had complaint of non healing ulcer in mouth with bleeding.

**TABLE I
PRESENT HISTORY**

Present History	No. of cases (n=50)	Percentage
Bleeding From Mouth	3	6.0
Hoarseness of voice	4	8.0
Dysphagia	21	42.0
Neck swelling	5	10.0
Non Healing Ulcer	16	32.0
Odynophagia	2	4.0
Sore Throat	1	2.0

84% patients in our study had a past history of chronic tobacco consumption (smoking/chewing), 62% patients were chronic alcoholic, 10% patients had history of tongue bite and 4% patients had past history of dental extraction.(table II) * 31 patients had history of both tobacco and alcohol intake. None of the 50 patients had a positive family history for head and neck malignancy.

**Table II
PAST HISTORY IN 50 STUDY CASES**

Past History	No. of cases (n=50)	Percentage
Tobacco consumption	42	84.0%
Alcoholic	31	62.0%
Tongue bite	5	10.0%
Dental extraction	2	4.0%

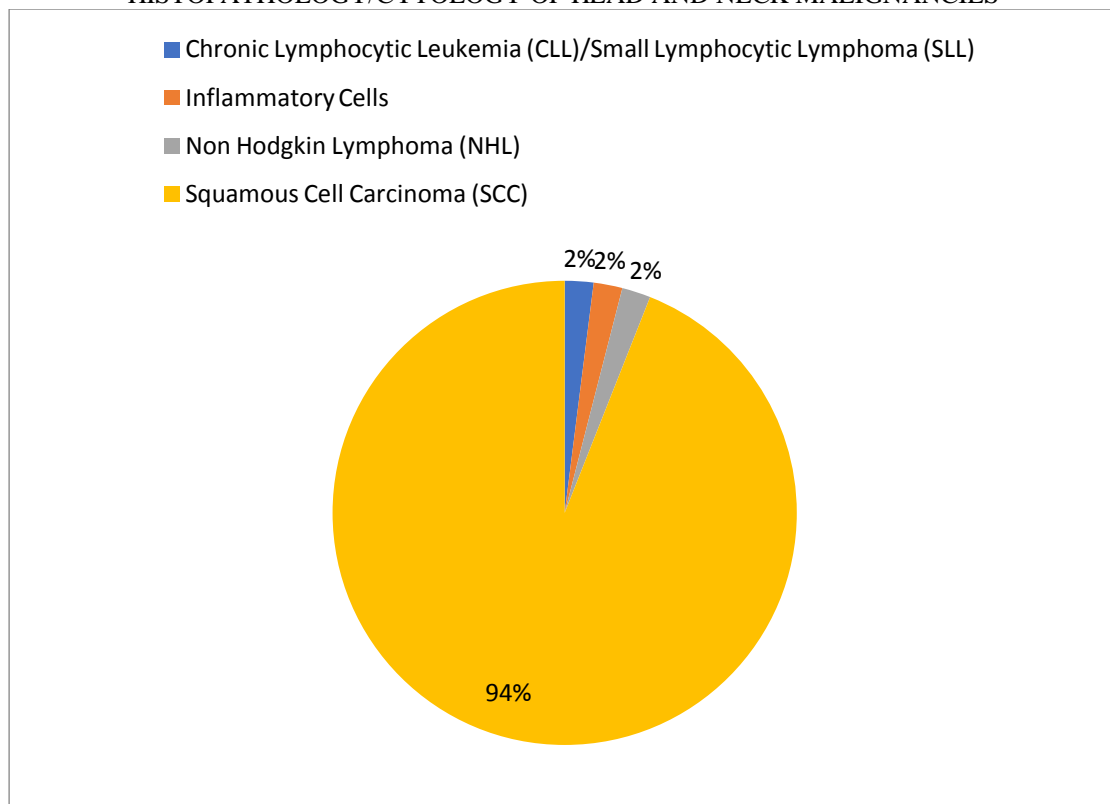
11 different sites of head and neck malignancies were studied which included tongue(20%), buccal mucosa (24%),supraglottis (24%),transglottis (14%),alveolus (4%),bilateral cervical lymphadenopathy (6%),hypopharynx (4%), thyroid gland (2%) and cervical esophagus(2%).(table III) .

Table III
PRIMARY SITE OF HEAD AND NECK CANCER

Primary site	No. of cases	Percentage
Bilateral cervical lymphadenopathy	3	6.0
Cervical oesophagus	1	2.0
Alveolus	2	4.0
Base of tongue	10	20.0
Buccal mucosa	12	24.0
Supraglottis	12	24.0
Thyroid	1	2.0
Transglottis	7	14.0
Hypopharynx	2	4.0
Total	50	100.0

Out of 50 cases studied, 47 cases were Squamous Cell Carcinoma (94%), 2 were Chronic Lymphocytic Leukemia (CLL)/Small Lymphocytic Lymphoma (SLL) (2%), 1 was Non Hodgkin Lymphoma (2%), 1 was inflammatory cells (2%).(graph I).

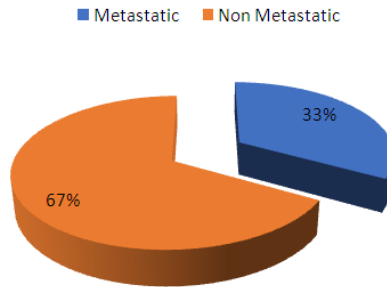
Graph I
HISTOPATHOLOGY/CYTOLOGY OF HEAD AND NECK MALIGNANCIES



All the cervical lymph nodes studied on either side of the neck showing restriction of diffusion on DWI/ADC MRI were selected in all 50 patients of head and neck malignancies and corresponding ADC values were analyzed. Histopathology/FNAC was considered as the gold standard for comparison.

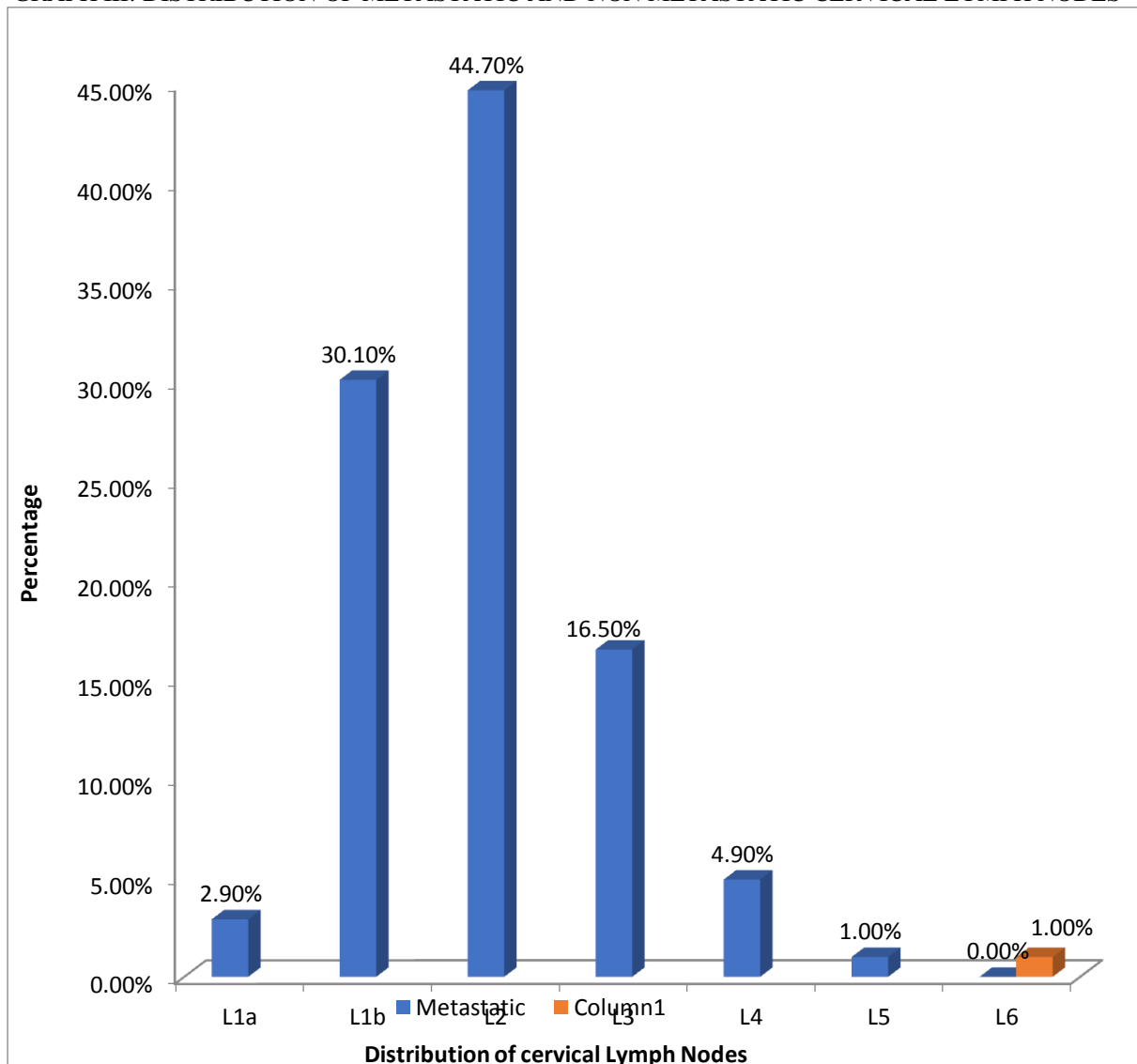
A total of 311 cervical lymph nodes were identified on DWI MRI and corresponding ADC values were tabulated and compared with FNAC or histopathology. Out of 311 cervical lymph nodes, 103 nodes showed metastasis (33.1%) and the rest 208 cases were non-metastatic (66.9 %) in nature.(Graph II)

Graph II: HISTOPATHOLOGY/CYTOLOGY ANALYSIS OF LYMPHNODES



Out of 103 metastatic nodes, 3 nodes (2.9 %) belongs to the submental (level Ia) group of lymph nodes, 31 nodes (30.1 %) belongs to the submandibular (level Ib) group of lymph, 46 nodes (44.7%) were seen in the upper jugular (level II), 17 nodes (16.5%) were seen in the middle jugular(level III), 5 nodes (4.9%) were seen in the lower jugular (level IV) and 1 node (1.0%) was seen in the level V group of cervical lymph nodes(graph III).

GRAPH III: DISTRIBUTION OF METASTATIC AND NON METASTATIC CERVICAL LYMPH NODES

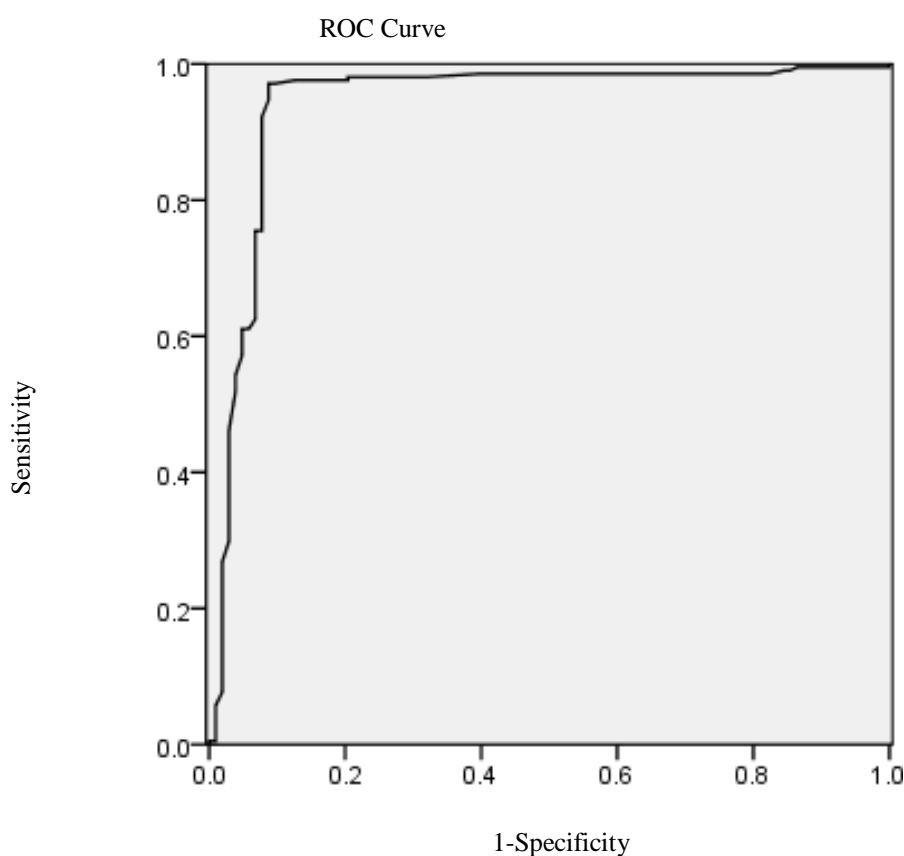


ADC values of all the 311 lymph nodes were evaluated and were compared with the histopathology/cytology findings. The mean ADC values of all the metastatic lymph nodes was $0.594 \times 10^{-3} \text{ mm}^2/\text{s}$ which was significantly lower than the mean ADC value of non-metastatic lymph nodes ($1.04 \times 10^{-3} \text{ mm}^2/\text{s}$) (p value less than 0.001). (Table IV).

Table IV
MEAN ADC VALUES OF CERVICAL LYMPH NODES

Histopathology/cytology	No. of nodes	Mean ADC \pm S.D.	Range	Std. Error Mean
Metastatic	103	0.60 \pm 0.20	1.56	0.01942
Non Metastatic	208	1.05 \pm 0.71	10.68	0.04924
Total	311	0.90 \pm 0.63	10.68	

Diagnostic performance was evaluated by drawing ROC curves for discriminating metastatic from non-metastatic cervical lymph nodes which showed as a threshold ADC value of $0.800 \times 10^{-3} \text{ mm}^2/\text{s}$ and area under ROC curve showed as a value of 0.941 which was statistically significant with p value of less than 0.001.



In our study involving 311 lymph nodes, 94 nodes showed true positive findings with ADC value $< 0.800 \times 10^{-3} \text{ mm}^2/\text{s}$ and metastasis on histology/cytology whereas 201 nodes were true negative with ADC value $\geq 0.800 \times 10^{-3} \text{ mm}^2/\text{s}$ and no evidence of metastasis on histology/cytology. Rest of the 9 nodes showed false negative findings with ADC values $\geq 0.800 \times 10^{-3} \text{ mm}^2/\text{s}$ and metastasis on histology/cytology whereas 7 nodes were false positive with ADC values $< 0.800 \times 10^{-3} \text{ mm}^2/\text{s}$ and no evidence of metastasis on histology/cytology (Table V).

Table V
COMPARISON OF ADC VALUES WITH HISTOPATHOLOGY/CYTOLOGY OF LYMPH NODES

ADC Value(x 10 ⁻³ mm ² /s)	Histopathology/cytology		Total
	Metastatic	Non-Metastatic	
<0.80	94 91.3%	7 3.4%	101 32.5%
≥0.80	9 8.7%	201 96.6%	210 67.5%
Total	103 100.0%	208 100.0%	311 100.0%

DIAGNOSTIC EVALUATION OF CERVICAL LYMPH NODES BASED ON ADC VALUE IN FIFTY STUDY CASES :

Diagnostic evaluation of this study for differentiation between metastatic and non-metastatic cervical lymph nodes revealed sensitivity, specificity, PPV, NPV of 91.2%, 96.6%, 93.0% and 95.7 % respectively at 95% confidence intervals. The diagnostic accuracy of test was 94.85%. The result revealed p values of less than 0.001 which was statistically significant. (Table VI).

Table VI

Sensitivity	91.2%
Specificity	96.6%
Positive Predictive Value	93.0%
Negative Predictive Value	95.7%
Accuracy	94.85%
'p' value	0.000 (Significant)

IV. Discussion:

Cervical lymph node involvement plays an important role in the staging, prognosis and treatment plan of the patients of head and neck malignancies.^{17,18,19} Clinical assessment of cervical lymph node involvement in patients of head and neck malignancies includes palpation of enlarged cervical lymphadenopathy. However, metastatic involvement could be found in non enlarged or normal sized lymph nodes also with prevalence of 30 % in cervical lymph nodes and thus contributing to false negative results.^{20,21} Imaging diagnosis of metastatic lymph nodes include size as well as morphological characteristics of lymph nodes such as heterogeneity, areas of necrosis or contrast enhancement patterns.^{20,21} DW-MRI is an effective non-invasive imaging technique for tissue characterization. Our study aimed to establish the diagnostic validity of the diffusion-weighted magnetic resonance imaging for the distinction between benign and malignant lymph nodes via comparing the ADC values, as solving out this diagnostic problem is mandatory for the management of the patients.²² It is non invasive technique and does not have any radiation exposure.^{18,23, 24}

Our study revealed that prevalence of head and neck malignancies was higher in males(84%) than females(16%).This was consistent with the gender distribution reported by various authors.^{25,26,27,28,29,30} In present study, age distribution ranged from 25 years to 80 years with a mean age of 54.8 years. This was in agreement with De bondt RBJ²⁵, Zhong J et al²⁷, Parihar P and Goel V²⁸, Ali TF and El Hariri MA²⁹ who reported a mean age of 59 years, 53.6 years, , 53 years , 53.1 years respectively.

Majority of patients (42%) in our study presented with complaint of dysphagia, 32% had complaint of non healing ulcer in mouth with/without trismus and pain or bleeding from ulcer,10% came with complaint of neck swelling, 8% with complaint of hoarseness of voice, 6% with bleeding from mouth,4% with odynophagia and 2% with sore throat. This was in consistent with findings of Dhull AK³⁰ who had reported that oropharyngeal dysphagia is common in patients with head and neck cancer (HNC).

In our study, 84% patients were chronic smoker (including only smokers + smokers as well as alcoholics) out of which 22% were only smokers. 62% patients were chronic alcoholic, 10% patients had past history of tongue bite and 4% patients had history of previous dental extraction. Patients with history of both tobacco consumption and alcohol intake are 62%.This was consistent with Dhull AK³⁰ who reported that 89% patients were total smokers, i.e. (only smokers + smokers as well as alcoholics) out of which 36% patients were only smokers. In this analysis, 59% were total alcoholics i.e. (only alcoholic + smokers as well as alcoholics) out of which 6% were only alcoholics. Patients who were consuming both types, i.e. alcohol and smoking were 53%. The present study evaluated cervical lymph nodes in head and neck malignancies arising from various sites including 12 cases of buccal mucosa cancers, 12 cases of supraglottic cancer, 10 cases of tongue cancer, 7 cases of tranoglottic cancer, 3 case of cervical lymphadenopathy, 2 cases each of alveolus and hypopharynx

cancers and 1 case each of thyroid cancer and cervical esophageal cancer. This finding was in conformity with De bondt RBJ et al.²⁵

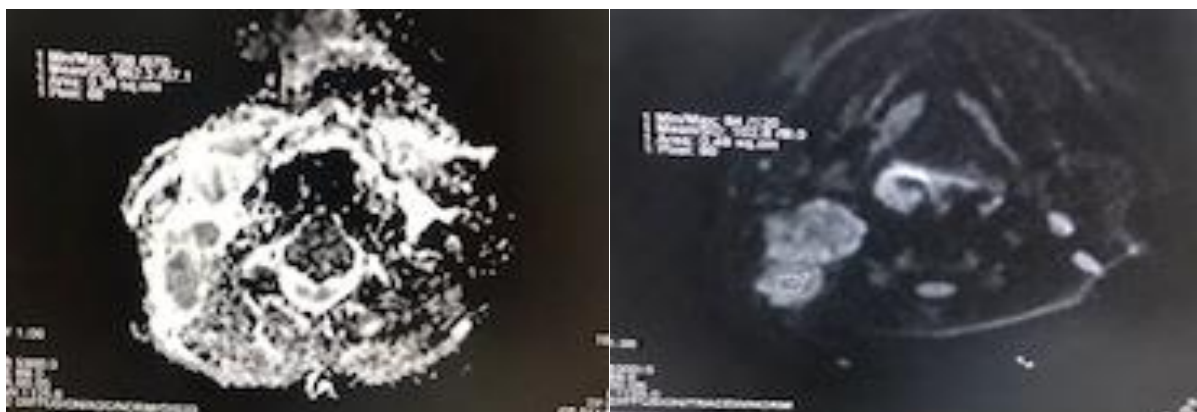
Majority of metastatic cervical lymph nodes in our study were observed in head and neck malignancies are squamous cell carcinoma (SCC). Out of 50 head and neck malignancies studied, 47 were SCC (94%), 1 each of Chronic Lymphocytic Leukemia (CLL)/Small Lymphocytic Lymphoma (SLL) (2%), Non Hodgkin lymphoma (2%) and inflammatory cells (2%). This was in conformity with findings of De Bondt RB et al¹⁷, Zhong J et al²⁷, Funk GF et el⁴ and Syrjanen S⁵ who reported that 90% of head and neck malignancies are Squamous cell carcinoma (SCC).

Total 311 cervical lymph nodes were identified on DWI. All the nodes revealed homogenous hyperintense signal on DWI and hypointense signal on ADC. Out of 311 lymph nodes, 103 nodes showed metastasis (33.1%) and 208 cases were non-metastatic (66.9 %) on FNAC/HP in our study. This finding was with conformity with study of De bondt RBJ et al²⁵ who reported metastatic node based prevalence of 27.2% in 26 patients including 219 cervical lymph nodes and in meta-analysis of 17 studies by Bondt RBJ et al¹⁷ who reported a variation of 20-77% in the prevalence of lymph node metastasis in patient of head and neck malignancies.

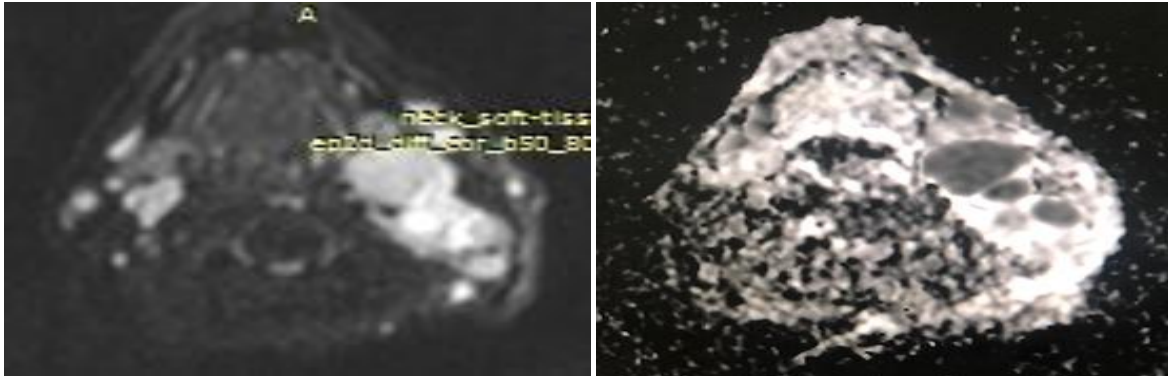
Out of 103 metastatic nodes, 3 nodes (2.9 %) belongs to the submental(level Ia) group of lymph nodes, 31 nodes (30.1 %) belongs to the submandibular (level Ib) group of lymph, 46 nodes (44.7%) were seen in the upper jugular (level II), 17 nodes (16.5%) were seen in the middle jugular(level III), 5 nodes (4.9%) were seen in the lower jugular(level IV) and 1 node (1.0%) was seen in the level V group of cervical lymph nodes. This was in consistent with findings of Jin GQ et al³¹ who was reported that majority (59.1%) of the malignant lymph node belonged to the upper jugular (level II) group of cervical lymph nodes.

In our study, quantitative analysis of diffusion weighted MRI images with calculation of ADC values for all 311 nodes was performed. The mean ADC value ($\times 10^{-3}$ mm²/s) for total, metastatic and non metastatic lymph nodes was 0.897×10^{-3} mm²/s \pm 0.628, 0.594×10^{-3} mm²/s \pm 0.197, and 1.046×10^{-3} mm²/s \pm 0.710 respectively. ADC value evaluation revealed statistically significant lower mean ADC value of metastatic lymph nodes than that of the non metastatic nodes with a p value of less than 0.001. The results are consistent with previous studies published by Holzapfel K et al²⁶, Zhong J et al²⁷, Parihar P and Goel V²⁸ and Peronne A et al.³² All these authors reported a statistically significant difference between the mean ADC values of benign and malignant /metastatic cervical lymph nodes. Holzapfel K et al²⁶ reported mean ADC value of metastatic lymph nodes(0.786×10^{-3} mm²/s) significantly lower than that of benign lymph nodes(1.24×10^{-3} mm²/s). Zhong J et al²⁷ also reported mean ADC value of metastatic lymph nodes(0.849×10^{-3} mm²/s) significantly lower than that of benign lymph nodes(1.443×10^{-3} mm²/s). Parihar P and Goel V²⁸ found mean ADC value of metastatic lymph nodes (0.82×10^{-3} mm²/s) significantly lower than that of benign lymph nodes (1.21×10^{-3} mm²/s). Perrone A et al³⁵ reported mean ADC value of metastatic lymph nodes (0.85×10^{-3} m²/s) significantly lower than that of benign lymph nodes (1.448×10^{-3} mm²/s)

In the present study, diagnostic performance was evaluated by drawing ROC curve which revealed an ADC cut off value of 0.800×10^{-3} mm²/s to differentiate between benign and malignant cervical lymph nodes with sensitivity and specificity of 91.2% and 96.6% respectively. PPV, NPV of present study was 93.0% and 95.7 % respectively at 95% confidence intervals. The diagnostic accuracy of test was 94.85%. The result revealed p values of less than 0.001 which was statistically significant. The findings are in agreement with various previous studies. Parihar P and Goel V²⁸ reported a sensitivity of 97%, specificity of 91.1% at ADC threshold value of 1.10×10^{-3} mm²/s and they included only the largest abnormal node in each patient using b value of 500 and 1000 s/mm². Perrone A et al³² revealed a sensitivity of 100%, specificity of 92.9 % at ADC cut off value of 1.03×10^{-3} mm²/s by evaluating enlarged cervical lymph nodes at b value of 500 and 1000 s/mm².



Fifty five years old male with a known history of laryngeal carcinoma a) DWIs b 1000 and b) ADC map showing hyperintense right sided deep cervical LNs in diffusion images corresponding to low signal in ADC map with an ADC value $0.708 \times 10^{-3} \text{ mm}^2/\text{s}$; the possibility of metastatic nodal deposits is considered which was proven by biopsy.



Sixty years old male known case of squamous cell carcinoma of the base of tongue a) DWIs b 1000 and b) ADC maps showing multiple enlarged left deep cervical lymph nodes with hyperintense signal in diffusion WIs and corresponding intermediate to low signal in ADC map; with an ADC value varying from 0.454×10^{-3} to $0.552 \times 10^{-3} \text{ mm}^2/\text{s}$; the possibility of metastatic nodal deposits is considered. The biopsy was positive for metastatic nodal deposits.

The present study revealed 9 false negative lymph nodes out of the 103 histology/cytology proven metastatic nodes, most likely due to micro necrotic focus in a node or missed foci of metastasis during ROI placement in the nodes and 7 false positive out of 208 histology/cytology proven non metastatic nodes which could be due to partial volume effect. Wang J et al¹⁴ did a study which showed similar results. Our study has few limitations. Due to heterogeneity of head and neck tissues, strongly changing geometric shape, and presence of thick bony structures, images can have a very low signal-to-noise ratio and strong susceptibility artifacts from many air-tissue boundaries, as well as from metallic surgical implants and dental fillings. Motion artifacts can occur due to jaw movements, swallowing, speaking, coughing, and breathing. Manually drawn ROI is also difficult to interpret, and may not always be accurate as it may miss a micro metastatic focus in lymph node or may include areas of micro necrotic foci both leading to false negative results with higher ADC values.

V. Conclusion:

Most of patients in our study presented with complaint of dysphagia and non healing ulcer in mouth with/without trismus with pain or bleeding from ulcer. About 84% patients had past history of chronic smoking out of which 62% were chronic alcoholic. Among 6 levels of cervical lymph nodes assessed, upper jugular nodes (level II) were the commonest nodes in total cervical lymph nodes (43.1%) as well as metastatic lymph nodes (44.7%). Out of 311 cervical lymph nodes assessed, 103 nodes showed metastasis (33.1%) and the rest 208 cervical lymph nodes were negative for metastasis (66.9%). Cervical lymph nodes were characterized into benign and malignant using DWI MRI and ADC value calculation with histopathology /cytology reference study. We observed the mean ADC value of $0.594 \times 10^{-3} \text{ mm}^2/\text{s} \pm 0.197$ in metastatic lymph nodes and $1.04 \times 10^{-3} \text{ mm}^2/\text{s} \pm 0.710$ in non-metastatic lymph nodes with p value less than 0.001 which was statistically significant. DWI and quantitative analysis of ADC values revealed that mean ADC value of metastatic nodes was significantly lower than that of the non-metastatic nodes. Our study concluded that diffusion weighted MR imaging can be considered a fundamental supporting method in the diagnosis of benign and malignant lymph nodes and can be recognized as a predictor of treatment plan of the patients of head and neck malignancies.

References:

- [1]. Parkin DM, Bray F, Ferlay J, Pisani P. Global cancer statistics, 2002. CA: a cancer journal for clinicians. 2005 Mar; 55(2):74-108.
- [2]. Pande P, Soni S, Kaur J, Agarwal S, Mathur M, Shukla NK et al. Prognostic factors in betel and tobacco related oral cancer. Oral oncology. 2002 Jul 1; 38(5):491-99.
- [3]. Argiris A, Haraf DJ, Kies MS, Vokes EE. Intensive concurrent chemo radiotherapy for head and neck cancer with 5-fluorouracil- and hydroxyurea-based regimens: reversing a pattern of failure. The Oncologist. 2003 Aug 1; 8(4):350-60.
- [4]. Funk GF, Karnell LH, Robinson RA, Zhen WK, Trask DK, Hoffman HT. Presentation, treatment, and outcome of oral cavity cancer: a National Cancer Data Base report. Head & neck. 2002 Feb; 24(2):165-80.
- [5]. Syrjänen S. Human papillomavirus infections and oral tumors. Medical microbiology and immunology. 2003 Aug 1; 192(3):123-28.

- [6]. Scully C, Field JK, Tanzawa H. Genetic aberrations in oral or head and neck squamous cell carcinoma (SCCHN): 1. Carcinogen metabolism, DNA repair and cell cycle control. *Oral oncology*. 2000 May 1; 36(3):256-63.
- [7]. McGurk M, Chan C, Jones J, O'regan E, Sherriff M. Delay in diagnosis and its effect on outcome in head and neck cancer. *British Journal of Oral and Maxillofacial Surgery*. 2005 Aug 1; 43(4):281-84.
- [8]. Rouvière H. *Lymphatic System of the Head and Neck*. Edwards Brothers. Ann Arbor (MI, USA). 1938:5-51.
- [9]. Shah JP, Strong E, Spiro RH, Vikram B. Surgical grand rounds: neck dissection: current status and future possibilities. *Clin Bull*. 1981; 11:25–33.
- [10]. Som PM, Curtin HD, Mancuso AA. An imaging-based classification for the cervical nodes designed as an adjunct to recent clinically based nodal classifications. *Archives of Otolaryngology–Head & Neck Surgery*. 1999 Apr 1; 125(4):388-96.
- [11]. Jakobsen J, Hansen O, Jørgensen KE, Bastholt L. Lymph node metastases from laryngeal and pharyngeal carcinomas: calculation of burden of metastasis and its impact on prognosis. *Acta Oncologica*. 1998 Jan 1; 37(5):489-93.
- [12]. White ML, Zhang Y, Robinson RA. Evaluating tumors and tumorlike lesions of the nasal cavity, the paranasal sinuses, and the adjacent skull base with diffusion-weighted MRI. *Journal of computer assisted tomography*. 2006 May 1;30(3):490-5.
- [13]. Chong VF, Fan YF, Khoo JB. MRI features of cervical nodal necrosis in metastatic disease. *Clinical radiology*. 1996 Feb 1;51(2):103-9.
- [14]. Wang J, Takashima S, Takayama F, Kawakami S, Saito A, Matsushita T et al. Head and neck lesions: characterization with diffusion-weighted echo-planar MR imaging. *Radiology*. 2001 Sep;220(3):621-30.
- [15]. Razek AA, Soliman NY, Elkhamary S, Alsharaway MK, Tawfik A. Role of diffusion-weighted MR imaging in cervical lymphadenopathy. *European radiology*. 2006 Jul 1;16(7):1468-77.
- [16]. Vandecaveye V, De Keyzer F, Vander Poorten V, Dirix P, Verbeken E, Nuyts S et al. Head and neck squamous cell carcinoma: value of diffusion-weighted MR imaging for nodal staging. *Radiology*. 2009 Apr;251(1):134-46.
- [17]. De Bondt RB, Nelemans PJ, Hofman PA, Casselman JW, Kremer B, van Engelshoven JM et al. Detection of lymph node metastases in head and neck cancer: a meta-analysis comparing US, USgFNAC, CT and MR imaging. *European journal of radiology*. 2007 Nov 1;64(2):266-72.
- [18]. Nabavizadeh SA, Chawla S, Agarwal M, Mohan S. On the Horizon: Advanced Imaging Techniques to Improve Noninvasive Assessment of Cervical Lymph Nodes. In *Seminars in Ultrasound, CT and MRI 2017* Oct 1;38(5):542-56.
- [19]. De Bree R, Castelijns JA, Hoekstra OS, Leemans CR. Advances in imaging in the work-up of head and neck cancer patients. *Oral oncology*. 2009 Nov 1; 45(11):930-35.
- [20]. Liao LJ, Lo WC, Hsu WL, Wang CT, Lai MS. Detection of cervical lymph node metastasis in head and neck cancer patients with clinically N0 neck—a meta-analysis comparing different imaging modalities. *BMC cancer*. 2012 Dec 1; 12(1):1-7.
- [21]. Anand N, Chaudhary N, Mittal MK, Prasad R. Comparison of the efficacy of clinical examination, ultrasound neck and computed tomography in detection and staging of cervical lymph node metastasis in head and neck cancers. *Indian Journal of Otolaryngology and Head & Neck Surgery*. 2007 Mar 1; 59(1):19-23.
- [22]. Sabri YY, Nossair EZ, Assal HH, Wahba HS. Role of diffusion weighted MR-imaging in the evaluation of malignant mediastinal lesions. *Egyptian Journal of Radiology and Nuclear Medicine*. 2020 Dec 1; 51(1):32.1-16.
- [23]. Padhani AR, Liu G, Mu-Koh D, Chenevert TL, Thoeny HC, Takahara T et al. Diffusion-weighted magnetic resonance imaging as a cancer biomarker: consensus and recommendations. *Neoplasia*. 2009 Feb 1; 11(2):102-25.
- [24]. Mahajan A, Deshpande SS, Thakur MH. Diffusion magnetic resonance imaging: a molecular imaging tool caught between hope, hype and real world of “personalized oncology”. *World journal of radiology*. 2017 Jun 28; 9(6):253-68.
- [25]. De bondt RBJ, Hoerberigs MC, Nelemans PJ, Deserno WM, Kootstra CP, Kremer B et al. Diagnostic accuracy and additional value of diffusion-weighted imaging for discrimination of malignant cervical lymph nodes in head and neck squamous cell carcinoma. *Neuroradiology*. 2009 Mar; 51(3):183-92.
- [26]. Holzapfel K, DuetschS, Fauser C, Eiber M, RummenyEJ, Gaa J. value of diffusion weighted MR imaging in differentiation between benign and malignant cervical lymph nodes. *European journal of radiology*. 2009; 72(3):381-87.
- [27]. Zhong J, Lu Z, Xu L, Dong L, Qiao H, Hua R et al. The diagnostic value of cervical lymph node metastasis in head and neck squamous carcinoma by using diffusion-weighted magnetic resonance imaging and computed tomography perfusion. *BioMed research international*. 2014 Jan 1; 260859; 1-7.
- [28]. Parihar P, Goel V. Differentiating Benign and Malignant Metastatic Cervical Lymph Nodes by Diffusion Weighted MRI Sequence. *International Journal of Anatomy Radiology and Surgery*. 2015; 4(4):47-50.
- [29]. Ali TF, El Hariri MA. Combined diffusion-weighted MRI and MR spectroscopy: Feasibility to improve the MRI capability in differentiation between benign and malignant neck lymphadenopathy. *The Egyptian Journal of Radiology and Nuclear Medicine*. 2017 Mar; 48(1):97-106.
- [30]. Dhull AK, Atri R, Dhankhar R, Chauhan AK, Kaushal V. Major risk factors in head and neck Cancer: a retrospective analysis of 12-year experiences. *World journal of oncology*. 2018 Jun; 9(3):80-84.
- [31]. Jin GQ, Yang J, Liu LD, Su DK, Wang DP, Zhao SF et al. The diagnostic value of 1.5-T diffusion-weighted MR imaging in detecting 5 to 10 mm metastatic cervical lymph nodes of nasopharyngeal carcinoma. *Medicine*. 2016 Aug; 95(32): e4286:1-8.
- [32]. Perrone A, Guerrisi P, Izzo L, D'Angeli I, Sassi S, Mele LL et al. Diffusion-weighted MRI in cervical lymph nodes: differentiation between benign and malignant lesions. *European journal of radiology*. 2011 Feb 1; 77(2):281-86.

Dr. Aditi Kundan, et. al. “Role of Diffusion Weighted MRI of Cervical Lymph Nodes in Head and Neck Malignancies.” *IOSR Journal of Dental and Medical Sciences (IOSR-JDMS)*, 20(02), 2021, pp. 45-54.