

## Acute Coronary Syndrome - NSTEMI following Paclitaxel administration in patient with Oral Squamous Cell Carcinoma : Case report and Review

Dr Deepali Lodha\*, Dr Roop Gill\*, Dr Vivek Vaswani\*\*,  
Dr Ashish Sharma\*\*\*, Dr J. D. Lakhani\*\*\*\*

Junior Residents\*, Assistant Professor\*\*, Senior Resident(Cardiology)\*\*\*, Professor and Head\*\*\*\*  
Department of General Medicine, SBKS MIRC, Pipariya, Vadodara, Gujarat-391760

### Abstract

Paclitaxel is a drug with antineoplastic activity which is used in treatment of various cancers like breast, ovarian, lung and other solid tumors including head and neck cancers. The major side effect associated with paclitaxel are bone marrow suppression, alopecia, polyneuropathy and cardiac toxicities. We here, report a case of middle aged male patient diagnosed with oral cancer who developed Acute Coronary Syndrome after starting Paclitaxel infusion. Acute MI can occur due to Paclitaxel administration which is rare but life threatening adverse drug event.

### Keywords

Paclitaxel, NSTEMI, Cardiotoxicity

Date of Submission: 20-03-2021

Date of Acceptance: 04-04-2021

### I. Introduction

Paclitaxel is a natural product with antineoplastic activity.<sup>1</sup> It is widely used in treatment of breast, ovarian, lung cancers and other solid tumors including head and neck cancers.<sup>2</sup>

Squamous cell carcinoma(SCC) of oral cavity is one the most common malignancies world wide. India and other developing countries have the highest incidence of SCC of oral cavity.<sup>3</sup> Surgery remains the gold standard treatment, but for unresectable disease, curative chemoradiotherapy or palliative radiotherapy has been offered.<sup>5</sup> Paclitaxel has been used in chemotherapy as an induction therapy or secondary treatment for metastatic SCC of head and neck.<sup>6</sup>

The major side effects of this drug are bone marrow suppression, alopecia, polyneuropathy and cardiac toxicities.<sup>7</sup> The cardiac toxicities include asymptomatic bradycardia, atrioventricular conduction blocks, atrial arrhythmias, left bundle branch block, ventricular tachycardia, congestive cardiac failure and fatal myocardial infarction.<sup>8</sup>

Cardiotoxicity is one of the most serious side effects of chemotherapy, resulting in morbidity and mortality. Cardiac dysfunction due to chemotherapy can be acute, subacute or chronic side effects. It becomes pertinent to learn and discuss about these serious adverse events related to paclitaxel.<sup>9</sup> We hereby aim to report this case of middle aged male patient diagnosed with oral cancer who developed acute coronary syndrome within 60 to 90 minutes after starting paclitaxel infusion.

### II. Case Report

61 year old male patient who was diagnosed with Squamous Cell Carcinoma of left buccal cavity with spread to Cervical level IA node was scheduled for Induction chemotherapy with Taxane derivative – Paclitaxel injection. Patient was admitted for his first cycle of chemotherapy . On admission he had no complaints of chest pain, palpitations, shortness of breath , and his vitals were within normal limits and all routine investigations (CBC, RFT, LFT, Urine r/m), ECG, Chest X-ray were done and found normal . Initially patient was pre-hydrated with intravenous (IV) Normal Saline(0.9%) 500ml followed by Intravenous Paclitaxel infusion. Patient started complaining of Chest pain which was retrosternal, stabbing type, associated with perspiration, radiating to back after 400 ml of IV Paclitaxel was given. Paclitaxel injection was immediately stopped. ECG was done which was s/o ST depressions in V1-V4 ( Fig 1); and posterior leads (V6,7,8) did not show any ST elevations, cardiac troponin I was Positive and 2D Echo done was normal and rest of the routine blood parameters were within normal limits. Diagnosis of acute coronary syndrome – NSTEMI (Non ST Elevation Myocardial Infarction) was made; loading dose of Inj Heparin (5000 IU, IV), dual antiplatelets (Aspirin, Clopidogrel), statin was given. Chest pain subsided within 30 minutes. Serial ECG monitoring was

done, and ECG changes reverted to normal sinus rhythm with no ST-T changes in about 8 hours ( Fig 2). Next day morning, similar ECG changed developed again with ST depressions in leads V1-V4 but patient did not have any symptoms ( Fig 3). Suspecting Vasospastic (Prinzmetal) angina , Tab Diltiazem (30mg ) was started thrice a day and CAG was planned. Patient underwent CAG on 3<sup>rd</sup> day of admission which revealed triple vessel disease (TVD)-stenosis in Left Main Coronary Artery, Left Ascending Artery, Circumflex, Right Coronary Artery ( Fig 4) and CABG was advised as next line of management

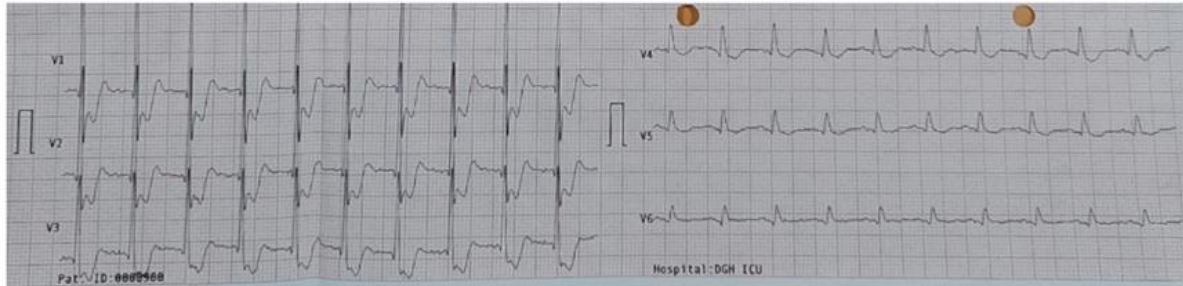


Fig 1

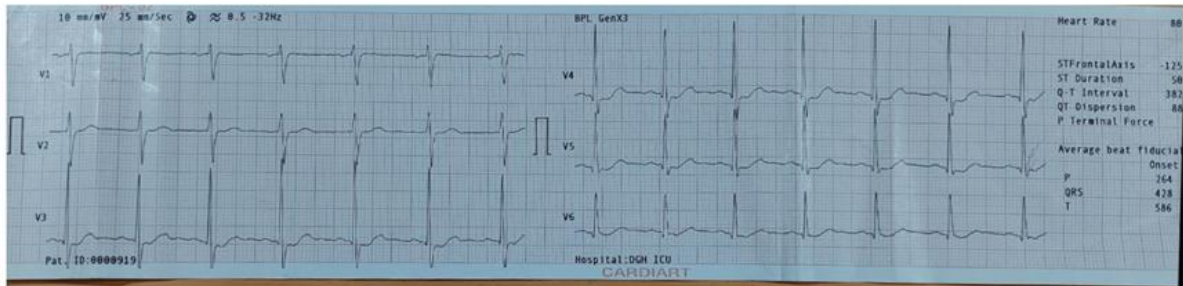


Fig 2

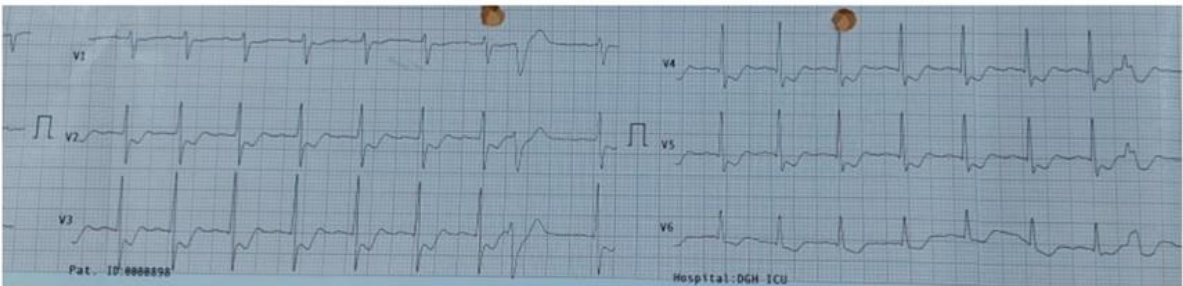


Fig 3

Fig 1 : ECG s/o ST depressions in V1- V4; Fig 2 : ECG s/o ( Reverted back) Normal Sinus Rhythm; Fig 3 : ST depressions in V1-V4

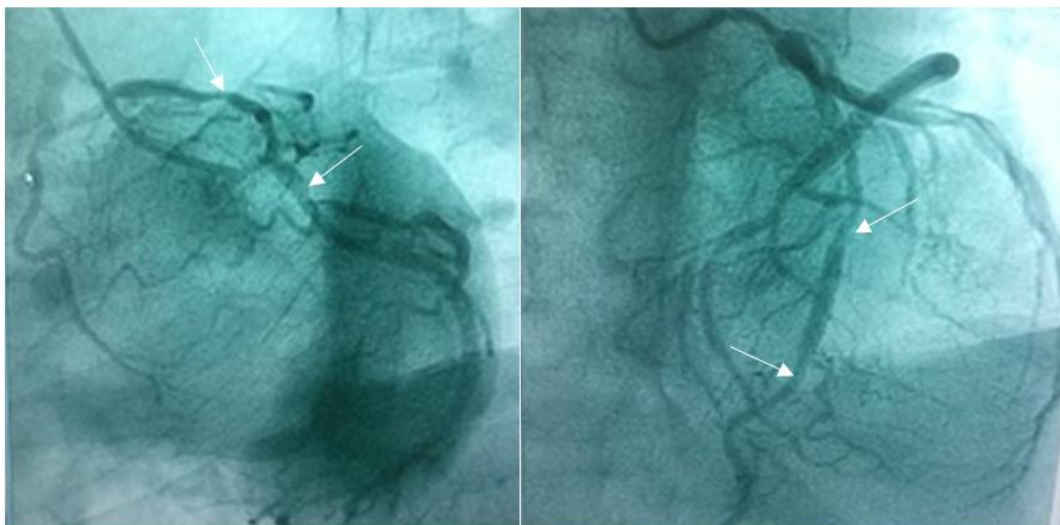


Fig 4 : Coronary Angiography showing TVD - stenosis in Left Main Coronary Artery, Left Ascending Artery, Circumflex, Right Coronary Artery.

### III. Discussion

Paclitaxel, a natural product with antineoplastic activity originally isolated from the bark of the Pacific yew tree, *Taxus brevifolia*, in 1971, therefore named as Taxol. It is the prototype of a novel class of antimicrotubule agent that induces tubulin polymerization. It has been in clinical use since 1993 as a chemotherapeutic agent for breast, ovarian, endometrial, lung and other solid tumors including head and neck cancers. Paclitaxel has been used in chemotherapy as an induction therapy or secondary treatment for metastatic SCC of head and neck.<sup>6</sup>

Cardiotoxicity is one of the most serious adverse effects of chemotherapy. Acute or subacute cardiotoxic adverse effects which includes reversible arrhythmias, abnormalities in ventricular repolarization, prolongation of QT interval, acute coronary syndrome, pericardial reaction, and alteration in myocardial function, can develop anytime from initiation of chemotherapeutic agent upto 4 weeks.<sup>10</sup> Chronic cardiotoxicity occurs 4 weeks after treatment. It includes reversible or irreversible cardiac (systolic or diastolic) dysfunction which can lead to heart failure and even death.<sup>11</sup>

Although Paclitaxel is very promising and effective chemotherapeutic drug which has been used since more than a decade but many adverse drug reactions which have been reported in various studies out of which few are lethal. Among these, Bone marrow suppression, Alopecia and Peripheral neuropathy are more common where as Cardiotoxicity is seen in 1-10%.<sup>12</sup> The adverse cardiac events include asymptomatic bradycardia seen in 3% of patients, arrhythmias <1% including AV conduction block, left bundle branch block, ventricular premature contractions and ventricular tachycardia in <1% of patients. Myocardial infarction (MI) which is rarest and a life threatening adverse event that has been reported in patients.<sup>13</sup>

Paclitaxel induced cardiotoxicity occurs either indirectly following a massive histamine release with subsequent conduction disturbances and arrhythmia, or through direct myocardial damage via an effect on subcellular organelles, which may induce congestive heart failure.<sup>14</sup> The exact mechanism that leads to MI while patient is receiving paclitaxel has not been clearly described in the literature.<sup>15</sup> But various pathophysiologies has been postulated out of which few includes coronary artery vasospasm- histamine mediated or vasospasm due to increased intracellular calcium concentration or allergic Myocardial infarction induced by Paclitaxel.<sup>16</sup>

A case report of 63 year old woman with ovarian cancer who developed acute MI one day after Paclitaxel administration has been reported by Park.et.al in 2009 in the Korean society of Cardiology. The authors in this case postulated that paclitaxel can itself cause coronary artery thrombosis.<sup>17</sup> In our study patient developed Acute MI (NSTEMI) after few hours of Paclitaxel infusion. Usually it has been observed that cardiotoxicities manifested during the infusion of the drug are asymptomatic and reversible.<sup>18</sup>

The study published in 2003 "Cardiotoxicity of Paclitaxel in African Americans" the authors observed 26% out of 90 patients developed sinus tachycardia, which was the most common cardiotoxic effect and 6% developed Acute MI, other cardiac events they found included non specific T wave changes, prolonged QT interval(4%), right and left bundle branch block and in 1% atrial fibrillation was present. Two patients had acute onset chest pain during infusion of Paclitaxel.

As observed in our patient there were no known risk factors and comorbidities present but the coronary angiography report was suggestive of triple vessel disease from this finding we can draw inference that this patient might have had coronary vasospasm superimposed on underlying obstructive coronary vessel disease which unveiled the coronary artery disease in the form of Non ST segment elevation MI.

Therefore clinicians must consider and recognize patients with higher cardiovascular disease risk factors before administration of such chemotherapeutic drugs. The needed pre-administration investigations like baseline ECG, Lipid profile, 2D Echo along with other routine investigations must be done in patients with no comorbidities and non identifiable risk factors. Thus proper cardiac monitoring must be exercised during and after the infusion of this drug. As there are few studies available in the literature regarding cardiotoxicities of paclitaxel, it is very important to report such rare isolated cases to provide insight to the other treating physicians.

#### IV. Conclusion

Acute MI secondary to Paclitaxel administration is a rare but life threatening adverse drug event. So extreme caution with proper observation is advised during the infusion even if the patient has no cardiac risk factors.

#### References

- [1]. Laher S, Karp SJ. Acute myocardial infarction following paclitaxel administration for ovarian carcinoma. *Clinical Oncology*. 1997 Jan 1;9(2):124-6.
- [2]. Honda Y, Grube E, de la Fuente LM, Yock PG, Stertz SH, Fitzgerald PJ. Novel drug-delivery stent: intravascular ultrasound observations from the first human experience with the QP2-eluting polymer stent system. *Circulation*. 2001 Jul 24;104(4):380-3.
- [3]. Honda Y, Grube E, de la Fuente LM, Yock PG, Stertz SH, Fitzgerald PJ. Novel drug-delivery stent: intravascular ultrasound observations from the first human experience with the QP2-eluting polymer stent system. *Circulation*. 2001 Jul 24;104(4):380-3.
- [4]. Pulte D, Brenner H. Changes in survival in head and neck cancers in the late 20th and early 21st century: a period analysis. *The oncologist*. 2010 Sep;15(9):994.
- [5]. Alzahrani R, Obaid A, Al-Hakami H, Alshehri A, Al-Assaf H, Adas R, Alduhaibi E, Alsafadi N, Alghamdi S, Alghamdi M. Locally Advanced Oral Cavity Cancers: What Is The Optimal Care?. *Cancer Control*. 2020 Apr 22;27(1):1073274820920727.
- [6]. Pignon JP, Le Maitre A, Maillard E, Bourhis J, Mach-Nc Collaborative Group. Meta-analysis of chemotherapy in head and neck cancer (MACH-NC): an update on 93 randomised trials and 17,346 patients. *Radiotherapy and oncology*. 2009 Jul 1;92(1):4-14.
- [7]. Rowinsky EK, Gilbert MR, McGuire WP, Noe DA, Grochow LB, Forastiere AA, Ettinger DS, Lubejko BG, Clark B, Sartorius SE. Sequences of taxol and cisplatin: a phase I and pharmacologic study. *Journal of clinical oncology*. 1991 Sep;9(9):1692-703.
- [8]. Arbuck SG, Strauss H, Rowinsky E, Christian M, Suffness M, Adams J, Oakes M, McGuire W, Reed E, Gibbs H. A reassessment of cardiac toxicity associated with Taxol. *Journal of the National Cancer Institute. Monographs*. 1993 Jan 1(15):117-30.
- [9]. Khakoo AY, Liu PP, Force T, Lopez-Berestein G, Jones LW, Schneider J, Hill J. Cardiotoxicity due to cancer therapy. *Texas Heart Institute Journal*. 2011;38(3):253.
- [10]. Dolci A, Dominici R, Cardinale D, Sandri MT, Panteghini M. Biochemical markers for prediction of chemotherapy-induced cardiotoxicity: systematic review of the literature and recommendations for use. *American Journal of Clinical Pathology*. 2008 Nov 1;130(5):688-95.
- [11]. Herrmann J, Yang EH, Iliescu CA, Cilingsiroglu M, Charitakis K, Hakeem A, Toutouzas K, Leeser MA, Grines CL, Marmagkiolis K. Vascular toxicities of cancer therapies: the old and the new—an evolving avenue. *Circulation*. 2016 Mar 29;133(13):1272-89.
- [12]. Sibaud V, Leboeuf NR, Roche H, Belum VR, Gladieff L, Deslandres M, Montastruc M, Eche A, Vigarios E, Dalenc F, Lacouture ME. Dermatological adverse events with taxane chemotherapy. *European Journal of Dermatology*. 2016 Sep;26(5):427-43.
- [13]. Page RL, O'Bryant CL, Cheng D, Dow TJ, Ky B, Stein CM, Spencer AP, Trupp RJ, Lindenfeld J. Drugs that may cause or exacerbate heart failure: a scientific statement from the American Heart Association. *Circulation*. 2016 Aug 9;134(6):e32-69.
- [14]. Schimmel KJ, Richel DJ, van den Brink RB, Guchelaar HJ. Cardiotoxicity of cytotoxic drugs. *Cancer treatment reviews*. 2004 Apr 1;30(2):181-91.
- [15]. Oneglia C, Kounis NG, Beretta G, Ghizzoni G, Gualeni A, Berti M. Kounis syndrome in a patient with ovarian cancer and allergy to iodinated contrast media: Report of a case: Vasospastic angina induced by chemotherapy. *International journal of cardiology*. 2011 Jun 2;149(2):e62-5.
- [16]. Esber C, Breathett K, Sachak T, Moore S, Lilly SM. Acute myocardial infarction in patient with triple negative breast cancer after paclitaxel infusion: A Case Report. *Cardiology research*. 2014 Aug;5(3-4):108.
- [17]. Park SH, Byon JS, Lee SW, Lee SJ, Jin DK, Shin WY. Coronary artery thrombosis associated with Paclitaxel in advanced ovarian cancer. *Korean circulation journal*. 2009 Mar;39(3):124.
- [18]. Rowinsky EK, McGuire WP, Guarnieri T, Fisherman JS, Christian MC, Donehower RC. Cardiac disturbances during the administration of taxol. *Journal of Clinical Oncology*. 1991 Sep;9(9):1704-12.
- [19]. Gibson MK, Li Y, Murphy B, Hussain MH, DeConti RC, Ensley J, Forastiere AA. Randomized phase III evaluation of cisplatin plus fluorouracil versus cisplatin plus paclitaxel in advanced head and neck cancer (E1395): an intergroup trial of the Eastern Cooperative Oncology Group. *Journal of Clinical Oncology*. 2005 May 20;23(15):3562-7.

Dr Deepali Lodha, et. al. "Acute Coronary Syndrome - NSTEMI following Paclitaxel administration in patient with Oral Squamous Cell Carcinoma : Case report and Review." *IOSR Journal of Dental and Medical Sciences (IOSR-JDMS)*, 20(04), 2021, pp. 20-23.