

Steroid Dependent Macular Edema in A Steroid Responder: A Case Report

Vira Jayesh Yogesh¹, Prabhushanker Mahalingam¹, Geetha G¹, Anusha Venkataraman¹

¹(Department of Vitreoretina, Sankara Eye Hospital, Coimbatore, India)

Abstract:

Background: Recalcitrant macular edema is a chronic complication of retinal vascular occlusive diseases. Various topical and injectable medications have been developed to control and treat the macular edema, including AntiVegf agents and steroids. While the intravitreal injection has the benefit of delivering the drug close into the vitreous cavity, it carries with it the risk of endophthalmitis. Topical medications are safer and can easily be withdrawn in case of side effects. In this case report we describe our experience in managing a patient with chronic macular edema secondary to retinal branch vein occlusion. The patient was treated with topical Difluprednate 0.05% eye drops with good functional and anatomical response. However, rise in intraocular pressure necessitated withdrawal of this drug and a switch back to intravitreal AntiVegf.

Conclusion: Topical Difluprednate 0.05% eye drops are effective in treatment of macular edema. But in steroid responders intra-vitreous injection of Anti VEGF has to be used as rescue therapy.

Key Word: BRVO, CME, Difluprednate, Anti VEGF, Bevacizumab, Steroid.

Date of Submission: 30-05-2021

Date of Acceptance: 13-06-2021

I. Introduction

Retinal vein occlusions (RVO) are the second commonest causes of retinal vascular occlusions and significantly contribute to ocular morbidity in terms of decrease in visual acuity, visual quality and long term complications. Macular edema is the commonest complication of RVO.(1) A series of clinical trials have been conducted to study the natural history, assess the efficacy of various treatment modalities and to formulate clinical guidelines in the management of this condition.(2) Steroid formulations either as topical eye drops, peribulbar injections or intravitreal injections, intravitreal antiVEGF agents, laser photocoagulation and surgery in various permutations and combinations continue to be used in the clinical setting. Owing to the diverse pathophysiology of this condition and its multifactorial causation and financial burden, many a times a tailor made approach is required in the management of vision threatening complications of RVOs, especially recalcitrant macular edema.

II. Case Report

A 45 year old female patient presented to the retina OPD with complains of diminution of vision in left eye since 10 days. The loss of vision was gradual, painless, not associated with flashes or floaters, with no diurnal variation and associated with a history of ocular trauma. The patient gave a history of retinal vascular occlusions in both eyes with vitreous haemorrhage in right eye and macular edema in left eye. The patient had undergone 3 port Pars Plana Vitrectomy in right eye 2 years ago and sectoral scatter laser followed by multiple intravitreal injections of Anti-VEGF Bevacizumab in left eye. The last intravitreal injection was 3 months ago.

At presentation her visual acuity in the right eye was Snellen's 6/6, N6 and left eye was 6/24. Intraocular pressure was 14mmHg and 15 mmHg in the right and left eye respectively by Goldmann aplanation tonometry (GAT). Slit lamp biomicroscopic examination of the anterior segment was essentially normal in right eye and in the left eye had cataract grade Nuclear sclerosis II. On Posterior segment examination, in right eye optic disc and macula were normal with sclerosed vessels in the superotemporal quadrant and laser marks confirming with the appearance of a vitrectomised eye. In the left, optic disc was normal with presence of retinal thickening and hard exudates in the macula. Sclerosed vessels were seen in the superotemporal quadrant with old laser marks.

Optical coherence tomography (OCT) of the posterior pole confirmed the diagnosis of cystoid macular edema in left eye. Central macular thickness was 467 microns (Figure 1). The patient was advised to instill eye drop Difluprednate 0.05% two times per day, eye drop Timolol Maleate 0.5% two times per day in the left eye and review after 1 week. The patient was advised to review after one week, when visual acuity improved to 6/12 and patient was asked to continue the same treatment and review after one month.

At the one month review, patient maintained visual acuity of 6/12. There were no fresh complaints. However, intraocular pressure in left eye was 30mmHg by GAT. Thus a diagnosis of steroid induced rise in intraocular pressure was made and the patient was asked to discontinue Difluprednate 0.05% eye drops and was asked to instill Nepafenac 0.1% eye drops instead and review after 1 week. OCT showed presence of intraretinal cystoids spaces and CMT was 460 microns (Figure 2).

At the next review, visual acuity in left eye had decreased to 6/36, IOP had reduced to 18mmHg. OCT scan showed increase in CME with CMT of 727microns (Figure 3). The patient was advised for phacoemulsification with intraocular lens implantation with intravitreal injection of Bevacizumab in left eye, which she underwent the following week.

One week after surgical intervention, visual acuity in left eye had improved to 6/18. There was some resolution of CME on OCT. CMT had reduced to 610microns. (Figure 4). Patient has been asked to review after 3 weeks to assess for repeat intravitreal injection of Bevacizumab.

Figure 1: OCT of Left Eye at presentation showing Cystoid macular edema

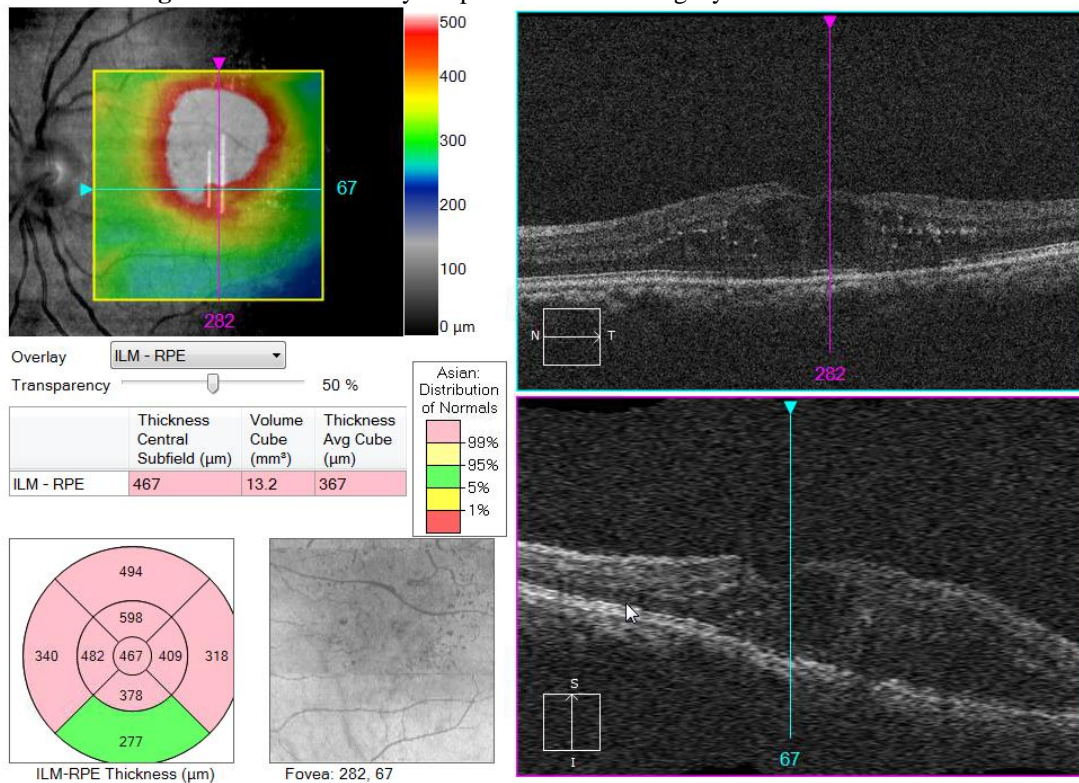


Figure 2: OCT of Left eye one month after topical Difluprednate 0.05% eye drops instillation.

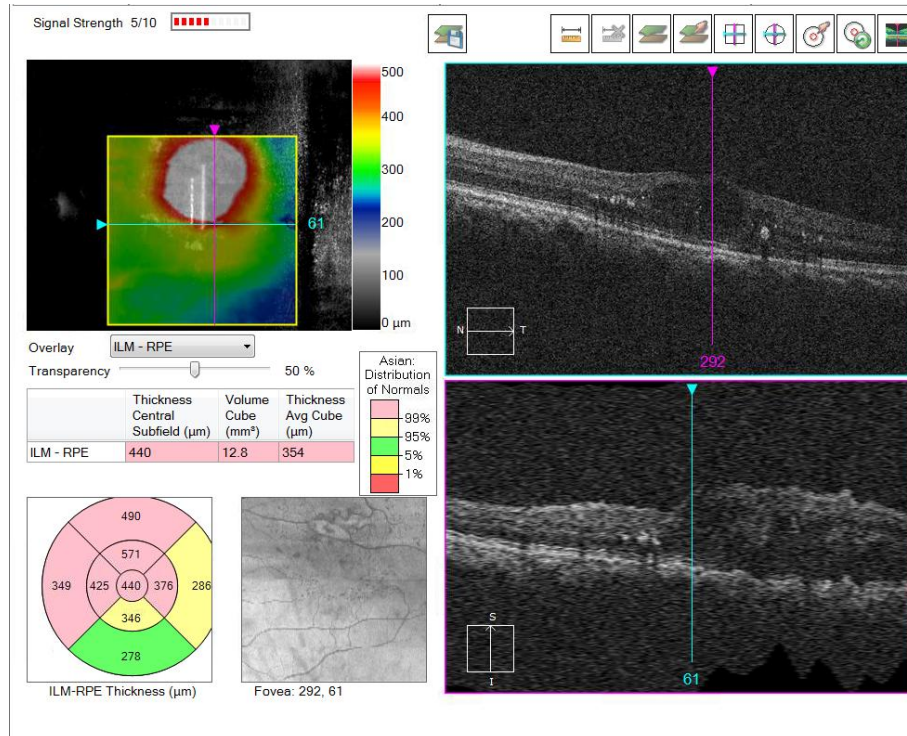


Figure 3: OCT of Left Eye one week after discontinuation of Difluprednate 0.05% eye drops. CMT: 727m

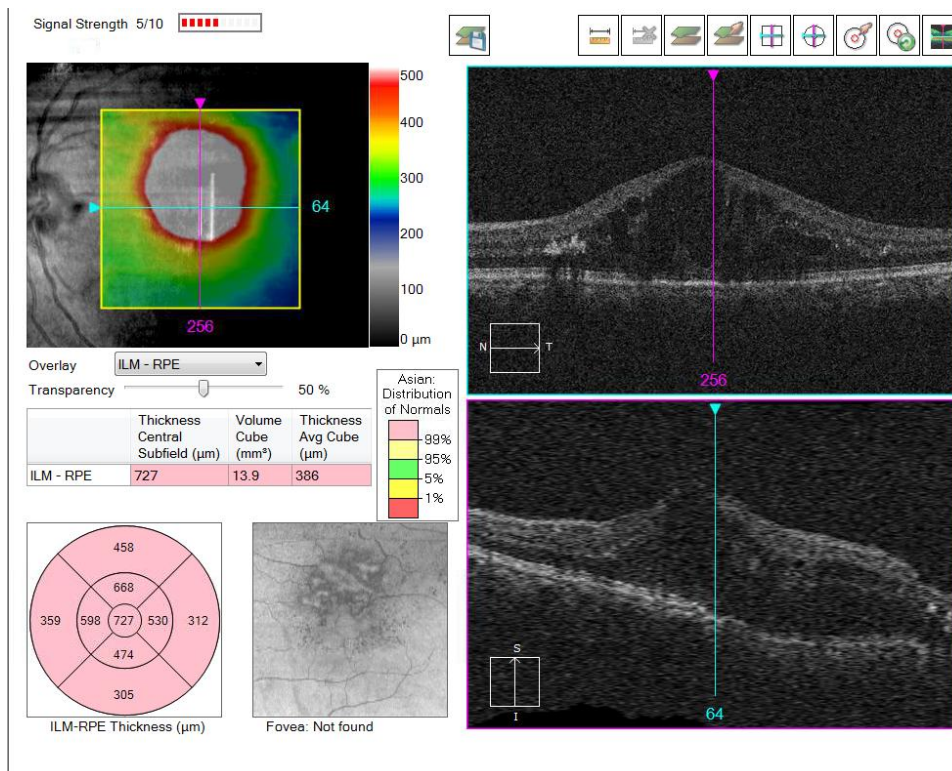
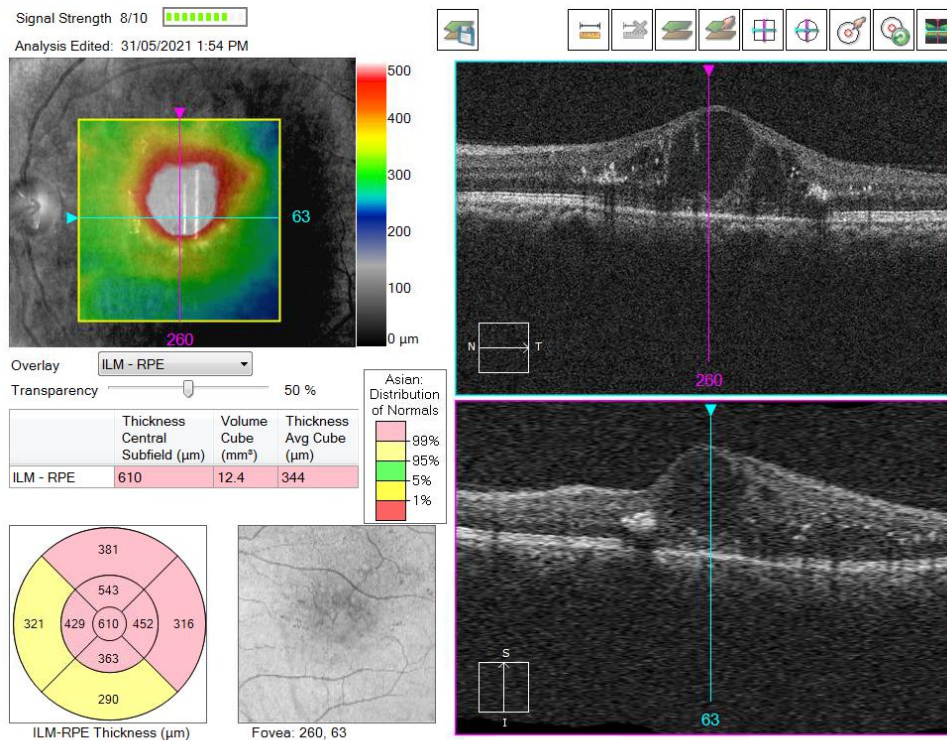


Figure 4: OCT of Left Eye one week after phacoemulsification with IOL implantation with Intravitreal injection of Bevacizumab.



III. Discussion

Use of Difluprednate 0.05% eye drops for controlling post operative inflammation has been well studied. The drug has been found to be efficacious and safe in management of anterior segment inflammation post cataract surgery as the more widely and routinely used Prednisolone acetate 1% eye drop.(3) Additionally, the drug has also been found to be effective in treatment of non-high risk Penetrating Keratoplasty graft rejections and early graft rejections. (4, 5) Authors have reported epitheliopathy and increase in intraocular pressure as significant side effects that require monitoring, but can be managed by withdrawal of the drug and/or addition of topical antiglaucoma medications. Similarly, retrospective case studies have shown the drug to be effective in management of posterior segment inflammations as well. In the study by Schallhorn et al (6) on seventy two eyes of 58 patients with cystoids macular edema, CME had resolved in 48% eyes and improved in 76% eyes by 30 days. Asahi M G et al (7) used a cocktail of difluprednate, NSAID and carbonic anhydrase inhibitor eye drops and found that there was improvement in visual acuity, leakage on fluorescein angiography and as well as OCT. In the twenty eyes with persistent diabetic macular edema evaluated by Kaur S et al(8) , two lines improvement in visual acuity and significant reduction in central retinal thickness was noted at the end of 3 months. However, 20% of study population had in increase in intraocular pressure. However, none of the patients that had to be weaned off diflucor had significant increase in CMT at follow-up visits.

IV. Conclusion

We report a unique case of steroid dependent macular edema in a steroid responder. In such cases, rescue therapy by intravitreal anti-VEGF injections become the mainstay of treatment.

References

- [1]. Jaulim A, Ahmed B, Khanam T, Chatziralli IP. Branch retinal vein occlusion: epidemiology, pathogenesis, risk factors, clinical features, diagnosis, and complications. An update of the literature. *Retina*. 2013 May;33(5):901-10. doi: 10.1097/IAE.0b013e3182870c15. PMID: 23609064.
- [2]. Li J, Paulus YM, Shuai Y, Fang W, Liu Q, Yuan S. New Developments in the Classification, Pathogenesis, Risk Factors, Natural History, and Treatment of Branch Retinal Vein Occlusion. *J Ophthalmol*. 2017;2017:4936924. doi: 10.1155/2017/4936924. Epub 2017 Mar 12. PMID: 28386476; PMCID: PMC5366235.
- [3]. KhalafAllah, M. T., Basiony, A., & Salama, A. (2019). Difluprednate versus Prednisolone Acetate after Cataract Surgery: a Systematic Review and Meta-Analysis. *BMJ open*, 9(11), e026752. <https://doi.org/10.1136/bmjopen-2018-026752>.
- [4]. Sorkin, N., Yang, Y., Mednick, Z., Einar-Lifshitz, A., Trinh, T., Santaella, G., Telli, A., Chan, C. C., Slomovic, A. R., & Rootman, D. S. (2020). Outcomes of difluprednate treatment for corneal graft rejection. *Canadian journal of ophthalmology. Journal canadien d'ophtalmologie*, 55(1), 82–86.
- [5]. Said OM, Saleh MGA, Omar AF, Abdou AA, Riad Mostafa AN. Topical Difluprednate for Early Corneal Graft Rejection After Penetrating Keratoplasty. *Clin Ophthalmol*. 2020 Oct 27;14:3495-3498. doi: 10.2147/OPTH.S267888. PMID: 33149542; PMCID: PMC7602884.

- [6]. Schallhorn, J. M., Niemeyer, K. M., Browne, E. N., Chhetri, P., & Acharya, N. R. (2018). Difluprednate for the Treatment of Uveitic Cystoid Macular Edema. *American journal of ophthalmology*, *191*, 14–22. <https://doi.org/10.1016/j.ajo.2018.03.027>
- [7]. Asahi, M. G., Bobarnac Dogaru, G. L., Onishi, S. M., & Gallemore, R. P. (2015). Strong topical steroid, NSAID, and carbonic anhydrase inhibitor cocktail for treatment of cystoid macular edema. *International medical case reports journal*, *8*, 305–312. <https://doi.org/10.2147/IMCRJ.S92794>
- [8]. Kaur, S., Yangzes, S., Singh, S., & Sachdev, N. (2016). Efficacy and safety of topical difluprednate in persistent diabetic macular edema. *International ophthalmology*, *36*(3), 335–340. <https://doi.org/10.1007/s10792-015-0121-3>

Vira Jayesh Yogesh, et. al. “Steroid Dependent Macular Edema in A Steroid Responder: A Case Report.” *IOSR Journal of Dental and Medical Sciences (IOSR-JDMS)*, 20(06), 2021, pp. 52-56.