

Central Retinal Artery Occlusion Following Acute Pancreatitis: A Case Report

Y. Hidan, S.Bahti, H.Jamaledine A. Mchachi, L. Benhmidoune, R. Rachid, M. EL Belhadji

Adult ophthalmology department , 20 Aout Hospital , Hassan II University Casablanca Morocco

Summary

We report the case of a 48-year-old patient hospitalized in the gastroenterology department for acute pancreatitis, she was referred to the ophthalmological emergency room with an acute painless loss of vision on the left eye. Visual acuity was limited to light perceptions on the left eye and 10/10 P2 on the right eye. The fundus examination showed ischemic edema and a cherry red macula. This aspect suggests an occlusion of the central retinal artery. Further angiography was performed which shows circulatory slowing. The diagnosis retained is an occlusion of the central retinal artery secondary to an thrombosis in a hypercoagulable area

Date of Submission: 08-07-2021

Date of Acceptance: 23-07-2021

I. Introduction

Acute pancreatitis (PA) is an inflammation of the pancreatic gland, its complications are numerous, it involves both the functional and the vital prognosis. Among these complications is disseminated intravascular coagulation. The occurrence of an occlusion of the central retinal artery in this area is a rare phenomenon. The case study is a 48-year-old patient who presented with left eye OACR following acute pancreatitis.

II. Observation

A 48-year-old female patient complained of an acute painless loss in visual acuity in her left eye after being hospitalized in the gastroenterology department for acute pancreatitis. Her history included arterial hypertension that was well controlled on monotherapy, and well-balanced dyslipidemia on statins.

The patient was admitted to hospital with typical abdominal pain, vomiting and mucocutaneous jaundice. The CRP was elevated to 30 (norms 0-0.9 mg/mL), the lipasemia was elevated to 971IU/L. , an abdominal CT scan allowed staging the pancreatitis in stage D according to the Balthazar classification A biological workup showed the onset of disseminated intravascular coagulation.

At the time of the emergency examination,, visual acuity in the left eye was limited to light perceptions and 10 / 10th P2 in the right eye. Slit lamp examination revealed a abolished direct photomotor reflex. Fundus examination showed ischemic-looking white retinal edema with a cherry-red macula (Fig.1). The patient benefited from an angiographic examination that showed no filling of the central retinal artery (Fig.2).OCT images demonstrated the increased reflectivity and thickness of the inner retina and a corresponding decrease of reflectivity in the outer layer of the retina(Fig.3) .the patient was put under medical treatment based on antiplatelet aggregates (acetylsalicylic acid 160mg), vasodilators and hypotonizers (oral acetazolamide).

The evolution was marked, 3 weeks later, by a resorption of the retinal edema and by an increase in visual acuity with close fingers counting.

An angiographic control was performed 6 weeks later and showed retinal neovascularization for which the patient underwent retinal panphotocoagulation .

III. Discussion

Acute occlusion of retinal artery following acute pancreatitis is a rare complication, the pathogenesis of which is always complex.

Emboli, atherosclerotic changes, vasculitis, vascular spasm, circulatory collapse, dissecting aneurysm, and hypertensive arterial necrosis represent multiple causes of OACR.

In our case, the patient had a normal blood pressure profile throughout her hospitalization and a thrombo-embolic origin was suggested following the occurrence of disseminated intravascular coagulation.

A similar case was described in the United States by Timoney in 2009 where the attack was particularly bilateral. [1]

Treatments described in the literature for RCAO include prescription of anticoagulants, anterior chamber puncture[4], vasodilators[3], carbonic anhydrase inhibitors[3], hyperbaric oxygen therapy[2], and fibrinolysis[2].

In our case, the patient presented to the emergency room 6 hours after the onset of the symptomatology, according to some authors, any treatment undertaken after 4 hours has no scientific basis[5], having exceeded the delay, fibrinolysis could not be performed in this situation.

OACR is a systemic complication that remains unknown to most physicians, hence the need to illustrate this case in order to sensitize ophthalmologists to this serious pathology.

IV. Conclusion

Central retinal artery occlusion is an ophthalmic emergency, the retinal analogue of a stroke. To date, there is no national consensus or guidelines on how this phenomenon should be managed.

In the event of a decrease in visual acuity following pancreatitis. The diagnosis of OACR must be evoked in order to achieve an early management, even if the visual prognosis remains poor.

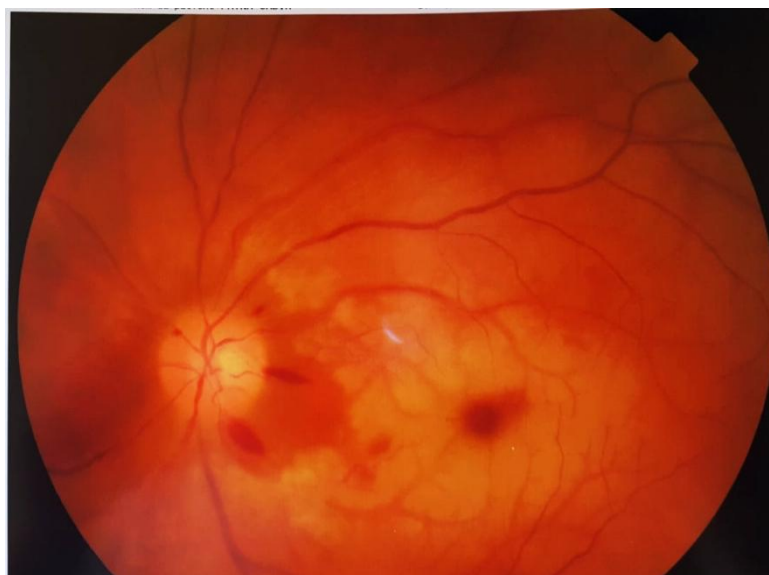

Fig.1: Left fundus photograph displaying diffuse macular edema with an intact choroidal circulation and scattered intraretinal hemorrhages

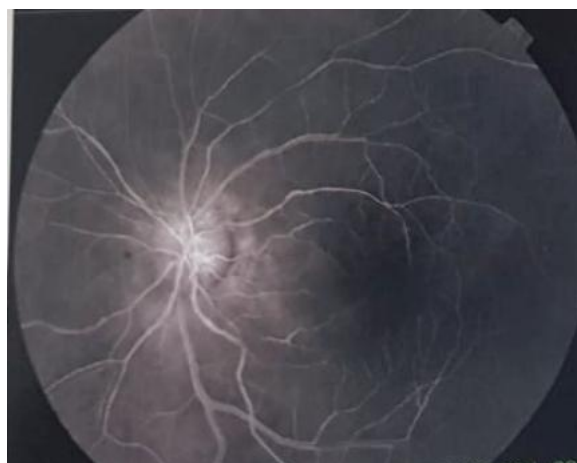


FIGURE 2: Retinal angiography shows the absence of perfusion of the occluded retinal artery branch

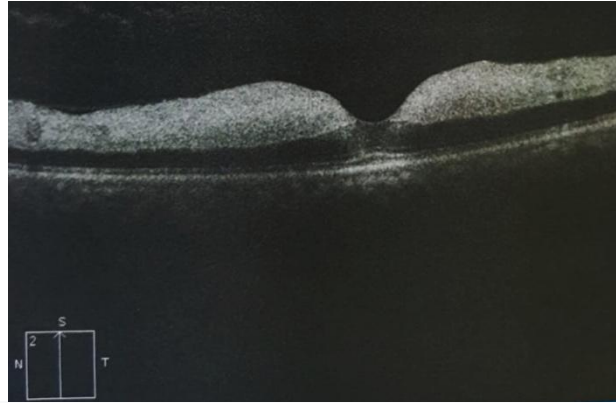


FIGURE 3: oct showed increased reflectivity and thickness of the inner retina and a corresponding decrease of reflectivity in the outer layer of the retina

Références

- [1]. Timoney, PJ, Pate, JC, Pearson, PA et Crandall, J. (2009). OCCLUSION BILATERALE DE L'ARTERE RETINALE CENTRALE CHEZ UN PATIENT ATTEINT DE PANCRÉATITE AIGU. Cas rétinien et rapports succincts, 3(3), 308-309.
- [2]. Nakata A, Sekiguchi Y, Hirota S, Yamashita Y, Takazakura E. Central retinal artery occlusion following cardiac catheterization. *Jpn Heart J* 2002;43:187—92.
- [3]. Blanco VR, Morís C, Barriales V, González C. Retinal cholesterol emboli during diagnostic cardiac catheterization. *Catheter Cardiovasc Interv* 2000;51:323—5.
- [4]. Loewenstein A, Goldstein M, Roth A, Lazar M. Cilioretinal artery occlusion during coronary catheterization. *Acta Ophthalmol Scand* 1999;77:717—8.
- [5]. 14-Hayreh SS. Intra-arterial thrombolysis for central retinal artery occlusion. *Br J Ophthalmol*, 2008; 92: 585-87

Y. Hidan, S.Bahti, et. al. "Transcerebellar Diameter, a Reliable Parameter to Identify Gestational Age in Second Trimester." *IOSR Journal of Dental and Medical Sciences (IOSR-JDMS)*, 20(07), 2021, pp. 01-03.