

Minor Salivary Gland Tumor At The Angle of Mouth:- Satisfactory Outcome In A Feared Entity: A Case Report.

**Karthik P, Anurag Saraswat, Fahad Tauheed, Purshotam Dass Gupta,
Vikram Singh Chauhan.**

Dept. of General Surgery, SMS &R, Sharda Hospital.

Abstract

Pleomorphic adenoma (PA) is the most common benign tumour affecting both major and minor salivary glands. Parotid gland is the most commonly affected major salivary gland. Minor salivary gland adenoma is a rare entity. Among minor salivary glands, palate is the most commonly affected site followed by lips, cheeks, gingiva, floor of the mouth, and tongue. PA of minor salivary glands at angle of mouth is a very rare occurrence both in adults and children. In this report, we present a case of PA of minor salivary glands at angle of mouth in an adult patient who was successfully treated by surgical excision, and after a follow-up period of 6 months there was no recurrence.

Date of Submission: 08-07-2021

Date of Acceptance: 23-07-2021

I. Introduction

Salivary gland neoplasms represent less than 1% of all tumours in the body, and 3-5% of all head and neck neoplasms. Minor salivary gland tumours (MSGTs) are infrequent, accounting for 10-15% of all salivary neoplasms, and are fundamentally located in the palate (50%), lips (15%), cheek mucosa (12%), tongue (5%) and floor of the mouth (5%), among other regions⁽¹⁾.

Unlike the major salivary glands where approximately 80% of tumours are benign, 80% or more of minor salivary gland tumours are malignant and they tend to have a great variation in presentation and histology⁽²⁾

There are between 450 and 750 minor salivary glands in the head and neck region, scattered throughout the Sino nasal cavities, oropharynx, larynx and trachea with the majority being found in the oral cavity⁽³⁾. In this report, we present a case of PA of minor salivary gland at angle of mouth in an adult patient which was successfully treated by surgical excision.

II. Case Presentation:

A 32 years old male patient presented to the OPD of department of general surgery at School of medical sciences & research and hospital, Greater Noida, Uttar Pradesh with a chief complaints of swelling over the inner left cheek extending upto angle of mouth since 2 years.

The history revealed that he developed a painless swelling at left cheek over the angle of mouth which was insidious in onset; initially it was approximately 1x1 cms, gradually doubled in it's size over the period of two years. He did not have any difficulty with speech and deglutition. The patient's past medical and surgical history was not significant, but the patient was a habitual tobacco chewer. On systemic examination, the patient was healthy and there was no regional lymphadenopathy.

On examination, facial symmetry was present and Overlying skin was normal. On intra oral examination, a non-tender swelling of approximately 2x2x1 cm was present at inner left cheek over the angle of mouth, which was disc shaped, firm in consistency with sub mucous fibrotic changes, free from skin and adhered to oral mucosa.

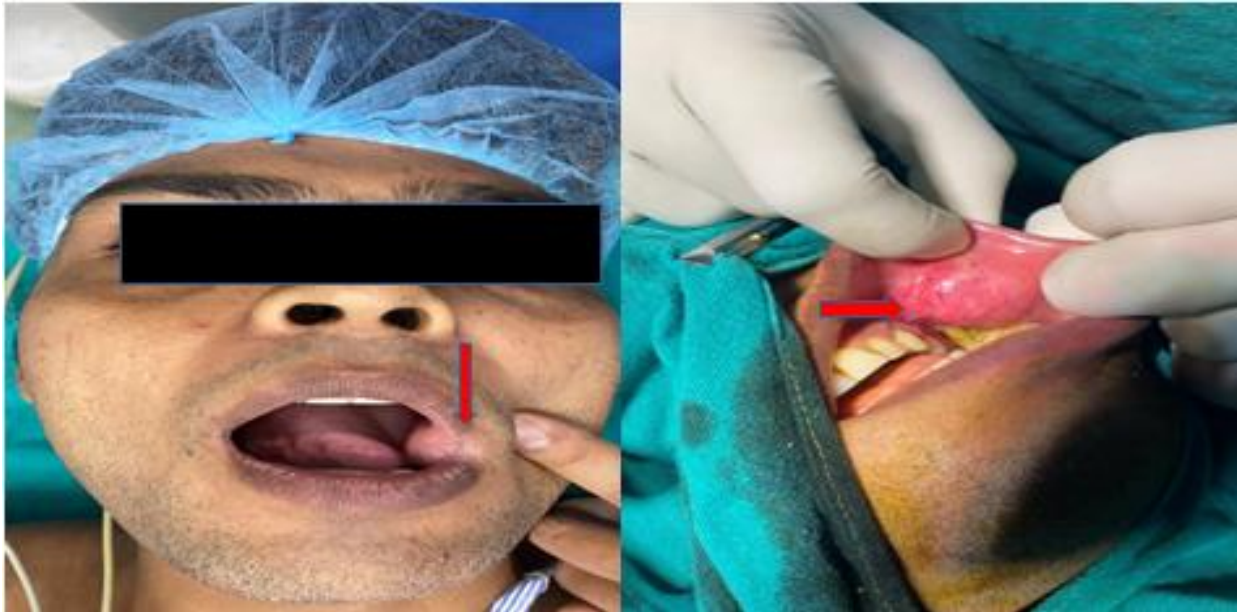

Fig 1: A) Extra oral and B) Intraoral view showing swelling at angle of mouth.

An Ultra sonogram of the left cheek revealed a well-defined rounded hypo echoic lesion with few foci of internal calcification with internal vascularity of size measuring 2x1.2 cm with posterior acoustic enhancement in intramuscular and subcutaneous plane seen over left cheek suggestive of a possible benign lesion.

In view of suspicious lesion of unknown origin in a habitual tobacco chewer, an urgent FNAC was advised.

FNAC revealed, Cytomorphological features suggestive of pleomorphic adenoma.

Based on the history, clinical presentation, ultrasonography and FNAC findings, the decision was made to surgically excise the lesion for excision biopsy and patient was taken up for elective surgery under general anaesthesia.

Per-Op:

The patient was taken up for elective surgery. A transverse incision made over the left buccal mucosa, dissection done up to capsule of adenoma. Blunt dissection done around the adenoma and specimen removed with 0.5mm of normal appearing surrounding margin. After achieving adequate haemostasis, wound closed with absorbable loose sutures. Specimen sent for histopathological examination.

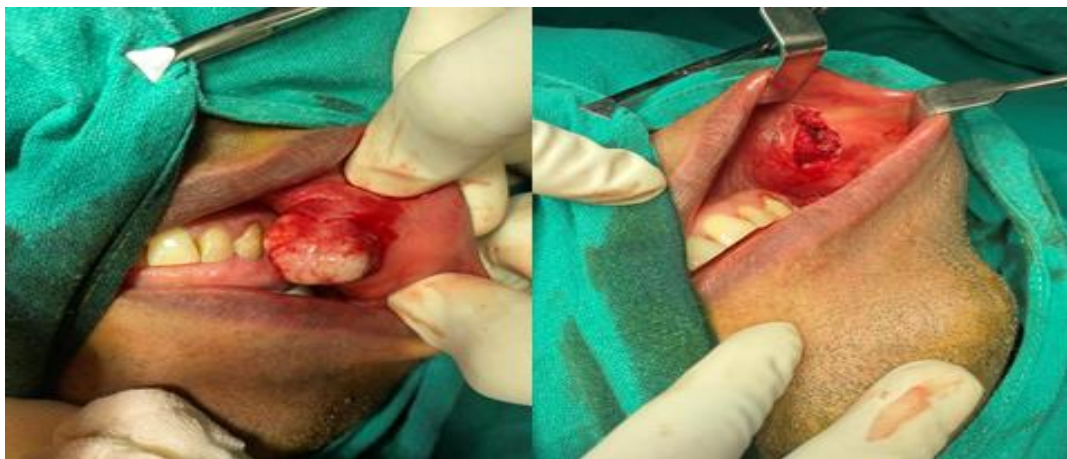

Fig:2 A) Exposure of the lesion B) surgical wound after excision of the lesion.

Post-Op:

Post-operative recovery and wound healing of the patient was uneventful. The patient was allowed orally in the evening. He tolerated oral feeds well without any pain. He was discharged on next day on oral antibiotics and providone iodine gargle solution.

Histopathology of the specimen- showed Encapsulated lesion composed of epithelial and myoepithelial components. Epithelial component is arranged in anastomosing tubules, nests, sheets, ribbons and cyst. Cells are predominantly columnar and cuboidal. Myoepithelial cells are cuboidal, spindle, plasmocytic and stellate and forms non descript sheets, trabeculae and cribriform pattern and are seen melting into the chondro myeloid stroma.

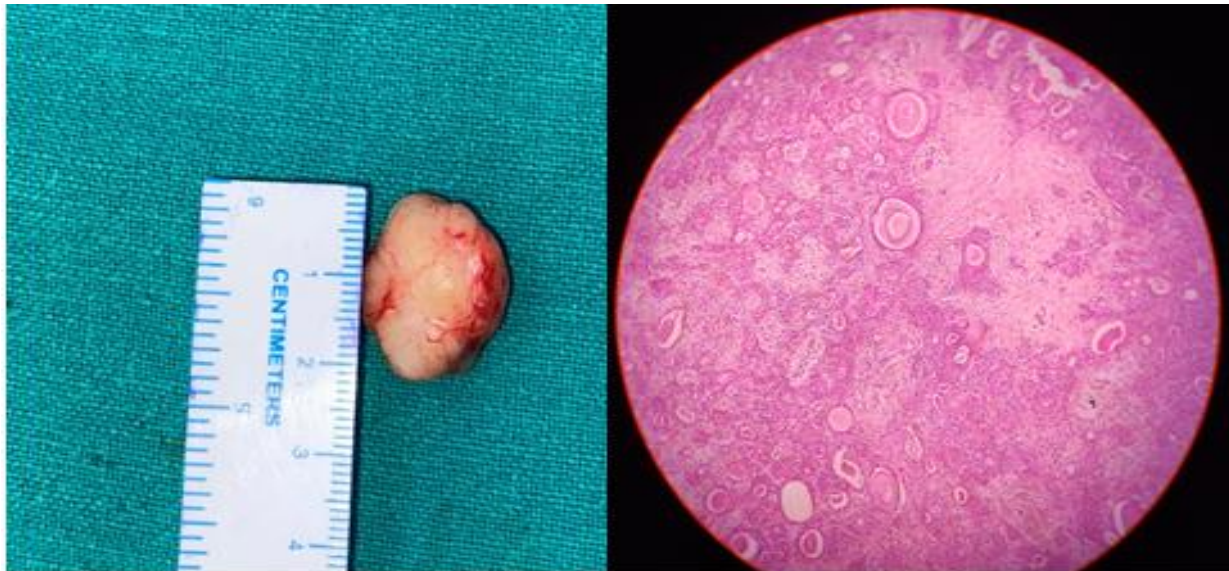


Fig:3 A) Excised adenoma B) histological composition of both epithelial and stromal elements

Follow-up:

Patient followed up after 1 week, 1 month, 3 month and 6 months without any traces of recurrence.

III. Discussion:

Minor salivary gland neoplasms represent less than 25% of intraoral salivary neoplasms. They have distinct characteristics, especially regarding frequency, distribution, and clinical aspects⁽⁴⁾.

Unlike major salivary gland neoplasms, the majority of minor salivary tumours are malignant. Bushra et al. reported that malignant tumours of the minor salivary glands constitute less than 0.5% of all malignant neoplasms⁽⁵⁾.

The aetiology of these tumours remains unknown. Unlike squamous cell carcinoma, for which more than 90% of patients are smokers, only 50% to 60% of patients with minor salivary gland tumours are smokers. There is an equal sex distribution among patients with minor salivary gland tumours⁽⁶⁾. These tumours most commonly present as slowly growing, painless, firm sub-mucosal masses⁽⁶⁾.

Differential diagnosis for the swelling at angle of mouth includes: minor salivary tumours, tumour of accessory parotid salivary gland, lipoma, myofibroma, neurofibroma, sebaceous cyst, epidermoid cyst, dermoid cyst, mucoepidermoid carcinoma, and adenoid cystic carcinoma.

The diagnosis of the salivary gland tumour includes clinical examination, supported by complementary techniques such as magnetic resonance imaging, computed tomography (CT) alone or combined with sialography, and fine-needle aspiration biopsy⁽⁷⁾. FNAC is recommended in the preoperative diagnosis of minor salivary tumours, with 96% accuracy. Open biopsy of these tumours is controversial due to potential tumour seeding⁽⁸⁾.

The management of MSGTs remains primarily surgical enucleation of encapsulated benign tumours⁽⁸⁾.

In our case the lesion was encapsulated, situated between the oral mucosa and the orbicularis oris muscle which was highly suggestive of a benign tumour of minor salivary gland origin. The lesion was excised intact with its capsule with margin of satisfactory. Inadequate resection, rupture of the capsule, or tumor spillage during excision can lead to local recurrence as these tumours often have microscopic pseudopod-like extensions into the surrounding tissues through the capsule. Therefore, long-term follow-up is required.

IV. Conclusion:

Pleomorphic adenoma of minor salivary gland at angle of mouth is a very rare entity, usually seen in adult patients. The most common symptom is a slow-growing, painless submucosal mass. Definitive diagnosis lies in the histopathological examination. Complete wide local surgical excision is the treatment of choice. Recurrences are uncommon but may be seen on long-term follow-up.

References:

- [1]. Olivia Pons Vicente, Nieves Almendros Marqués, Leonardo Berini Aytés, Cosme Gay Escoda. Minor salivary gland tumors: A clinicopathological study of 18 cases. *Med Oral Patol Oral Cir Bucal*. 2008;13(9):E582-8.
- [2]. Sonal Mishra, Y.C. Mishra. Minor salivary gland tumors in the Indian population: A series of cases over a ten year period. *Journal of oral biology and craniofacial research*. 2014; 4:174-180.
- [3]. M.J. Stricka, C. Kellyb, J.V. Soamesc, N.R. McLeana. Malignant tumours of the minor salivary glands—a 20 year review. *The British Association of Plastic Surgeons*. 2004;57: 624–631.
- [4]. Dmitry José de Santana Sarmiento¹, Maria de Lourdes Silva de Arruda Morais, Antonio de Lisboa Lopes, Costa et al. Minor intraoral salivary gland tumors: a clinical-pathological study. 2016;14(4):508-12.
- [5]. Bushra Rahman, Nadira Mamoon, Shahid Jamal, et al. Malignant tumors of the minor salivary glands in northern Pakistan: a clinicopathological study. *Hematol Oncol Stem Cel Ther*. 2008;1(2):90-93.
- [6]. Ian Ganly, MD; Snehal G. Patel, MD; Maria Coleman, et al. Malignant Minor Salivary Gland Tumors of the Larynx. *Arch Otolaryngol Head Neck Surg*. 2006;132:767-770.
- [7]. Jimsha Vannathan Kumaran, Mariappan Jonathan Daniel, Mithunjith Krishnan, et al. Salivary gland tumors: An institutional experience. *SRM J Res Dent Sci*. 2019;10:12-6.
- [8]. Grazyna Wyszynska-Pawelec, Michał Gontarz, Jan Zapała, et al. Minor Salivary Gland Tumours of Upper Aerodigestive Tract: A Clinicopathological Study. *Gastroenterology Research and Practice*. 2012.
- [9].

Karthik P, et. al. “Minor salivary gland tumor at the angle of mouth:- satisfactory outcome in a feared entity: A case report. Dept. of General Surgery, SMS &R, Sharda Hospital.” *IOSR Journal of Dental and Medical Sciences (IOSR-JDMS)*, 20(07), 2021, pp. 45-48