

A comparative study between unilateral and bilateral pedicle screw fixation combined with transforaminal lumbar interbody fusion(TLIF) for the treatment of low lumbar degenerative disc diseases

Dr. Tulasidas Bhattacharyya¹, Dr. Rajarshi Roy², Dr. Kunal Ram Phookun³,
Dr. Siddhartha Rai^{4,*}

¹Professor & HOD, Department of Orthopaedics, Gauhati medical college, Guwahati, Assam

²Registrar, Department of Orthopaedics, Gauhati medical college, Guwahati, Assam

³Senior Resident, Department of Orthopaedics, Gauhati medical college, Guwahati, Assam

⁴Senior Resident, Department of Orthopaedics, Gauhati medical college, Guwahati, Assam

*= Corresponding author, Address for correspondence: Dr. Siddhartha Rai, Senior Resident, Department of orthopaedic surgery, Gauhati medical college & hospital, p.o. indrapur, pin-781032, Bhangagarh, guwahati, assam, india;

Abstract

Background: Spinal fusion has become an important procedure in the management of spine degenerative disorders. TLIF, transforaminal lumbar interbody fusion for short, has become the standard technique in the management of LDDD (lumbar disc degenerative diseases) nowadays. The objective of our study was to compare the clinical and radiological outcome of unilateral pedicle screw fixation (UPSF) and bilateral screw fixation (BPSF) after unilateral transforaminal lumbar interbody fusion (TLIF) for the treatment of lumbar degenerative disc diseases. **Materials and Methods:** A total of 20 patients were included in the study out of which 8 were treated with UPSF (Group A) and 12 were treated with BPSF (Group B). The perioperative outcomes along with preoperative and postoperative clinical and radiological outcomes were recorded in the follow up period. Clinical outcomes were evaluated by the VAS, the ODI (Oswestry disability index). **Results:** As per the perioperative assessment, the intraoperative blood loss, intraoperative time were less in UPSF group compared to BPSF group ($p < 0.0001$). At the end of 1 year follow up, the fusion rates along with the clinical parameters were comparable in both the groups. **Conclusion:** UPSF technique with TLIF can attain similar clinical efficiency in the treatment of single-level low lumbar DDD when compared with BPSF technique, with less surgical injuries, less intraoperative time and shortened duration of hospital stay

Keywords: lumbar degenerative disc diseases; transforaminal lumbar interbody fusion; unilateral pedicle screw fixation; bilateral pedicle screw fixation.

Date of Submission: 08-07-2021

Date of Acceptance: 23-07-2021

I. Introduction

Lumbar disc degenerative diseases (LDDD) are considered a common disease which includes prolapsed lumbar disc, degenerative instability, spondylolisthesis of lumbar vertebrae, lumbar spinal stenosis and degenerative scoliosis. [1] Transforaminal lumbar interbody fusion (TLIF) was originally labelled by Harms and Rollinger in 1982 [2]. It has turned out to be one of the ordinary standard techniques for decompression of the ipsilateral foramen and an appropriate interbody fusion. High fusion rates have been reported.

TLIF combined with bilateral pedicle screw fixation results in rigid stabilization that will last while fusion takes place [3-4]. Although bilateral pedicle screw (PS) fixation after lumbar interbody fusion is accepted as a standard surgical procedure providing rigid fixation with great biomechanical stability and clinical benefits, the rigidity of bilateral (PS) fixation can cause device related osteoporosis of the vertebrae which makes the adjacent segment prone to load and motion induced degeneration. Some authors have proven that excessive stiffness can jeopardise the fusion due to graft resorption that is in hand due to lack of stress against the end plates. [5][6] With unilateral pedicle screw approach there is a reduction of retraction of thecal sac and nerve roots and preservation of contralateral structures are possible with sufficient disc exposure, with resection of a single facet joint. Other advantages include a decrease of blood loss, faster surgery procedure, reduced radiation dose, reliable fusion and reducing overall cost [7][8] with similar radiological outcome as in bilateral fixation [9].

However, studies comparing unilateral and bilateral screw fixation combined with TLIF have reported mixed results. The present study was as such undertaken to compare the effectiveness of unilateral and bilateral pedicle screw fixation with interbody fusion for single-segment(L4/5 or L5/S1) DDD with unilateral radicular symptoms in a single lower limb.

II. Materials And Methods

Ethics statement

An ethical clearance was obtained from institutional ethical clearance committee, Gauhati medical college and hospital before the commencement of the study.

Patients included in the study

A total of 20 cases of chronic degenerative disc disease with Patient age ranging between 40-65 years attending opd of Gauhati Medical College who met inclusion and exclusion criteria and gave written consent to participate in the study. The study was conducted for a period of one year from June 2019 to August 2020 at Gauhati medical college and hospital, Guwahati. All patients were followed up for a period of one year.

Inclusion criteria:

1. Recurrent lumbar disc herniation.
2. Degenerative lumbar spinal stenosis (DLSS).
3. Low grade (Grade I or II) spondylolisthesis

Exclusion criteria:

1. Age < 40 years.
2. Severe osteoporosis or posterior structural deficiency owing to congenital deformity or prior surgeries
3. Patients with previous lumbar fusion or multilevel disease were excluded from the study.
4. Traumatic spinal fractures, infectious conditions, metastasis.

Allocation of patients

The patients were allocated into two groups viz. Group A (unilateral screw fixation) and group B (bilateral screw fixation) using a randomization tool (Sealed Envelope Ltd. 2021). Create a blocked randomisation list. Accordingly, 12 patients were included in group A and 8 in group B.

Table 1 : Data collection schedule

| DATA COLLECTION SCHEDULE | | | | | | |
|---|--------|---------|---------|---------|---------|--------|
| EVALUATION | Pre-op | Post-op | 6 weeks | 3months | 6months | 1 year |
| Straight A-P & Lateral radiographs | + | + | + | + | + | + |
| T2 weighted MRI/ CT | + | | | | | + |
| Lateral view X-ray in extension & flexion | + | | | + | + | + |
| Neurological examination | + | + | + | + | + | + |
| VAS | + | + | + | + | + | + |
| ODI | + | | + | + | + | + |

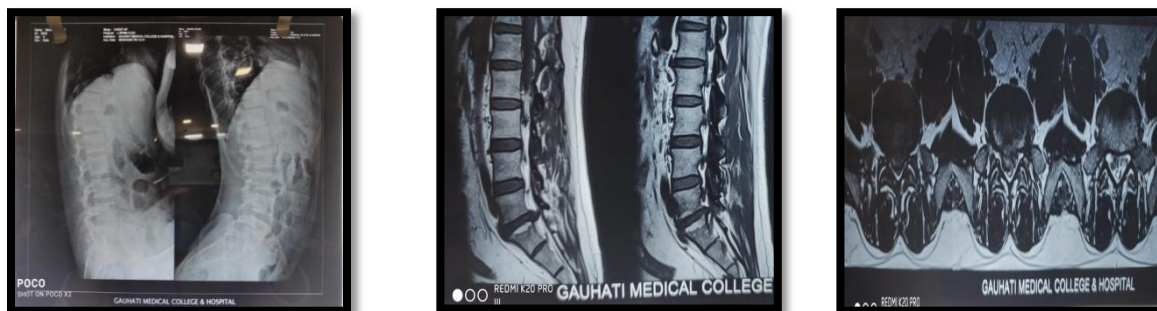

Figure (1-3) : preoperative radiographic assessment

OPERATIVE PROCEDURE:^{[10][11]}

Patients were placed in prone position , involved segment identified under C-ARM guidance and marked. Skin incision was decided depending on the symptomatic side, also depending on the type of disc protrusion seen preoperatively on MRI.If a disc herniation or foraminal stenosis was present , and predominantly one sided then that side is chosen.

A 8-10 cm incision was given midline or 1.5- 2cm lateral to midline, centred over the involved segment. The dissection was carried down to lumbodorsal fascia and the skin and subcutaneous tissue were retracted laterally on either side.

Fascial incision was done and using electrocautery and cob elevator the paraspinal muscles were separated. The spinous process and the lamina above and below the level of the pathology were exposed.

Pedicle screw placement were then done after proper identification of the pedicles under C-ARM guidance using techniques described earlier on the symptomatic side.

A ¼ -inch osteotome and kerrison rongeurs are used to remove the inferior articular process and superior portion of the superior articular process on the side chosen for TLIF.

In the procedure the spinous process, supraspinatus and interspinous ligaments and the contralateral facet joints remain untouched.

Exposure of the underlying disc space was facilitated by removal of the lateral margin of ligamentum flavum.

Exposure of the working window was then done by identifying the Kambin's triangle. The traversing nerve root forms the medial border, the exiting nerve root forms the lateral border and the superior aspect of the pedicle of the distal vertebra forms the base of the triangle.

The nerve roots were retracted and the dura was protected.

Epidural bleeding were controlled with gelfoam and cottonoids soaked in thrombin.

Specialized straight and angled ostetomes, pituitary rongeurs, rasps and curettes were used to elevate and remove disc material and cartilaginous end plates.

Additional distraction of the pedicle instrumentation was applied relying on ligamentotaxis.

Rasping of the end plates were done with rasper

Trial insertion of cage was done according to the disc height.

The disc space was filled with morsellised bone from the facetectomy after the cage packed with bone graft was inserted.

The spinal precut rods were then placed after they were contoured in lordosis. The locking screws were inserted and as distraction is applied the screws were tightened.

Wound was then closed in layers and sterile dressing applied.

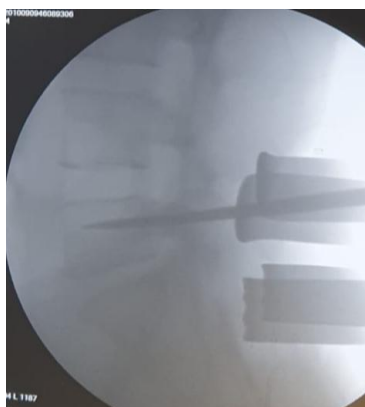


Fig 4- insertion of pedicle awl

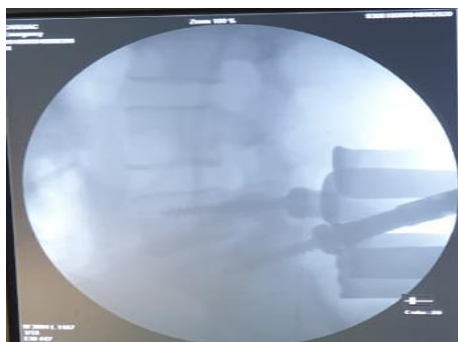


Fig 5- insertion of pedicle screws



Fig 6- final image of screw with cage

Patient mobilization was generally begun 24- 48 hours post surgery with or without support. No clear consensus exist on the duration of bed rest or type of external support , which depends on the pathologic condition and location and extent of fusion. Immobilization was continued until the patient was comfortable or until consolidation of fusion mass was seen on X-Rays. Starting of physical strengthening therapy of the spine also depends on the above factors..

Patients were encouraged on a gradual return to normal activities as much as possible avoiding bending, lifting and twisting for 3 months.

FOLLOW UP:

Sutures were removed at 2 weeks post surgery. Regular follow up was done at 3months,6 months and 1 year where the radiological and clinical parameters were assessed.

III. Results

This study was conducted on 20 patients with age ranging between 44-63 years. The mean age was: 48.85 years, 30% of patients in the study were above 50 years of age. There were 11 females and 9 males out of the 20 patients who underwent the procedure.. Average follow up time was 1 year. The intra operative blood loss, operative time were significantly lower in Group A compared to group B ($p < 0.001$)(table 2). At the end of final follow up(1 year), there was no statistically significant difference in both the groups in terms of increase in disk height of surgical segments, decrease in disk heights of caudal and cranial segments, increase in lumbar lordosis of surgical segments($p > 0.05$). Fusion rates although higher in BPSF group were not statistically significant($p > 0.005$)(table 3).

During the follow-up, the VAS score for back and leg pain, the ODI scores were significantly improved at all time points compared with preoperative in both UPSF and BPSF group. The ODI score of UPSF was lower than BPSF group at 1 year although not significant statistically.

We did not find any major complications for UPSF with TLIF or BPSF such as infection, pseudarthrosis, screws rupture and graft collapse until the final follow-up.

Table 2: Intraoperative parameters

| Operative parameter | Group A (UPSF) | Group B(BPSF) | p- value |
|---------------------------------|----------------|---------------|----------|
| Operative time(minutes) | 80.2±12.2 | 101.1±14.8 | <0.0001 |
| Intra-operative blood loss(ml) | 99.2 ±13.2 | 129.3±16.2 | <0.0001 |
| Mean hospitalization time(days) | 5.2±2.1 | 6.3±3.3 | 0.796 |

Fusion rating(table 3)

| Groups | 3 months | 6 months | 1 year | p-value |
|----------------|----------|----------|--------|---------|
| Group A (UPSF) | 32.3 % | 71.4% | 90.4% | >0.005 |
| Group B(BPSF) | 36.4% | 76.4% | 93.6% | |

IV. Discussion

Spinal fusion has become an important procedure in the management of spine degenerative disorders. And a variety of fusion patterns developed such as posterolateral fusion, anterior lumbar interbody fusion (ALIF) and PLIF. TLIF, transforaminal lumbar interbody fusion for short, has become the standard technique in the management of LDD nowadays, using bilateral pedicle screw (PS) system through a midline approach. Our study wanted to compare the outcome of TLIF via unilateral pedicle screw fixation and bilateral pedicle screw fixation.

BPSF with TLIF has been regarded as the standard surgical procedure to treat single-segment lumbar DDD(12). This method requires both sides of paravertebral exposure with intervertebral body fusion combined with bilateral pedicle screws to provide temporary spinal stability. However, this kind of procedure shows some disadvantages. Firstly, it requires extensive intraoperative paravertebral muscle exposure around the affected segment increasing the trauma, operation time, rates of infection, intraoperative blood loss, postoperative incision and muscle injury(13). Although , BPSF increases the stability of spine, it also leads to increase in costs of the implants alongwith increased incidence of neurological complications. Goel et al(14) first reported the benefits of UPSF, and several study found that UPSF is as effective as BPSF in lumbar spinal fusion (15-17). Some researchers, however, do not advocate in favor of UPSF due to its poor rigid system (18,19). There are some researchers holding the opinion that BPSF could result in degeneration of adjacent segments for the strong rigid fixation stress shielding in the fixed segment [20, 21].

In our study we observed that the operative time, intraoperative blood loss, average hospital stay of UPSF group were significantly less than BPSF group(<0.05). These were all due to the lesser trauma of the UPSF. There were no major complication found in the both UPSF and BPSF groups. The radiological parameters along with fusion rates were comparable in both the groups. The functional outcome assessed by VAS and ODI scores didn't yield any statistically significant difference in both the groups. Our findings are in concordance with other studies. Many researchers have concluded that UPSF with TLIF is a safe and feasible option for the treatment of lumbar DDD, since it presents better results regarding operation time, intra- and post-operative blood loss and implant costs when compared to BPSF [22,23,24.] Besides, there was no statistically significant difference in the fusion and complication rates comparing UPSF and BPSF groups [25, 26, 27] .

V. Conclusion

UPSF technique with TLIF can attain similar clinical efficiency in the treatment of single-level low lumbar DDD when compared with BPSF technique, with less surgical injuries, less intraoperative time and shortened duration of hospital stay. However, a large sample size is warranted to further validate the findings of our study.

References

- [1]. Huan Liu, Ying Xu, Si-Dong Yang, Tao Wang, Hui Wang, Feng-Yu Liu, Wen-Yuan Ding: Unilateral versus bilateral pedicle screw fixation with posterior lumbar interbody fusion for lumbar degenerative diseases A meta-analysis. *Medicine*96: 21 (e6882), 2017.
- [2]. Harms J. Rolinger H. A one –stager procedure in operative treatment of spondylolisthesis: dorsal traction- reposition and anterior fusion (author's transl). *Z Orthop Ihre Grenzgeb.* 1982; 120(3): 343-347
- [3]. Xiao YX, Chen QX, Li FC. Unilateral transforaminal lumbar interbody fusion: a review of the technique, indications and graft materials. *J Int Med Res.* 2009;37(3):908–917.
- [4]. Si-Dong Yang, Qian Chen, Wen-Yuan Ding, Jian-Qiang Zhao, Ying-Ze Zhang, Yong Shen, Da-Long Yang: Unilateral Pedicle Screw Fixation with Bone Graft vs. Bilateral Pedicle Screw Fixation with Bone Graft or Cage: A Comparative Study, *Med Sci Monit*; 22: 890-897, 2016.
- [5]. Potter BK, Freedman BA, Verwiebe EG, et al. Transforaminal lumbar interbody fusion: clinical and radiographic results and complications in 100 consecutive patients. *J Spinal Disord Tech.* 2005;18(4):337–346.
- [6]. McAfee PC, Farey ID, Sutterlin CE, et al. 1989 Volvo Award in basic science. Device-related osteoporosis with spinal instrumentation. *Spine (Phila Pa 1976).* 1989;14(9):919–926.
- [7]. Harris BM, Hilibrand AS, Savas PE, et al. Transforaminal lumbar interbody fusion: the effect of various instrumentation techniques on the flexibility of the lumbar spine. *Spine (Phila Pa 1976).* 2004;29(4):E65– 70.
- [8]. Deyo RA, Nachemson A, Mirza SK (2004) Spinal-fusion surgery - the case for restraint. *N Engl J Med* 350:722–726

- [9]. Liu Z, Fei Q, Wang B, Lv P, Chi C, Yang Y, Zhao F, Lin J, Ma Z.: A meta-analysis of unilateral versus bilateral pedicle screw fixation in minimally invasive lumbar interbody fusion. *PLoS One*. 6; 9 (11): e111979, 2014
- [10]. Shafik Tahseen El Molla, Hisham Anwer, Hatem Sabry, Unilateral Pedicular Screws and Interbody Lumbar Spine Fusion in Unilateral Degenerative Pathology (Technique and Outcome), *International Journal of Neurosurgery*. Vol. 4, No. 2, 2020, pp. 34-40. doi: 10.11648/j.ijn.20200402.1
- [11]. DOI:10.1016/j.wneu.2014.12.012 Corpus ID: 205714097 Unilateral and bilateral pedicle screw fixation in transforaminal lumbar interbody fusion: radiographic and clinical analysis. □ A. Villavicencio, Benjamin Serxner, A. Mason, E. L. Nelson, S. Rajpal, Nathan Faes, Sigit Burneikiene less Published 2015 Medicine World neurosurgery
- [12]. Sim HB, Murovic JA, Cho BY, Lim TJ, Park J. Biomechanical comparison of single-level posterior versus transforaminal lumbar interbody fusions with bilateral pedicle screw fixation: segmental stability and the effects on adjacent motion segments. *J Neurosurg Spine* 2010.
- [13]. Motosuneya T, Asazuma T, Tsuji T, Watanabe H, Nakayama Y, Nemoto K. Postoperative change of the cross-sectional area of back musculature after 5 surgical procedures as assessed by magnetic resonance imaging. *J Spinal Disord Tech*. 2006;19:318–22.
- [14]. Goel VK, Lim TH, Gwon J, Chen JY, Winterbottom JM, Park JB, et al. Effects of rigidity of an internal fixation device. A comprehensive biomechanical investigation. *Spine*. 1991;16:S155–61
- [15]. Shih-Hao Chen, Shang-Chih Lin, Wen-Chi Tsai et al, Biomechanical comparison of unilateral and bilateral pedicle screws fixation for transforaminal lumbar interbody fusion after decompressive surgery – a finite element analysis, *Musculoskeletal Disorders* 2012, 13:72
- [16]. Si-Dong Yang, Qian Chen, Wen-Yuan Ding et al, Unilateral Pedicle Screw Fixation with Bone Graft vs. Bilateral Pedicle Screw Fixation with Bone Graft or Cage: A Comparative Study. *Medical science monitor*, 2016; 22: 890-897
- [17]. Chen HH, Cheung HH, Wang WK, Li A, Li KC. Biomechanical analysis of unilateral fixation with interbody cages. *Spine*. 2005;30:E92–6
- [18]. Korovessis P, Papazisis Z, Koureas G, Lambiris E. Rigid, semirigid versus dynamic instrumentation for degenerative lumbar spinal stenosis: a correlative radiological and clinical analysis of short-term results. *Spine*. 2004;29:735–42. 24.
- [19]. Harris BM, Hilibrand AS, Savas PE et al: Transforaminal lumbar interbody fusion: The effect of various instrumentation techniques on the flexibility of the lumbar spine. *Spine (Phila Pa 1976)*, 2004; 29: E65–7
- [20]. Zeng ZY, Wu P, Mao KY, et al. Unilateral pedicle screw fixation versus its combination with contralateral translaminar facet screw fixation for the treatment of single segmental lower lumbar vertebra diseases. *Zhongguo Gu Shang*. 2015;28(4):306–12.
- [21]. Park P, Garton HJ, Gala VC, Hoff JT, McGillicuddy JE. Adjacent segment disease after lumbar or lumbosacral fusion: review of the literature. *Spine (Phila Pa 1976)*. 2004;29(17):1938–44.
- [22]. Mao L, Chen GD, Xu XM, Guo Z, Yang HL. Comparison of lumbar interbody fusion performed with unilateral or bilateral pedicle screw. *Orthopedics*, 2013; 36:e489–93
- [23]. Xiao SW, Jiang H, Yang LJ, Xiao ZM. Comparison of unilateral versus bilateral pedicle screw fixation with cage fusion in degenerative lumbar diseases: a meta-analysis. *Eur Spine J*, 2015; 24: 764–74
- [24]. Suk KS, Lee HM, Kim NH, Ha JW. Unilateral versus bilateral pedicle screw fixation in lumbar spinal fusion. *Spine (Phila Pa 1976)*, 2000; 25: 1843–47.
- [25]. Xue H, Tu Y, Cai M. Comparison of unilateral versus bilateral instrumented transforaminal lumbar interbody fusion in degenerative lumbar diseases. *Spine J*. 2012, 12:209-15.
- [26]. Lin B, Xu Y, He Y, Zhang B, Lin Q, He M. Minimally invasive unilateral pedicle screw fixation and lumbar interbody fusion for the treatment of lumbar degenerative disease. *Orthopedics*. 2013;36:e1071–6.
- [27]. Dong J, Rong L, Feng F, Liu B, Xu Y, Wang Q, et al. Unilateral pedicle screw fixation through a tubular retractor via the Wiltse approach compared with conventional bilateral pedicle screw fixation for single-segment degenerative lumbar instability: a prospective randomized study. *J Neurosurg Spine*. 2014;20:53–9

Dr. Tulasidas Bhattacharyya, et. al. “A comparative study between unilateral and bilateral pedicle screw fixation combined with transforaminal lumbar interbody fusion(TLIF) for the treatment of low lumbar degenerative disc diseases.” *IOSR Journal of Dental and Medical Sciences (IOSR-JDMS)*, 20(07), 2021, pp. 58-63