

Finger Guided Hemorrhoidal Artery Ligation With Recto Anal Repair (Fghal + Rar) : A New Approach In Surgical Management Of Hemorrhoids. Experience at Our Institute.

Dr. A. Suvarchala¹, Dr. B. Lokesh Kalki², Dr. G. Keerthi³

1. Assistant professor, Department of General Surgery, Andhra Medical College, Visakhapatnam, 530002.

2. Post graduate, Department of General Surgery, Andhra Medical College, Visakhapatnam, 530002.

3. Senior resident, Department of General Surgery, Andhra Medical College, Visakhapatnam, 530002.

Abstract:

Background: RAR (recto anal repair) is a minimally invasive technique which includes haemorrhoidal artery ligation and rectal mucopexy.

Objectives:

1) The purpose of this study is to identify the initial and 14th post operative day follow up results.

2) To know the early benefits, and complications that are associated with FGHAL-RAR.

Materials and methods:

40 cases of hemorrhoids (both internal and external) admitted in Department of General Surgery, KGH, Visakhapatnam from March 2020 to March 2021 were included in this study. All of them underwent FGHAL-RAR and their postoperative outcomes have been evaluated. Postoperative follow-up was evaluated clinically and by proctoscopy after 2 weeks, 1 month and 3 months respectively.

Results:

The initial symptomatology was discomfort in daily life, anal blood loss, anal pain and haemorrhoidal prolapse. Around 80% showed symptomatic relief immediately after the operative procedure.

After 2 weeks, significant improvement was observed with regard to blood loss, pain and prolapse. The improvement of symptoms were at par as mentioned in literature. After 3 months all the patients were symptom free.

Conclusion:

FGHAL- RAR procedure is a very effective technique for treatment of high-grade hemorrhoids. It's a minimally invasive technique with no major complications recorded. FGHAL- RAR offers a variety of advantages, including improved treatment of symptoms, lower pain levels, shorter hospital stays, less time off work and high patient satisfaction levels.

Keywords: Haemorrhoidal artery ligation, recto anal repair, prolapse, followup.

Date of Submission: 18-09-2021

Date of Acceptance: 03-10-2021

I. Introduction

Haemorrhoidal disease is one of the most common encountered problem in surgical OPD. The main pathogenetic cause for haemorrhoidal disease is increased intraluminal blood pressure of the distal rectum. This results in an imbalance between arterial inflow and venous return. Reasons for the increase in intraluminal blood pressure are multifactorial and most probably individually different.

While conventional haemorrhoidectomy is regarded as the gold standard in terms of efficacy, it is associated with significant morbidity.

In the last two decades, haemorrhoidal artery ligation (HAL), first described by Morinaga in 1995¹, has become universally accepted for the treatment of haemorrhoids. The rationale for this procedure is based on the assumption that arterial blood flow is mainly responsible for the enlargement of the haemorrhoidal plexus due to the absence of capillary interposition between the arterial and venous systems within the anal canal.

After studying the vascular nature of haemorrhoids, Aigner et al^{2,3} in 2006 postulated that there was three times increased blood flow in the superior haemorrhoidal vessels supplying the anal cushions and hence leading to engorgement. This subsequently leads to development of haemorrhoids.

The term Recto-Anal Repair (RAR) has been used to designate either the combined procedure (FGHAL + RAR), or mucopexy alone.

II. Materials and Methods

40 cases of hemorrhoids (both internal and external) admitted in Department of General Surgery, KGH, Visakhapatnam from March 2020 to March 2021 were included in the study.

Inclusion criteria:

- a) Patients with grade 3 and grade 4 internal hemorrhoids.
- b) Combined Internoexternal hemorrhoids grade 3 and grade 4.
- c) Age 18 - 70 years (both sex).

Exclusion criteria:

- a) Grade 1 and grade 2 internal hemorrhoids.
- b) Thrombosed hemorrhoids.
- c) Co-existing anal conditions such as anal fistula, perineal abscess, IBD, colorectal malignancies, portal hypertension.
- d) Previous perineal surgeries.
- e) Age <18 and >70 years.
- f) Follow-up criteria not met.

Operative technique:

- All 40 cases were done under spinal anesthesia.
- The average operating time was about 30 minutes.
- Under aseptic conditions, the perineal skin region was cleaned and the patient was covered with sterile draping.
- The beak proctoscope was lubricated and inserted through the anal canal to a depth of 6-7cm from the anal margin and 2-3cm above the dentate line.
- The proctoscope was slowly rotated and tilted to search for all the haemorrhoidal arteries (branches of the superior rectal artery) by palpation of pulsations.
- A figure-of-eight suture was conducted at the sites where the pulsations are most prominent. The procedure was repeated twice to make sure no arteries were left untied.
- After finishing the Haemorrhoidal Artery Ligation (HAL) procedure, the beak proctoscope was again inserted and a longitudinal running plication suture was placed (0.5cm between each step) through the enlarging slot in the anoscope. This was executed from proximal to distal under direct vision and the suture was tied. This procedure was then repeated for every prolapsing haemorrhoidal pile.
- For young patients with hypertonic sphincter and fissure in ano and patients below 60 years with acute fissure in ano, closed sphincterotomy was also done to give them symptomatic relief.

III. Results And Discussion

1.Age Distribution

The study included patients between 18 years and 70 years with the predominantly affected age group being 40-50 years, constituting 42% of the total cases.

S.no	Age	Number
1)	20-30 years	5
2)	30-40years	13
3)	40-50years	17
4)	50-60years	3
5)	60-70years	2
	Total	40

2.Sex Distribution

Females presented in slightly higher numbers than males. There is no statistical significance to this as the sample size is small.

S.no	Sex	Number
1)	Males	18
2)	Females	22

3.Number of patients in each group :

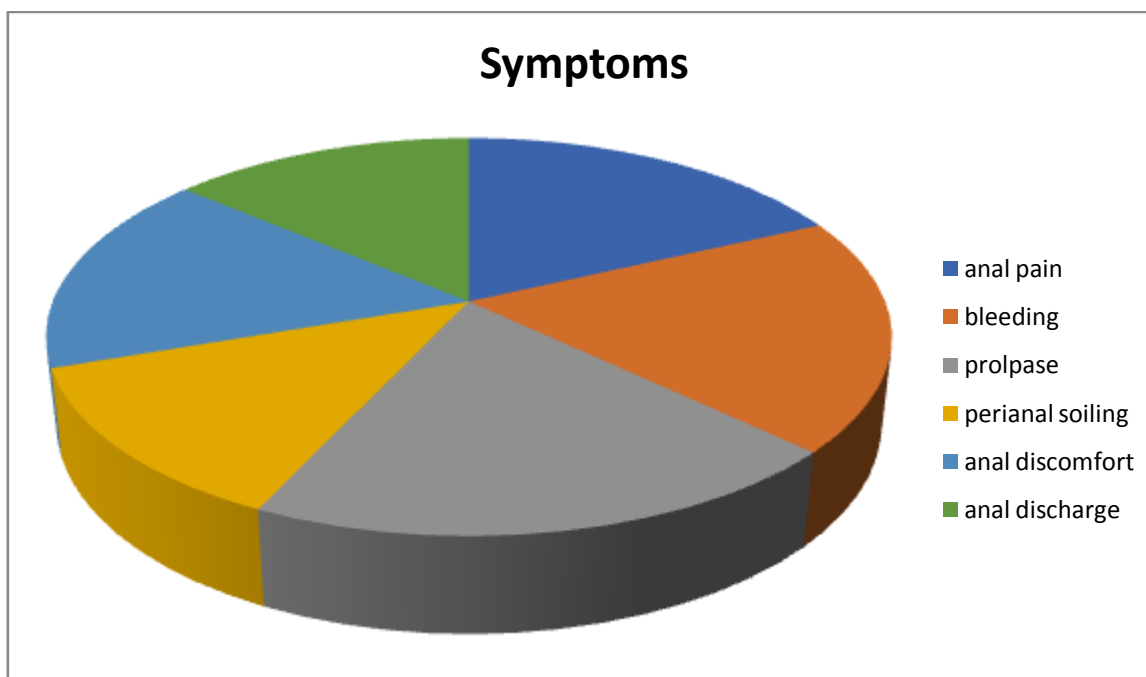
We operated more number of combined Internoexternal haemorrhoids followed by grade 4 internal haemorrhoids. (Goligher classification)

IV. Presenting complaints :

S.no	Type of hemorrhoids	Number of patients
1)	Internal grade 3 hemorrhoids	7
2)	Internal grade 4 hemorrhoids	13
3)	Combined Internoexternal haemorrhoids	20

The most common presenting symptoms were anal bleeding, haemorrhoidal prolapse and anal pain, among which 94% patients presented with haemorrhoidal prolapse.

S.no	Symptoms	Percentage of patients
1	Anal pain	85%
2	Anal Bleeding	90%
3	Haemorrhoidal prolapsed	94%
4	Perianal soiling	60%
5	Anal itching	35%
6	Anal discomfort	78%
7	Anal discharge	65%
8	Constipation	78%
9	Faecal incontinence	0%
10	Unpleasant odour	30%



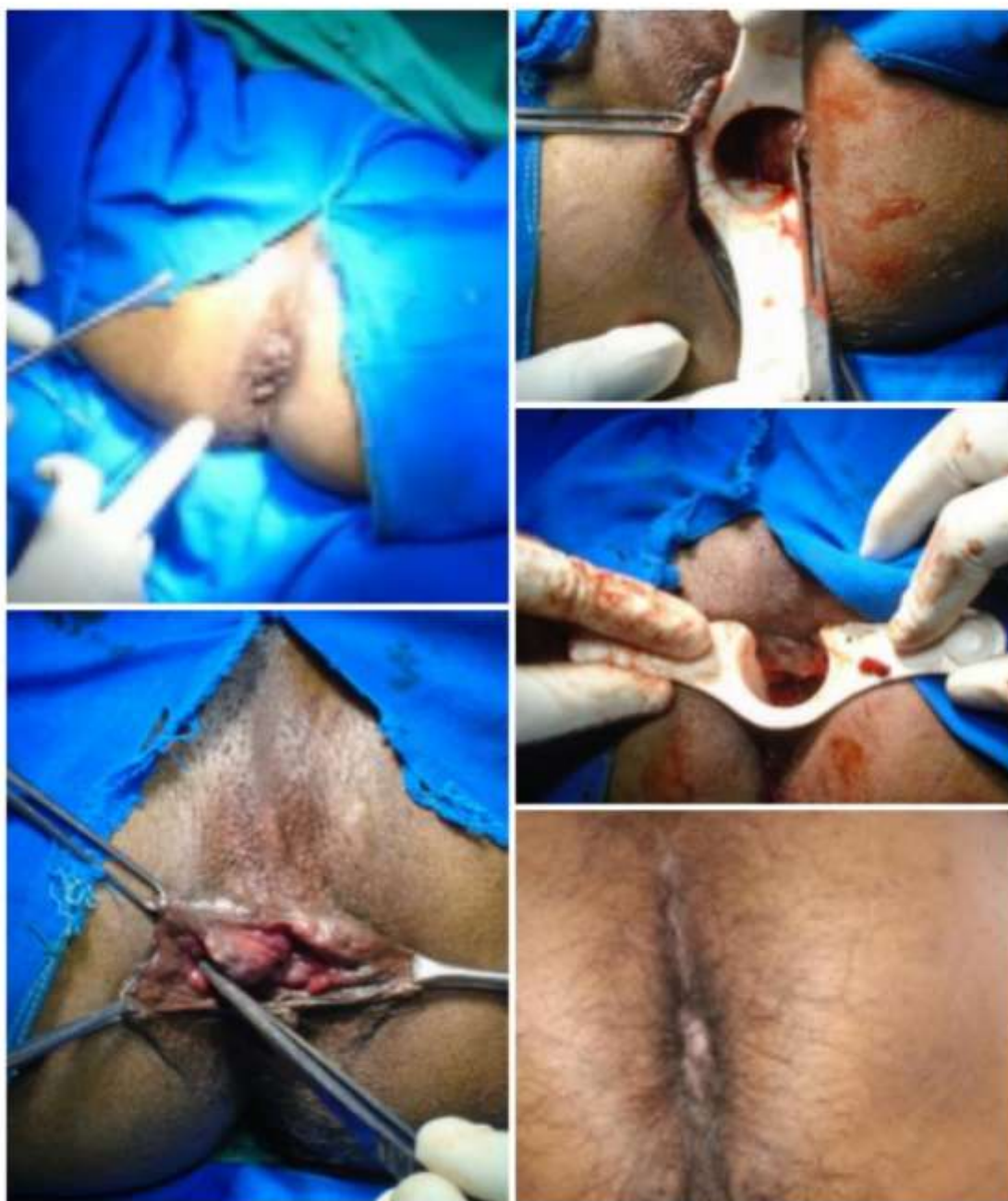V. Length of hospital stay:

The maximum stay in hospital was about 3-4 days and the minimum stay was 1 day. Most patients (90%) were discharged on POD-1.

10% patients are discharged on POD-2 and POD-3 due to anal pain, residual prolapse or anal bleeding.

S.no	Type of hemorrhoids	Maximum stay	Minimum stay
1	Grade 3 hemorrhoids	3 days	1 day
2	Grade 4 hemorrhoids	4 days	1 day
3	Internoexternal hemorrhoids	3 days	1 day

In a prospective study by Carlos Hoyuela et al, the average hospital stay (range) was 11 (3-25) hours⁴, which was similar to this study results.

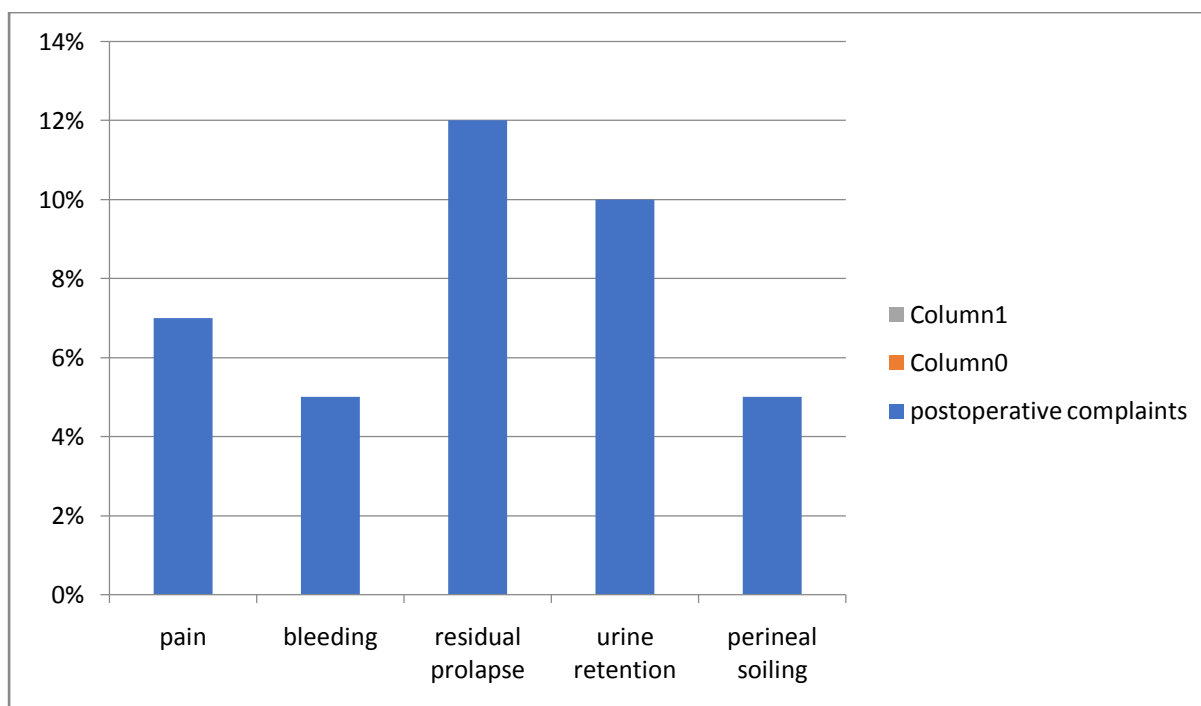


VI. Early postoperative complications :

The Milligan-Morgan (open) and Ferguson (closed) hemorrhoidectomy are the most commonly used surgical techniques. However, hemorrhoidectomy is notable to be associated with intense and prolonged postoperative pain⁵. Other complications associated with hemorrhoidectomy also occur with significant frequency. These include urinary retention (2–36%), bleeding (0.03–6%), anal stenosis (0–6%), and infection (0.5–5.5%)⁵. Sphincter defect or incontinence has been reported in up to 12% of patients after the surgery^{6,7}. The most common early postoperative complications are residual prolapse, persistent pain and bleeding. However this study shows urinary retention (10%), persistent bleeding (5%).

The residual prolapse was observed in 12% of the cases due to tissue edema which resolved later. Urinary retention was due to the effects of spinal anesthesia, and it subsided on POD-1. Postoperatively all patients were given oral analgesics and laxatives for a period of 1 week.

S.no	Postoperative complaints	Percentage of patients in each group
1	Persisting pain	7%
2	Persisting bleeding	5%
3	Residual prolapse	12%
4	Faecal incontinence	0%
5	Urinary retention	10%
6	Urinary tract infection	0%
7	Perianal soiling	5%
8	Fissure	1%
9	Constipation	3%



VII. Delayed complications during followup :

Relief of initial presenting complaints were noted in almost 98% patients.No impairment of continence, no bleeding during or after defecation after 3months , less discomfort, no hygiene problems, and no peri-anal soiling. The main complication on the 14th day was residual protrusion in 1 case and resolved on 4 weeks later.

S.no	Symptoms	At 2 weeks	At 1 month	At 3 months
1	Persistent bleeding	2%	1%	-
2	Residual prolapse	5%	2%	1%
3	Persistent pain	8%	-	-
4	Constipation	2%	-	-
5	Pruritus	1%	-	-
6	Mixed symptoms	3%	1%	-

VIII. Conclusion:

Based on the principles of Morinaga and Aigner, instead of using DGHAL probes which are available as single use and also expensive, we tried to palpate the branches of SHA with index finger at 2-3 cm above the dentate line(at the apex of pile masses) and ligate them all.

The number of patients showing relief of hemorrhoidal symptoms at 3 month follow-up was high. Bleeding was resolved in 95% of the patients, itching in 96%, burning in 100% and soiling in 100%. The recurrence of prolapse at 1 month was low, with no re-prolapse being recorded at 3months followup of the patients. Patient satisfaction was consistently high (>90%) at all follow-up intervals and the complication rate was low.

Recto Anal Repair not only has several perioperative advantages, it is also minimally invasive surgery, with low pain levels, shorter hospital stay and no major complications with high patient satisfaction levels. It also offers prolonged relief for all haemorrhoidal symptoms and for re prolapse. RAR is an effective form of treatment for high-grade hemorrhoids.

However this study needed more cases and a longer follow up period to analyze the late complications and recurrence.

References:

- [1]. Morinaga K, Hasuda K, Ikeda T. A novel therapy for internal haemorrhoids: ligation of the haemorrhoidal artery with a newly devised instrument (Moricorn) in conjunction with a Doppler flowmeter. *Gastroenterol.* 1995;90:610
- [2]. Aigner F, Gruber H, Conrad F, Eder J, Wedel T, Zelger B, Engelhardt V, La Böhler U, et al. Revised morphology and hemodynamics of the anorectal vascular plexus: impact on the course of haemorrhoidal disease. *Dis.* 2009;24:105–113.
- [3]. Aigner F, Bodner G, Gruber H, Conrad F, Fritsch H, Margreiter R, Bonatti H. The vascular nature of haemorrhoids. *J Gastrointest Surg.*
- [4]. HAL-RAR (Doppler guided haemorrhoid artery ligation with recto-anal repair) is a safe and effective procedure for haemorrhoids. Results of a prospective study after two-years follow-up **Carlos Hoyuela.**
- [5]. American Gastroenterological Association medical position statement: diagnosis and treatment of hemorrhoids,” *Gastroenterology*, vol. 126, no. 5, pp. 1461–1462, 2004.
- [6]. R. J. F. Felt-Bersma, R. Van Baren, M. Koorevaar, R. L. Strijers, and M. A. Cuesta, “Unsuspected sphincter defects shown by anal endosonography after anorectal surgery. A prospective study,” *Diseases of the Colon and Rectum*, vol. 38, no. 3, pp. 249–253, 1995.
- [7]. K.-M. Hiltunen and M. Matikainen, “Anal dilatation, lateral subcutaneous sphincterotomy and haemorrhoidectomy for the treatment of second and third degree haemorrhoids. A prospective randomized study,” *International Surgery*, vol. 77, no. 4, pp. 261–263, 1992

Dr. A. Suvarchala, et. al. “Finger Guided Hemorrhoidal Artery Ligation With Recto Anal Repair (Fghal + Rar) : A New Approach In Surgical Management Of Hemorrhoids. Experience at Our Institute.” *IOSR Journal of Dental and Medical Sciences (IOSR-JDMS)*, 20(9), 2021, pp. 06-11.