

Sea Fan Neovessels In Eales Disease ; A Case Report

M. Aachak, H. Brarou, I. Jeddou, H. Boui, T. Abdellaoui, F. El asri, Y.

Mouzarii, K. Reda, A. Oubaaz

Department of ophthalmology, Military hospital, Mohammed V university, Rabat, Morocco

Date of Submission: 04-04-2022

Date of Acceptance: 19-04-2022

A 35 YO old patient without any medical history presented with an acute decreasing of visual acuity in the right eye without any other clinical signs. Ophthalmic examination revealed a best corrected visual acuity limited to hand movement in the right eye and 6/10 in the left eye.

Slit lamp examination was normal and fundus evaluation showed an vitreous hemorrhage grade 4 and Sea fan neovascularizations in the right eye. B scan sonography of the left eye showed a flat retina.

An exhaustive etiologic investigation came back negative.

Eales disease diagnosis was made considering the bilateral lesions, the sea fan neovascularisations and the contralateral vitreous hemorrhage and thus exclusion of other systemic or ocular conditions that could present with similar retinal features.

Eales disease is an idiopathic peripheral ischemic retinal vasculopathy. The disorder is most prevalent among young males and normally affects both eyes (50 to 90 %). It is characterized by three overlapping stages of venous inflammation (vasculitis), occlusion, and retinal neovascularization [1].

The newly formed vessels neovascularization are in the form of a sea fan. The arteriovenous phase exhibits early laminar flow in veins, leakage of the sheathed and newly formed vessels. The venous phase displays considerable leakage of the new-formed blood vessels. Such is the case of our patient [2].

Bibliography

- [1]. M-H Errera, A Pratas, Eales' disease, *Journal Français d'Ophtalmologie*, Volume 39, Issue 5, May 2016, Pages 474-482
- [2]. J.L.Sánchez-Vicentea, A.Moruno-Rodríguez, Diagnosis of Eales disease from a macular epiretinal membrane, *Archivos de la Sociedad Española de Oftalmología (English Edition)*, Volume 94, Issue 11, November 2019, Pages 556-560

Figures

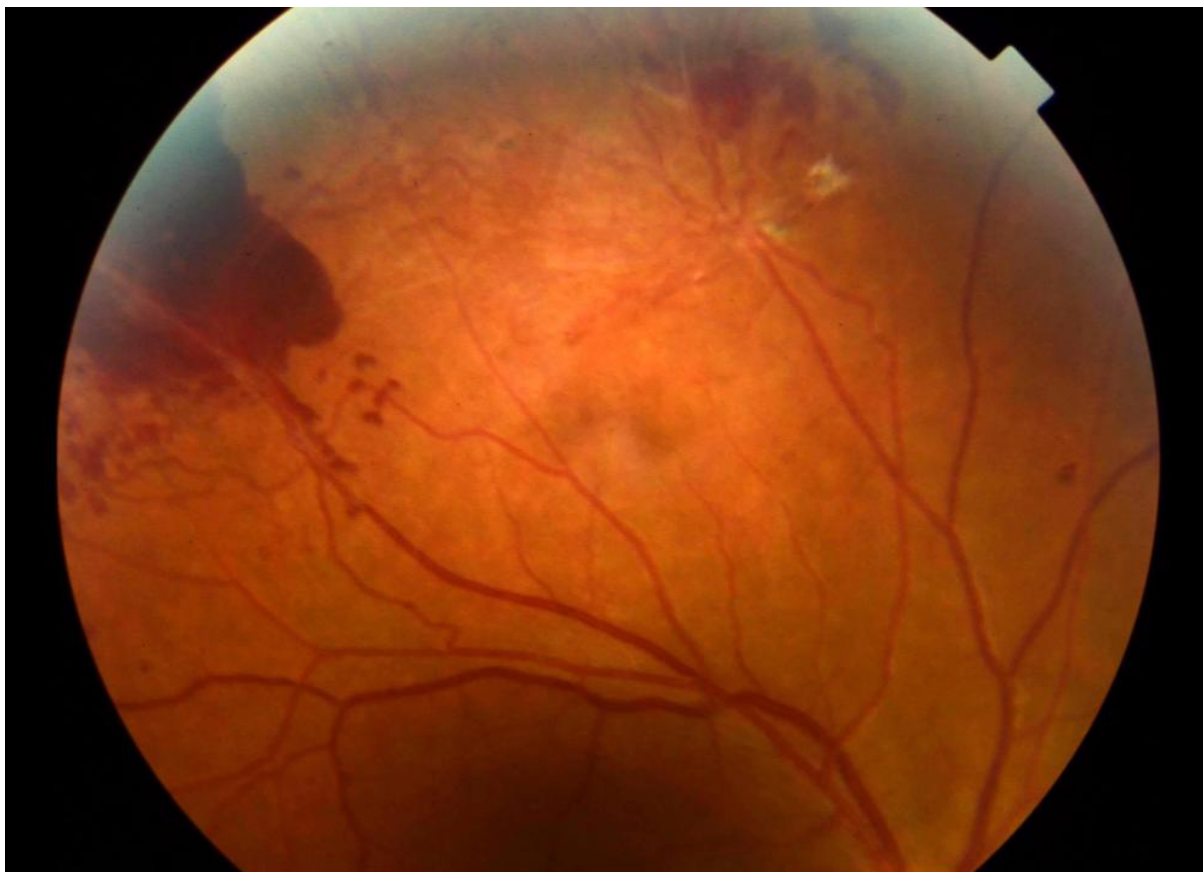

Figure 1: fundus photography showed a subretinal hemorrhage and neovascularizations in the right eye

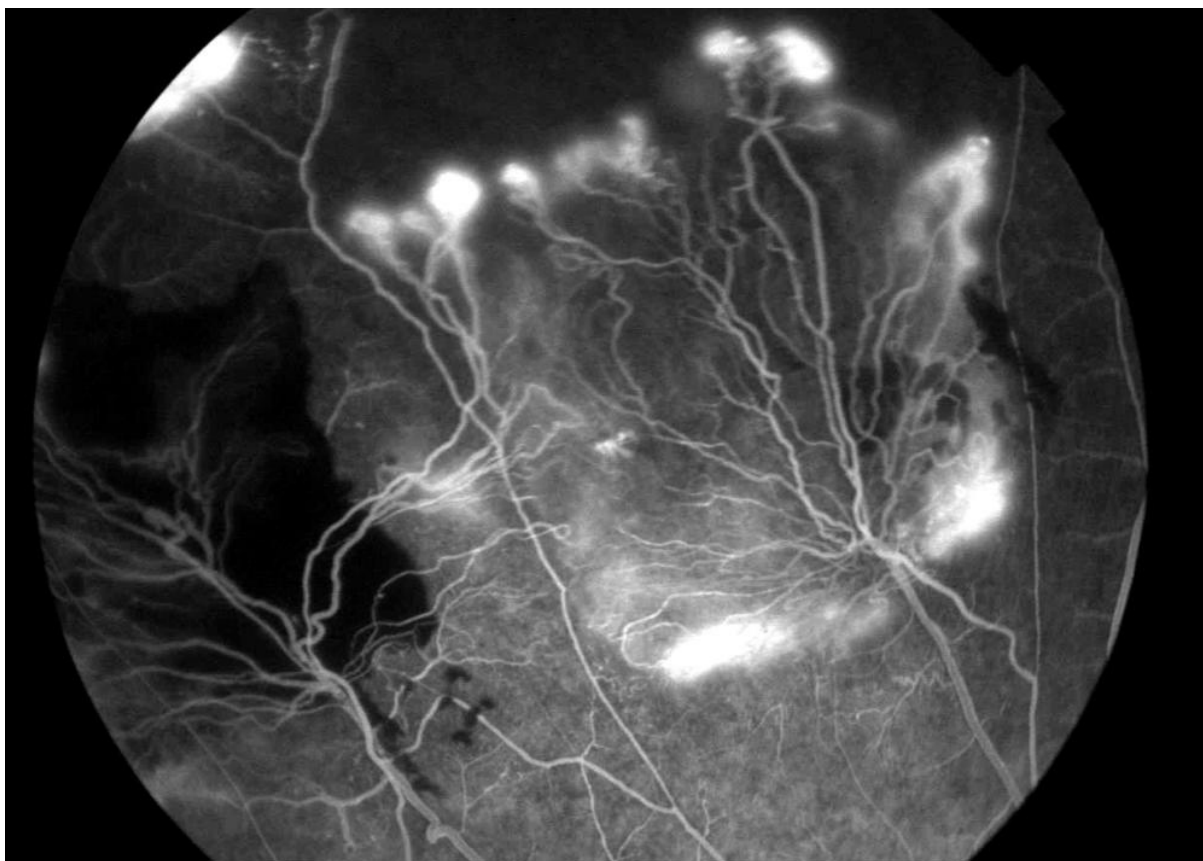


Figure 2: Sea fan neovascularizations