

## A Stitch In Time Saved The Eye!!

Dr. Rishi Sharma<sup>1\*</sup>, Dr. Nitin V Vichare<sup>2</sup>

1. Department of Ophthalmology, Military Hospital Secunderabad, Telangana-500015

2. Squint and Oculoplasty Surgeon, Command Hospital, Pune-411040, Maharashtra

\* Corresponding author- Dr. **Rishi Sharma**, Department of Ophthalmology, Military Hospital Secunderabad, Telangana-500015.

**ABSTRACT:** Ocular injury is the most common worldwide cause of monocular visual impairment and blindness. Globe rupture is a common sight-threatening ophthalmic emergency. We report a case of a globe rupture in 11 years-old boy with trauma in the right eye when he was accidentally hit with a pen by a fellow student resulting in a corneal laceration, hyphema, traumatic cataract, iris prolapse, and Retinal detachment. This case illustrates the importance of immediate and prompt primary repair of an open globe injury to safeguard against unsatisfactory visual outcomes.

**Running Title:** Stitch in time saved the eye

**Word count-** abstract(85), text-(902)

**Keywords:** Open globe injury (OGI) Globe rupture, corneoscleral laceration, primary repair

Date of Submission: 15-07-2022

Date of Acceptance: 31-07-2022

### I. Introduction

Ocular trauma is an important cause of visual impairment<sup>1</sup> and the World Health Organization has reported that globally 55 million people experience serious ocular trauma every year<sup>2</sup>. According to an estimate, the average incidence of Open globe injuries (OGI) worldwide is 3.5 per 100,000 persons, with more than 203,000 cases occurring each year.<sup>3</sup> Men and boys in the age group of 10-30 years make up approximately 80% of these patients with OGI.<sup>4</sup> In this article we present the successful primary repair of a globe perforation resulting in the restoration of anatomical integrity and preserving visual potential.

### II. Case History

11 years-old boy presented to the emergency department with an alleged history of trauma in his right eye when he was accidentally hit with a pen by a fellow student. Post-trauma individual had pain, redness, watering, and the sensation of something coming out of the eye. On examination, Visual acuity was light perception (PL) in the right eye with inaccurate Projection of rays (PR), 6/6 unaided in the left eye. The right eye was digitally soft with severe conjunctival chemosis, crescent-shaped corneal laceration (Fig 1) from 9 o'clock towards 5 o'clock with possible extension to the sclera, iris prolapse, hyphema, vitreous strands attached to the eyelashes. The rest of the details could not be visualized. The left eye examination was essentially normal with Intraocular pressure (IOP) of 16 mm Hg. Systemic examination was normal.

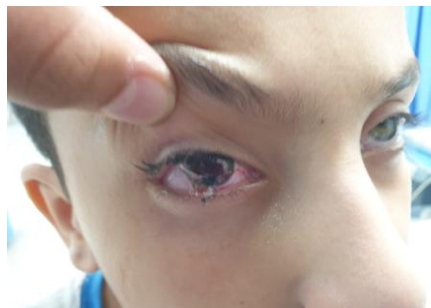

Fig 1: Open globe injury right eye

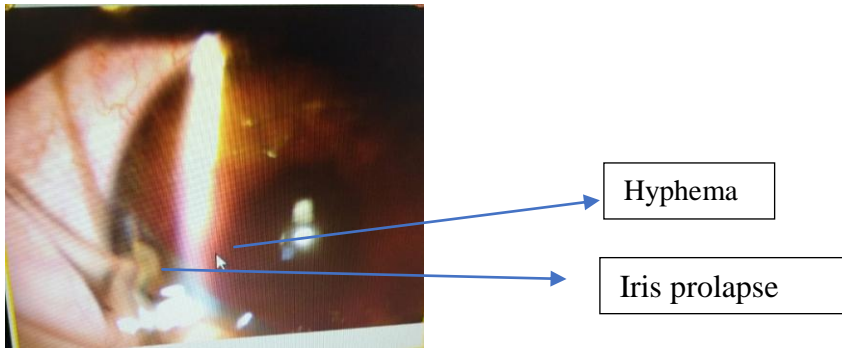


Fig 2: Slit lamp image

The diagnosis of globe rupture (Fig 2) was based on history and clinical evaluation. Primary repair of the globe was planned under General Anaesthesia. The patient was given tetanus immunization, antiemetics, analgesics, and intravenous broad-spectrum antibiotics. Laboratory tests included a full blood count, liver function tests, INR, prothrombin time, partial thromboplastin time, and kidney function tests, all were within normal. The primary repair involved sealing the corneoscleral laceration using 10/0 Nylon sutures (a total of 8 interrupted sutures). The prolapsed iris was viable and was repositioned by the iris spatula. Hyphema was washed using a bimanual irrigation aspiration technique and an Anterior vitrectomy was done (Fig 3).

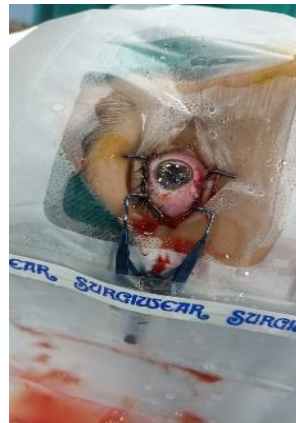

Fig 3: Intra-op

In the first post-operative visit (Fig 4), the eye was slightly injected with periorbital and conjunctival chemosis, the anterior chamber was formed with minimal hyphema, and no signs of wound leakage or infection were found. The lens was present however, the Fundal glow was not seen. The vision in the eye was PL+ with inaccurate PR. The patient was put on oral steroids along with intensive systemic and topical antibiotic-steroid, cycloplegics, and lubricants.

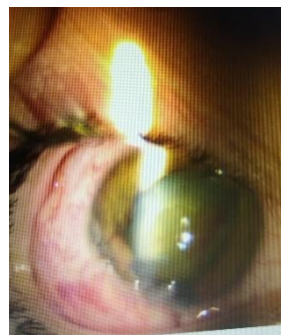


Fig 4: 1st Post-op Day

The primary repair restored the integrity of the eye and the patient was referred to a Vitreo-retinal (VR) surgeon for further evaluation and management. He subsequently underwent lens aspiration with Pars plana vitrectomy and Retinal detachment surgery. The patient was left aphakic and a contact lens was placed (Fig 5). The patient is on follow-up and planned for secondary Intra-ocular lens (IOL) implantation in the next 6 months.

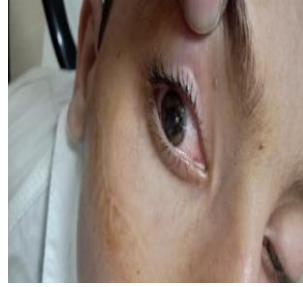

Fig 5: Post VR surgery

### III. Discussion

The Ocular Trauma Classification Group has developed a classification system based on BETT (Birmingham Eye trauma terminology) and features of globe injury at initial examination. Mechanism of injury, visual acuity at presentation, presence/absence of a relative afferent pupillary defect (RAPD), and extent (i.e., zone) of the injury are the four parameters based on which the mechanical trauma to the eye is subdivided into open and closed globe injuries. Full-thickness wound of the eyewall, due to either a laceration or an occult rupture is termed an Open globe injury (OGI).<sup>5</sup> Globe rupture is a condition where the integrity of the outer membranes of the eye is disrupted by blunt or penetrating trauma resulting in a full-thickness injury to the cornea or sclera. The pathophysiology of a ruptured globe involves any blunt force causing a rise of intraocular pressure (IOP) leading to frank rupture of the eyewall by means of an inside-out mechanism.<sup>2-5</sup> Signs of an occult globe rupture include hyphema, subconjunctival hemorrhage, distorted pupil, low intraocular pressure, prolapse of uveal tissue, and disturbed ocular motility.<sup>6-9</sup>

As a general principle, primary globe repair should be performed as soon as possible to increase the chances of anatomic and functional recovery and to prevent endophthalmitis.<sup>10,11</sup> Initially the primary repair addresses proper wound closure, management of any prolapsed tissue, and removal of blood and foreign material in the anterior chamber to permit an adequate view for subsequent ocular procedures. Management should include a protective eye shield and prophylaxis against tetanus and traumatic endophthalmitis.<sup>12,13</sup> Secondary vitreoretinal repair is performed in cases of vitreous hemorrhage, vitreous and/or retinal incarceration in a sclera wound, and/or retinal detachment.<sup>14</sup>

Principles of open globe repair<sup>15</sup>

1. To restore structural integrity and preserve visual potential. Repair under GA and aim at the closure of the globe as far as possible except in case of an expulsive hemorrhage.
2. Try to identify the extent of laceration/perforation.
3. Try to realign and reapproximate the corneal tissues with proper suturing techniques. Complex corneal lacerations may require tectonic grafts using cyanoacrylate and/or fibrin glue(s).
4. At the time of the injury, it is very difficult to assess the extent of lens damage and posterior capsule integrity, therefore it is advisable to plan lens removal in subsequent surgeries.

### IV. Conclusion

The surgical repair of globe perforation is a complex and challenging procedure, however, prompt assessment of the type and extent of the injury coupled with timely and meticulous intervention can improve the likely visual and anatomical outcomes for these patients.

#### Acknowledgments

None.

#### Conflicts of interest

The author declares that there are no conflicts of interest.

#### Funding

None.

### References

- [1]. Ramirez, D. A., Porco, T. C., Lietman, T. M. & Keenan, J. D. Ocular injury in United States Emergency Departments: seasonality and annual trends estimated from a nationally representative dataset. *Am. J. Ophthalmol.* 191, 149–155.
- [2]. Negrel, A. D. & Thylefors, B. The global impact of eye injuries. *Ophthalmic Epidemiol.* 5, 143–169 (1998).
- [3]. Pieramici DJ et al. *Am J Ophthalmol.* 1997;123(6):820-831.
- [4]. Casson RJ et al. *Clin Exp Ophthalmol.* 2002;30(1):15-18.
- [5]. Kuhn F et al. *Graefes Arch Clin Exp Ophthalmol.* 1996;234(6):399-403.

- [6]. Chronopoulos, Argyrios; Ong, Jong Min; Thumann, Gabriele; Schutz, James S. "Occult globe rupture: diagnostic and treatment challenge". *Survey of Ophthalmology*, Sep 2018. 63 (5): 694–699.
- [7]. Pieramici DJ et al. *Am J Ophthalmol*. 1997;123(6):820-831.
- [8]. Casson RJ et al. *Clin Exp Ophthalmol*. 2002;30(1):15-18.
- [9]. Bord SP, Linden J. Trauma to the globe and orbit. *Emerg Med Clin North Am*. 2008;26(1):97–123.
- [10]. Andreoli CM, Andreoli MT, Kloek CE, et al. Low rate of endophthalmitis in a large series of open globe injuries. *Am J Ophthalmol*. 2009;147:601–608.
- [11]. Cebulla CM, Flynn HW Jr. Endophthalmitis after open globe injuries. *Am J Ophthalmol*. 2009;147:567–568.
- [12]. Pokhrel PK, Loftus SA. Ocular emergencies. *Am Fam Physician*. 2007;76(6):829–836.
- [13]. Maw R, Pineda R, Pasquale LR. Traumatic ruptured globe injuries in children. *Int Ophthalmol Clin*. 2002;42(3):157–165.
- [14]. Coleman DJ. Early vitrectomy in the management of the severely traumatized eye. *Am J Ophthalmol*. 1982;93:543–551. Ryan SJ. Guidelines in the management of penetrating ocular trauma with emphasis on the role and timing of pars plana vitrectomy. *Int Ophthalmol*. 1979;1:105–108.
- [15]. Yonekawa Y, Chodosh J, Elliott D, Surgical Techniques in the Management of Perforating Injuries of the Globe. *Int Ophthalmol Clin*. 2013;53(4):127-137.

Dr. Rishi Sharma. "A Stitch In Time Saved The Eye!!" *IOSR Journal of Dental and Medical Sciences (IOSR-JDMS)*, 21(07), 2022, pp. 57-60.