

# A Study of Zygomycotic Fungal Organisms Causing Invasive Sinusitis and Its Management in Covid Era

Dr.B.Santhanakrishnakumar<sup>1</sup>,  
Dr.L.Sivasankari<sup>2</sup>,Dr.A.Vijaynivas<sup>3</sup>,Dr.Ravikumar<sup>4</sup>,Dr.B.Anuradha<sup>5</sup>,  
Dr.S.Saranya<sup>6</sup>

<sup>1</sup>(ENT, Government Thoothukudi Medical College and Hospital / The Tamilnadu Dr.M.G.R University, India)

<sup>2</sup>(ENT, Government Thoothukudi Medical College and Hospital / The Tamilnadu Dr.M.G.R University, India)  
<sup>3</sup>(ENT, Government Thoothukudi Medical College and Hospital / The Tamilnadu Dr.M.G.R University, India)  
<sup>4</sup>(ENT, Government Thoothukudi Medical College and Hospital / The Tamilnadu Dr.M.G.R University, India)  
<sup>5</sup>(ENT, Government Thoothukudi Medical College and Hospital / The Tamilnadu Dr.M.G.R University, India)  
<sup>6</sup>(ENT, Government Thoothukudi Medical College and Hospital / The Tamilnadu Dr.M.G.R University, India)

## Abstract:

**Background:** Invasive fungal rhinosinusitis is broadly classified into two types based on duration into acute and chronic. Acute or fulminant invasive fungal rhinosinusitis is a life threatening disease present usually in immunocompromised patients with impaired neutrophilic response. This condition is characterized by presence of hyphal invasion of sinus tissue and a time course of less than 4 weeks [1] [2]. Chronic invasive fungal rhinosinusitis is a slow destructive disease with a time course of more than 12 weeks duration.

**Materials and Methods:** This was a retrospective observational study. Regardless of the COVID RT-PCR status, all the data gathered from the case records of the patients in the year 2020 to 2022 who were admitted with clinical and radiological features of invasive chronic rhinosinusitis were included in the study. To eradicate the disease, Endoscopic sinus surgery / Endoscopic sinus surgery with partial maxillectomy were performed. KOH mount and fungal culture were sent. Anti-fungal therapy included Parenteral liposomal amphotericin B and oral posaconazole. Regular follow up was done for 3 months.

**Results:** About 30 invasive rhinosinusitis patients out of total 70 fungal sinusitis were registered for the study. Among them 17 were male and 13 were female. Among the 30 patients, 29 were diabetic and 26 had previous history of RT-PCR COVID positive. Sinonasal, orbital, palatine, and cerebral involvement were seen in 30, 14, 9 and 3 patients respectively. The most common clinical feature reported is facial pain (23) and facial swelling (21). Diabetes mellitus is reported to be the most common co-morbidity, followed by systemic hypertension. Surgical management included Endoscopic sinus surgery and Endoscopic sinus surgery with partial maxillectomy. Fungal culture revealed 22 patients with rhizopus, 5 patients with mucor, 2 patients with mixed species and 1 patient with absidia

**Conclusion:** Without early treatment, rapid progression of the disease with 50-80% mortality rates from intra-orbital and intra-cranial complications have been reported [3] Improvement of the host response is paramount for survival. Surgery is necessary to halt or slow the progression of the disease, to reduce fungal load and to provide tissue culture [3].

**Key Word:** Invasive fungal sinusitis, COVID – 19

Date of Submission: 05-01-2023

Date of Acceptance: 19-01-2023

## I. Introduction

Fungal rhinosinusitis is a disease of the nose and the paranasal sinuses that typically affect immunocompromised patients. There are several types of fungal sinusitis. The classification depends on the degree of invasion of the sinuses. The overarching categories are non-invasive and invasive fungal sinusitis [4]. Invasive fungal sinusitis is further classified into acute, granulomatous and chronic type.

Acute invasive fungal rhinosinusitis is characterized by presence of hyphal invasion of sinus tissue and time course of less than 4 weeks. Aspergillus and the fungi in the order Mucorales (rhizopus, rhizomucor and mucor) are the most common implicated species [4]. Granulomatous variety is defined by invasive fungal

infection lasting more than 12 weeks [5]. The causative agent is almost exclusively *Aspergillus flavus* [5]. Most commonly seen in countries like Sudan, India, Pakistan and Saudi Arabia [5]. Chronic invasive fungal rhinosinusitis is a slowly destructive disease with a time course of more than 12 weeks duration. The most common fungi implicated is *Aspergillus fumigatus* [5].

### **MUCORMYCOSIS :**

Mucormycosis is caused by the fungi belonging to the order of MUCORALES. The fungi classified under the Mucorales physically resemble ribbon-like hyphae that are broad, aseptate, or sparsely septate. Mucorales includes 11 genera and 27 species that are connected to human illnesses. The most frequent pathogen causing mucormycosis worldwide is *Rhizopus arrhizus*, followed by the species of *Cunninghamella*, *Lichtheimia*, *Apophysomyces*, *Rhizomucor*, *Mucor*, and *Rhizomucor* [10]. Angio-invasion and increased mortality are linked to mucormycosis [10]. Diabetes mellitus is the most common risk factor in the Asian continent, whereas haematological malignancies and transplantation are the major risk factors in European countries and the United States [10].

Generally referred to as "the black fungus," frequently results in necrosis throughout the head and neck, including the nose, paranasal sinuses, orbits, and facial bones, with a potential for cerebral dissemination. Due to the disease's rapid progression and frequently delayed diagnosis, it has a significant morbidity and fatality rate. The Indian Health Ministry has encouraged all states to designate mucormycosis an epidemic due to the sheer size of the outbreak. The condition is typically connected to COVID-19 infections brought on by the B.1.617.2 (Delta) variation. Patients who have specific predisposing medical factors, such as immunosuppression and diabetic ketoacidosis, are more likely to develop mucormycosis. Depending on how the person was exposed to the fungus—through ingestion, inhalation, direct contact, or violent inoculation—progressive tissue necrosis can develop at various anatomical sites. It has an impact on various organ systems, including the gastrointestinal tract, respiratory system, and central nervous system. The most prevalent site of rhinocerebral mucormycosis, which affects the head and neck, is the nose, although it can also spread to the paranasal sinuses, orbit, facial bones, and cranial cavity. Mucormycosis in the bone marrow may promote fungal growth by damaging the endothelial lining of vessels, resulting in vascular insufficiency and leading to bony necrosis and fungal osteomyelitis. The enhanced expression of platelet-derived growth factor (PDGFRB) signalling has been linked to the angioinvasive aspect of mucormycosis.

## **II. Material And Methods**

The study is based on all the data that was collected from the case records of patients who were admitted and suspected to have clinical and radiological features of fungal sinusitis and managed by the Department of ENT, Thoothukudi Medical College, were included in this study.

**Study Design:** Retrospective study

**Study Location:** This was a tertiary care teaching hospital based study done in Department of ENT, at Government Thoothukudi Medical College Hospital, Thoothukudi

**Study Duration** 2020 to 2022.

**Sample size:** 30 patients.

### **Procedure:**

Regardless of age, COVID-19 status, prior COVID-19 history, or underlying comorbidities, all data from the case records of patients who were admitted and suspected to have clinical and radiological features of fungal sinusitis and managed by the Department of ENT, Thoothukudi Medical College, were included in this study. Imaging tests (CT, MRI), KOH mounts, and diagnostic nasal endoscopy were done for all patients. Relevant patients underwent endoscopic sinus surgery and endoscopic sinus surgery with partial maxillectomy. Intraoperative specimens were sent for fungal culture and histopathological examination. Surgery was not offered to those who were in critical condition or unsuited for it. All patients received antifungal treatments, including oral posaconazole and parenteral liposomal amphotericin-B.

## **III. Result**

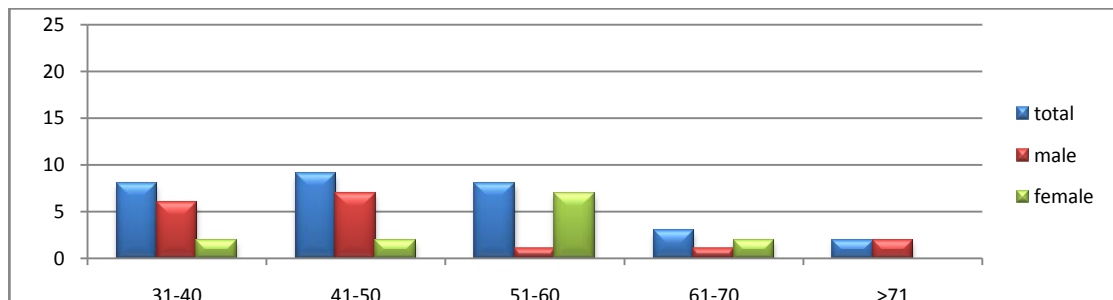
A total of 30 invasive rhinosinusitis patients among the 70 fungal sinusitis cases admitted and taken up for the study. Among them 17 were male and 13 were female. Among the 30 patients, 29 were diabetic and 26 had previous history of RT – PCR COVID positive. In fungal culture, 22 patients had *Rhizopus*, 5 patients had *Mucor*, 2 patients had mixed specimens. Left sided involvement is more common than right sided involvement. Sinonasal, orbital, palatine, and cerebral involvement were seen in 30, 14, 9 and 3 patients respectively. The most common clinical feature reported is facial pain (23), facial swelling (21), orbital swelling (12), orbital pain (9), and headache (8). Diabetes mellitus is reported to be the most common co-morbidity (27), followed by systemic hypertension (7), tuberculosis (2), chronic kidney disease (2), coronary artery disease (2), hypothyroidism

(1) and carcinoma (1). Surgical management included Endoscopic sinus surgery in 29 patients and Endoscopic sinus surgery with maxillectomy in 1 patient. Fungal culture revealed 22 patients with rhizopus, 5 patients with mucor, 2 patients with mixed species and 1 patient with absidia.

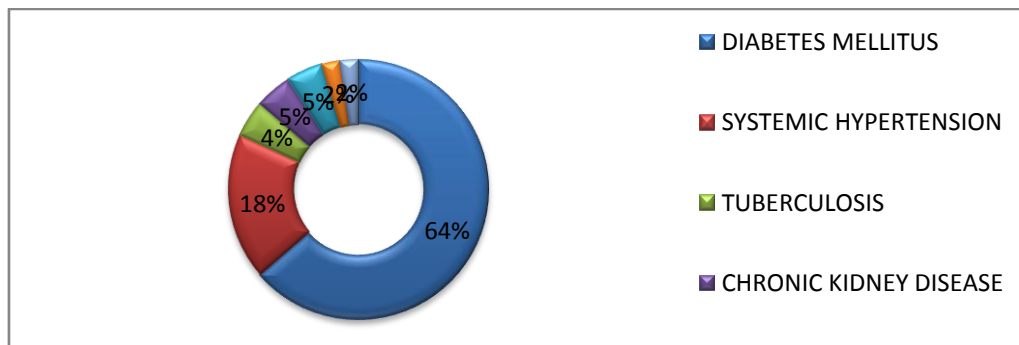
Table no 1 shows the incidence of invasive fungal sinusitis among different age groups. In the age group of 31–40 years, 9 individual was affected, 9 in the age group of 41–50 years, 7 in the age group of 51–60 years, 3 patients in the age group of 61–70 years, 2 patients in the age group of 71–80 years. Hence, the most common age group affected is reported to be between 31 to 50 years. It is also found that a total of 17 males and 13 females were affected, indicating that the disease is more prevalent amongst the males.

**Table no 1: DISTRIBUTION AMONG AGE GROUPS AND SEX.**

AGE GROUP	31-40	41-50	51-60	61-70	>71
TOTAL	9	9	7	3	2
MALE	6	7	1	1	2
FEMALE	3	2	7	2	0



The most frequent concomitant condition is uncontrolled diabetes mellitus (64%) followed by systemic hypertension (18%), chronic renal disease and coronary artery disease (5%), pulmonary tuberculosis and cancer (2%).



Involvement in the sinonasal region is more common followed by involvement in the orbital, palatal region, and cerebral region.

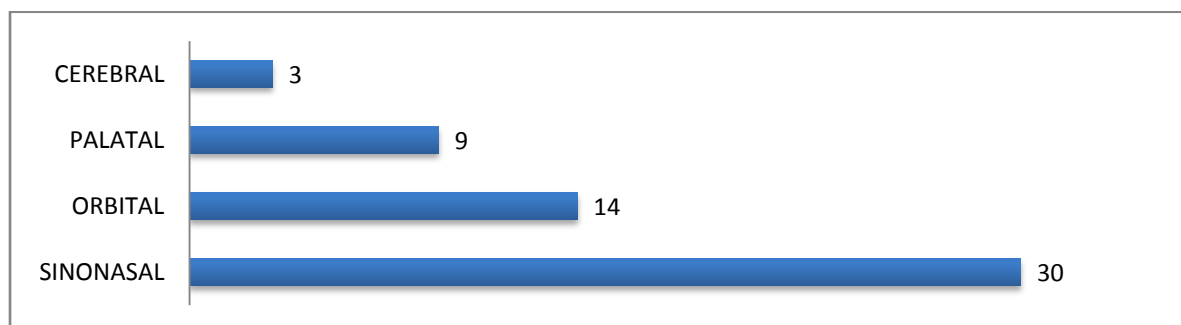


Table 2 shows; the most prevalent clinical feature of sinonasal involvement were facial, facial swelling, headache, and nasal obstruction which affected 23, 21, 8, and 4 patients respectively. In cases of orbital involvement, 12 patients had orbital swelling, and 9 patients had orbital pain. In cases of palatal involvement, there were 7 cases of palatal discoloration, 2 cases of palatal ulceration, 6 cases with loosening of

tooth , 3 case with history of toothache, 2 case with trismus , and 1 case with an oroantral fistula. In cerebral involvement , 2 patients presented with facial nerve palsy and cavernous sinus thrombosis.

**TABLE NO 2 :SPECTRUM OF CLINICAL MANIFESTATIONS IN PATIENTS**

S.NO	SYMPTOMS AND SIGNS	NUMBER OF PATIENTS	%
1.	FACIAL PAIN	23	76
2.	FACIAL SWELLING	21	70
3.	ORBITAL PAIN	9	30
4.	ORBITAL SWELLING	12	40
5.	HEADACHE	8	26.6
6.	PALATAL DISCOLORATION	7	23.3
7.	PALATAL ULCERATION	2	6
8.	NASAL OBSTRUCTION	4	13.3
9.	FACIAL NERVE PALS	2	6.6
10.	TOOTH ACHE	3	10
11.	TRISMUS	2	6.6
12.	LOOSENING OF TOOTH	6	20
13.	OROANTRAL FISTULA	1	3.3

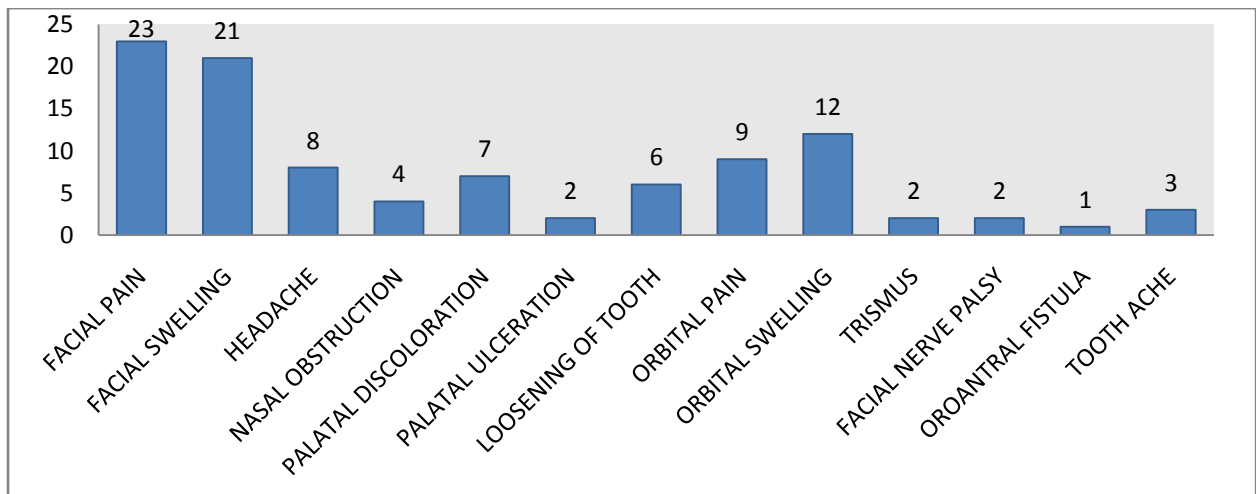
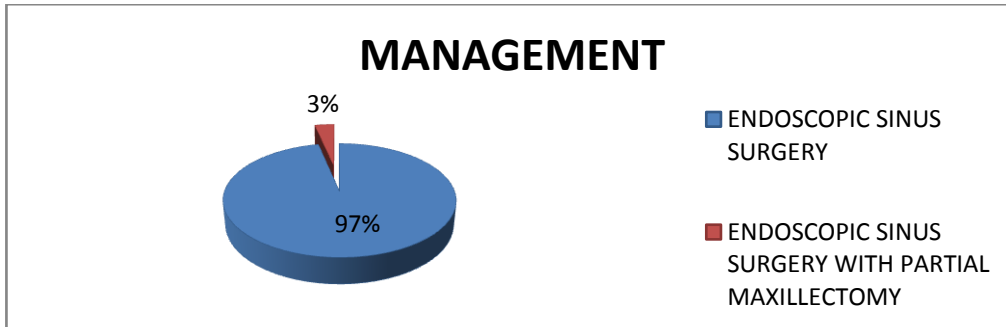


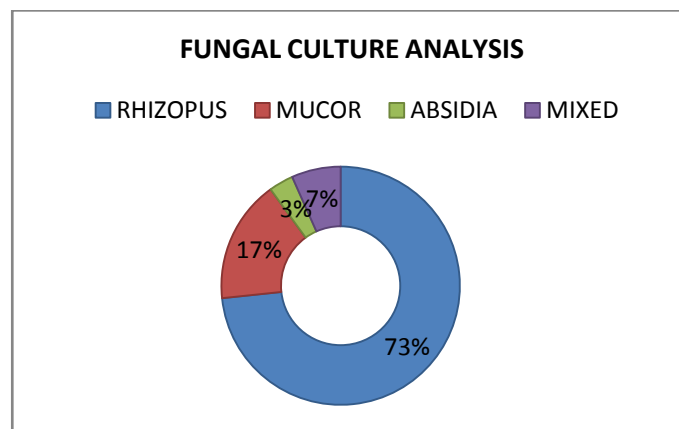
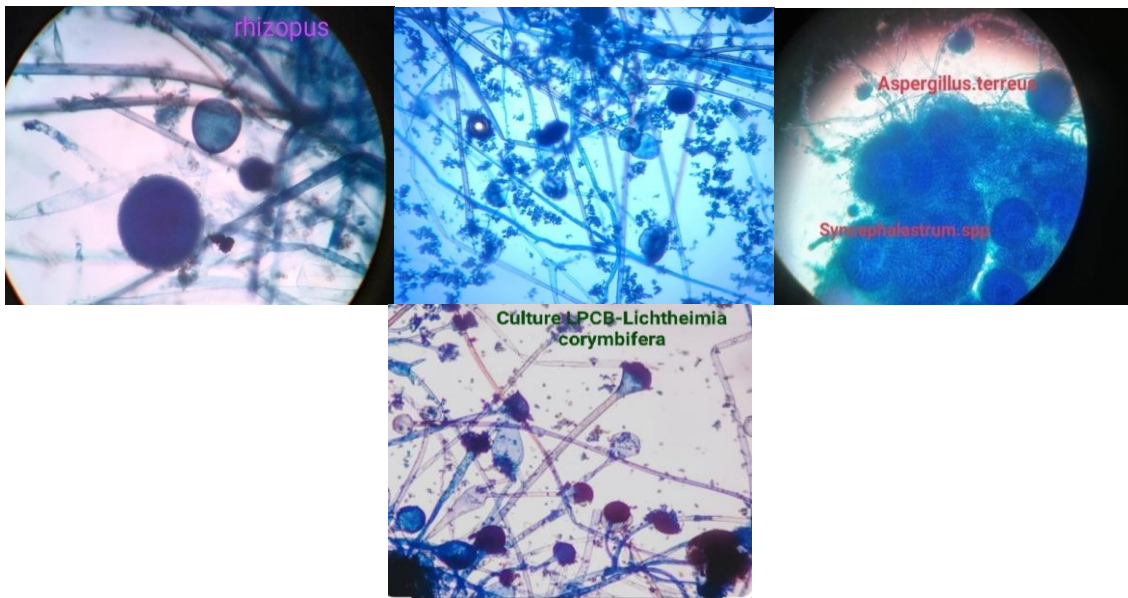
Table no 3 shows ; Out of 30 patients, 29 underwent endoscopic sinus surgery , and 1 underwent endoscopic sinus surgery with partial maxillectomy. All patients received antifungal treatments, including oral posaconazole and parenteral liposomal amphotericin-B. 11 patients with orbital involvement were also treated with retrobulbar injection of amphotericin and 3 patients with central nervous system involvement were referred to higher centre.

**TABLE NO 3 ; OUTCOME OF THE PATIENTS WHO WERE SURGICALLY INTERVENED AND NON INTERVENED**

OUTCOME	SURGICAL INTERVENTION DONE	NO SURGICAL INTERVENTION
TOTAL NUMBER OF PATIENTS	30	NIL
FULLY CURED	28	NIL
DEATH	2	NIL



On fungal culture, 22 patients were found to have rhizopus , 5 patients had mucor , 2 had mixed species, and 1 had absidia species.

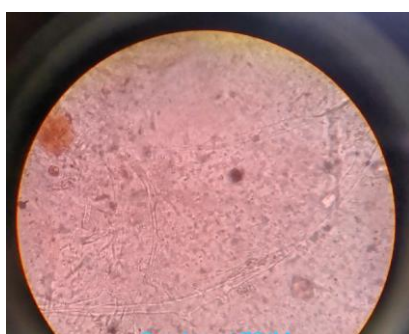


#### IV. Discussion

This condition is characterized by the presence of fungal tissue invasion and a granulomatous reaction with considerable fibrosis. Histological features include mycotic infiltration of blood vessels, vasculitis with thrombosis, tissue infarction, hemorrhage and acute neutrophilic infiltrate [4]. The inability to mount a host response to invasive fungal disease in immunocompromised patients can make the diagnosis of this disease entity difficult, especially in the early stages [6]. Although commonly reported clinical symptoms include fever, cough, crusting of nasal mucosa, epistaxis and headaches [4]. A high index of suspicion of this disease entity should be in any immunosuppressed patients with localizing sinonasal symptoms. Often, fever of unknown origin that has failed to respond to 48hrs of broad-spectrum intravenous antibiotics maybe the initial presenting

symptoms . In the early stages , nasoendoscopic finding maybe as subtle as the presenting symptoms. Alteration in mucosal appearance such as discoloration ,granulation and ulceration are the most consistent physical findings [7]. There are no pathognomic features for fungal rhinosinusitis on imaging and a CT Scan is the initial radiologic investigation of choice. Compared to Allergic fungal rhinosinusitis , invasive fungal rhinosinusitis tends to have more focal bony erosions , lacks expansion of the sinuses , has more limited sinus disease and has more disease outside of the sinuses than within when there is intra-orbital and intra-cranial extension [8]. Proptosis , enlarging mass in cheek,nose and paranasal sinuses are predominant symptoms in granulomatous variety [4] [6]. Species detection by looking for right-angled branching on broad aseptate hyphae in KOH mounts .Using lactophenol cotton blue, aseptate hyphae and sporangiospores can be visualized. The easiest way to visualise the hyphae in invaded tissues is to use Grocott-Gomori methenamine silver staining. It is possible to demonstrate pathological alterations in tissues using periodic acid-Schiff and hematoxylin and eosin stains, such as acute suppurative inflammation with focal foci of granulomatous inflammation and angioinvasion by hyphae with ensuing thrombosis and infarction .As alternatives to histochemistry, in situ hybridization and polymerase chain reaction for fungal DNA can be employed to diagnose tissues .

#### FUNGAL HYPHAL ELEMENTS ON KOH



Prior to definitive identification of the causative fungi , empirical treatment with intravenous amphotericin B , a broad-spectrum antifungal agent has been recommended [9]. The triazoles are effective in the treatment of invasive fungal rhinosinusitis without the associated nephrotoxicity which is seen in standard amphotericin B [6] [9].

#### V.Conclusion

Over the course of weeks or months, Invasive fungal sinusitis advances gradually. Clinical results are improved with early diagnosis and treatment. To control the disease, complete excision of diseased paranasal tissues is recommended; however, the treatment regimen may vary and be customised based on the extent of the disease, the patient's health, and other factors.

#### References

- [1]. Definitions of fungal rhinosinusitis. Ferguson BJ ; Otolaryngologic Clinics of North America, 01 Apr 2000, 33(2):227-235
- [2]. Fungal rhinosinusitis<sup>†</sup>; A categorization and definitional schema addressing current controversies Arunaloake Chakrabarti MD, David W. Denning FRCP, FRCPATH, Berrylin J. Ferguson MD
- [3]. An algorithmic approach to the diagnosis and management of invasive fungal rhinosinusitis in the immunocompromised patient ; BoydGillespieMD<sup>1</sup>Bert W.O'MalleyMD<sup>2</sup>
- [4]. Fungal Sinusitis ; Richard D. deShazo, M.D., Kimberle Chapin, M.D., and Ronnie E. Swain, M.D.
- [5]. Fungal disease of the nose and paranasal sinuses ; George R.ThompsonIIIIMD<sup>ab</sup>Thomas F.PattersonMD
- [6]. AnApproach to Fulminant Invasive Fungal Rhinosinusitis in the Immunocompromised Host M. Boyd Gillespie, MD; Bert W. O'Malley Jr, MD; Howard W. Francis, MD
- [7]. Imaging of granulomatous and chronic invasive fungal sinusitis: Comparison with allergic fungal sinusitis ; C. Ekambar Eshwara Reddy, FRCS, MSc, MS, Ashok K. Gupta, MS, , and Sher B. S. Mann, MS
- [8]. Agents for treatment of invasive fungal infections ; BeatrizLunaPharmD<sup>12</sup>Richard H.DrewPharmD, MS<sup>12</sup>John R.
- [9]. Chronic Invasive Fungal Rhinosinusitis in Immunocompetent Patients: A Retrospective Chart Review ; Naif H. Alotaibi,<sup>1,2,\*</sup> Omar Abu Omar,<sup>2</sup> Mays Altahan,<sup>2</sup> Haifa Alsheikh,<sup>2</sup> Fawziah Al Mana,<sup>2</sup> Zeyad Mahasin,<sup>1</sup> and Eyas Othman
- [10]. Mucormycosis in COVID-19: A systematic review of cases reported worldwide and in India; Awadhesh KumarSingh<sup>a</sup>RituSingh<sup>a</sup>Shashank R.Joshi<sup>b</sup>AnoopMisra.

Dr.B.Santhanakrishnakumar, et. al. "A Study of Zygomycotic Fungal Organisms Causing Invasive Sinusitis and Its Management in Covid Era." *IOSR Journal of Dental and Medical Sciences (IOSR-JDMS)*, 22(1), 2023, pp. 01-06.