

# **A Prospective Study To Compare Efficacy Of Local Corticosteroid And Platelet Rich Plasma Injection For Treatment Of Lateral Epicondylitis**

**DR.ARJUN ROY, DR.ANSHUMAN DUTTA, DR. VIKASH AGARWALA,  
DR. TRIDIP BHARALI, DR. VEERENDER DEV, DR. RAHUL ASHOK  
BHANGE**

**SILCHAR MEDICAL COLLEGE AND HOSPITAL**

---

Date of Submission: 27-04-2023

Date of Acceptance: 08-05-2023

---

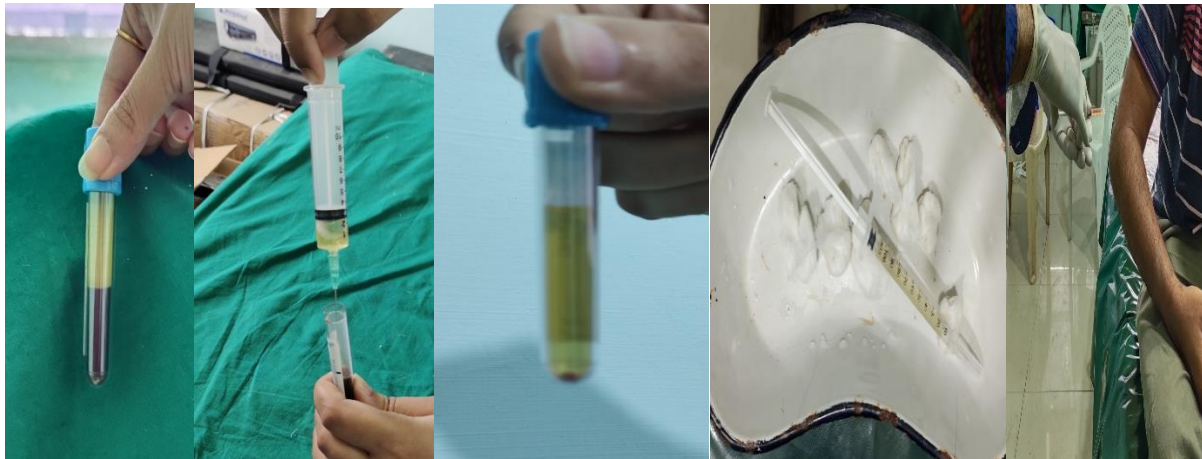## **I. INTRODUCTION**

Lateral epicondylitis, or “tennis elbow,” is a frequently diagnosed condition and a common cause of pain around elbow joint. The complaint is characterized by pain over the lateral epicondyle of the humerus, which is aggravated with resisted dorsiflexion of the wrist. The incidence is approximately 4 to 7 per 1000 patients per year. Lesion can be in common extensor tendon, extensor Carpi radialis brevis (ECRB), or radial collateral ligament but most commonly extensor Carpi radialis brevis (ECRB) is involved. Repeated tendon overuse leads to micro tear in tendon when stretch exceeds physiological limit of the tissue. There is ongoing inflammatory process besides change in complex tendon structure. Generation of pain may be due to irritation of mechanoreceptors by traction or shear forces or activation of nociceptive receptors. Several modalities of treatment have been developed which includes rest, nonsteroidal anti-inflammatory drugs, physical therapy, tennis elbow belt, corticosteroid injection, botulinum toxin injection, Extracorporeal shock wave and pulsed ultrasound. One of these treatments is injection of platelet-rich plasma (PRP) which is an autologous blood product enriched with biological factors responsible for tissue regeneration. Corticosteroid work as short-term measure by reducing the inflammation but it doesn't deal with the root cause of inflammation as PRP does. The use of platelets as vehicles for the delivery of growth factors in the form of platelet rich plasma (PRP) may be just the beginning of a new medical frontier known as “orthobiologics.” Since 1992 Platelet-rich plasma (PRP) is a new technology focused on enhancing the healing response after injury of different tissue types. Platelet rich plasma is defined as the plasma fraction of autologous blood having a platelet concentration above baseline. Study has shown clinical efficacy of PRP use with minimum concentration of platelets by four times as compare to autologous blood. As PRP is an autologous blood product, it is free of transmissible diseases and cannot cause hypersensitivity reactions. The healing properties of PRP have been attributed to the various biological growth factors like platelet derived growth factor (PDGF), vascular endothelial growth factor (VEGF), epidermal growth factor, hepatocyte growth factor (HGF) and insulin like growth factor-1. PRP is prepared through a platelet separation process, which results in an increased platelet concentration compared with the original whole blood sample. It is assumed that when PRP is injected into an area of tendinopathy, the platelets release a multitude of growth factors and stimulate a healing response and many investigators found increased collagen gene expression and increased production of VEGF and HGF in human tenocytes treated with PRP.

## **II. MATERIALS AND METHODS**

This randomized control trial for evaluating efficacy of platelet rich plasma vs. corticosteroid injection in treatment of Lateral Epicondylitis was conducted in Department of Orthopaedics. All patients of “chronic tennis elbow” with at least 6-month duration of symptoms who came to OPD of Department of Orthopaedics were included in the study. Total 60 diagnosed cases of tennis elbow on the basis of clinical examination who met the inclusion criteria were randomized into two groups (PRP and corticosteroid group). PRP preparation was done from 40 ml of autologous venous blood. Blood was centrifuged at two levels, first 1200 rpm for 10 minutes and second at 2000 rpm for 10 minutes. Patients are analyzed for pain using VAS score and functional assessment done using DASH score. Inclusion criteria: patients having age between 18 to 70 years and duration of symptoms at least 6 months. Exclusion criteria: Patients who did not give consent for the procedure, patients with tendon rupture, acute inflammatory disease, infectious disease, malignancy, history of autoimmune platelet disorder, history of consistent use of NSAIDs and systemic steroid use, anemic patients, patients having platelet count less than 150,000 per micro liter, diabetic and pregnant woman. 2 ml of PRP solution (diluted with plasma) injected

directly into the area of maximum tenderness using a 22-g needle into the common extensor tendon using a peppering technique. This technique involved a single skin portal and then 5 penetrations of the tendon. Patients in steroid group received 2 ml of methylprednisolone (40 mg/ml, inj). Immediately after the injection, the patients were kept in a supine position without moving the arm for 15 minutes. Patients were sent home with instructions to limit their use of the arm for approximately 24 hours and use acetaminophen for pain. A formal stretching and strengthening exercises of forearm muscles were initiated on 2nd day after injection. At 4 weeks after the procedure, patients are allowed to proceed with normal sporting or recreational activities as tolerated. The patients were assessed using Visual analogue scale (VAS), Disability assessment of Shoulder and Hand score (DASH) score before and after treatment at 2, 8 weeks and 3, 6 months.



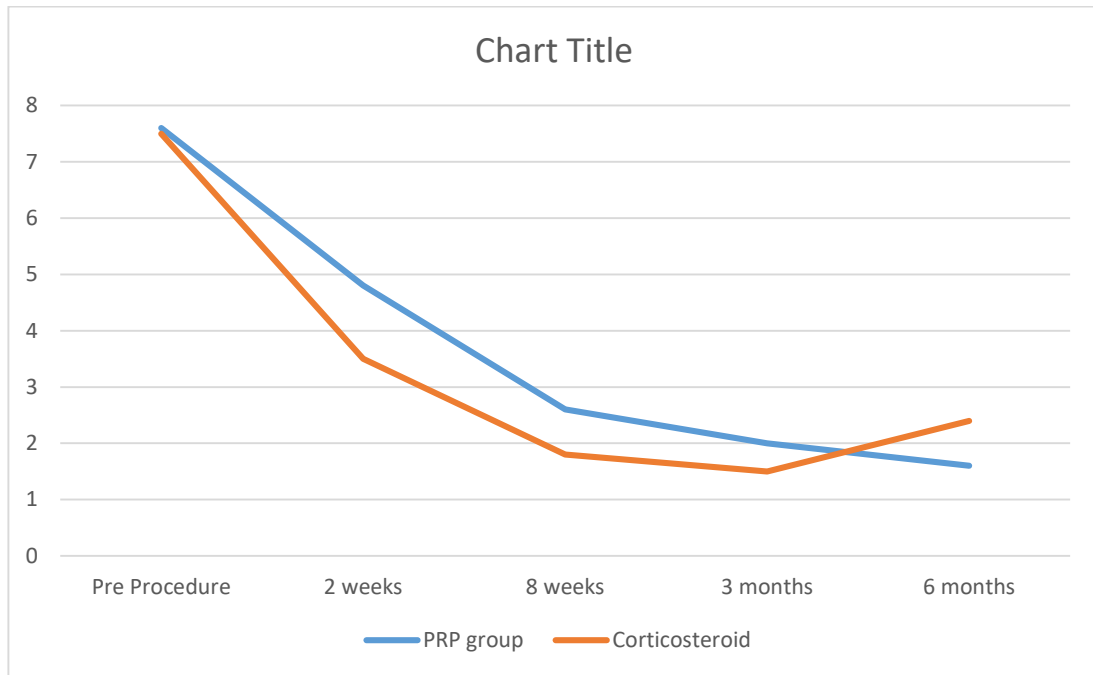
**EXTRACTION OF PRP FROM AUTOLOGOUS BLOOD AND INTRODUCTION TO SITE**

**III. RESULT**

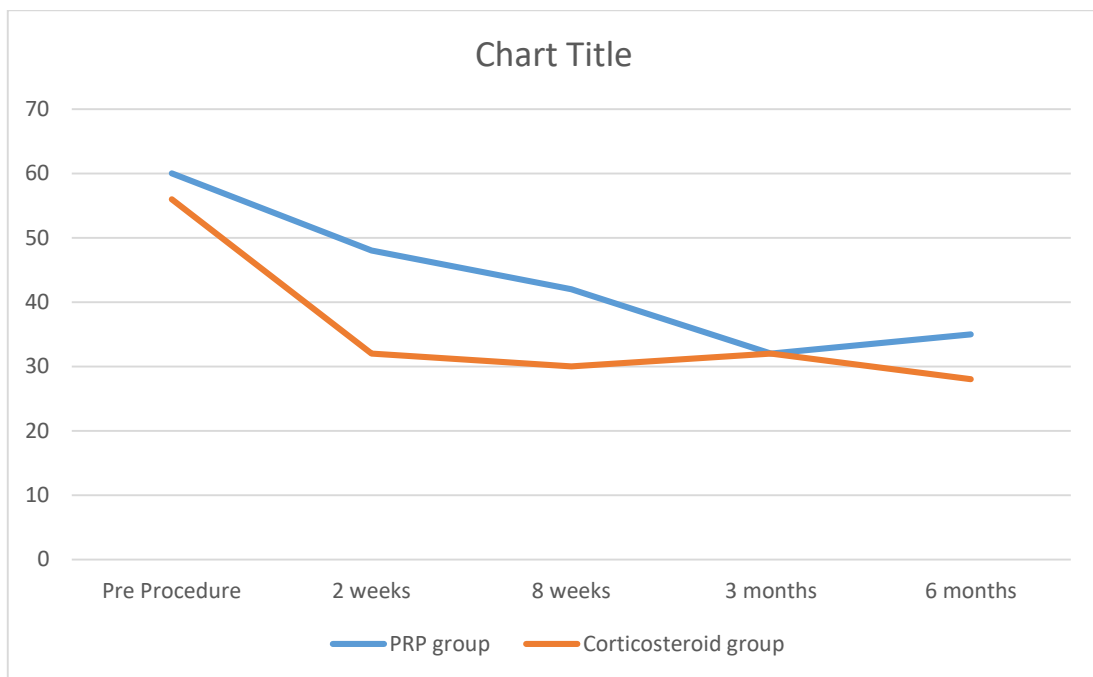
Total 60 patients were included in study (30 in each group), demographically both groups were similar (Table 1). Mean VAS Score (Figure 1) and DASH score (Figure 2) before treatment and at each follow-up were compared (total 5 mean and 2 groups). There was statistically significant difference between both groups in all 5 means except at 2nd and 3rd mean (2, 8 weeks respectively).

Age(years)	PRP GROUP	CORTICOSTEROID GROUP	TOTAL
21-24	1	0	1
25-29	1	2	3
30-34	7	8	15
35-39	14	12	26
40-44	5	4	9
45-50	2	4	6
51-54	0	0	0
55-60	0	0	0
<b>TOTAL</b>	<b>30</b>	<b>30</b>	<b>60</b>

**TABLE 1 DEMOGRAPHIC DATA OF BOTH GROUPS**



**MEAN VAS SCORE: PRP VS CORTICOSTEROID GROUP**



**MEAN DASH SCORE: PRP VS CORTICOSTEROID GROUP**

#### IV. DISCUSSION

This Randomized single blind study was designed and conducted to compare the use of autologous PRP to Local corticosteroid in patients with lateral epicondylitis. Lateral epicondylitis is one of the most perplexing disorder of musculoskeletal system with many possible options of treatment. Most common etiological factors are repeated dorsiflexion or pronation and supination movements. The number of overuse injuries is not exactly known, but in sports medicine, they account for 30 to 50% of all injuries . Studies have shown that people who have worked for 25 to 35 years are more likely to develop tendinopathy . In our study maximum patients were in fourth decade. The mean age group was 36.5 and 38.3 years in PRP and Corticosteroid group respectively. Nirschl RP et al in their study found tennis elbow predominance in fourth and fifth decade . In our study female predominance was present 60 % and 66 % in PRP and corticosteroid group respectively. Karen Walker-Bone et al in their study on occupation and epicondylitis found mean age 45.6 years (range 24.6 - 66.3 years) with 55 %

of subjects being female who are involved in repetitive forearm movements . Nirschl et al found mainly fibro-elastic tissue and vascular invasion describing this condition as “angiofibroblastic tendinosis” . The corticosteroid group was improved progressively & than declined while PRP group got progressively improved. After 6 months of follow up the effect in PRP group was maintained and declined in Corticosteroid group. This concludes that PRP is more helpful in treating lateral epicondylitis. Corticosteroid injection which was gold standard treatment for lateral epicondylitis, is considered controversial now a days because studies have proved that it offers only short-term relief as compare to physiotherapy and wait and watch policy . Often results are poor after 3 months of follow-up. Occurrence of relapse probably because steroid leads to permanent changes within microstructure of tendon as patient has tendency to overuse the arm after injection as a result of direct pain relief . Platelet rich plasma is an ideal biologic product in which patients own platelets are collected into a highly concentrated form. Platelets release more than 95% of the presynthesized growth factors within one hour of activation. This initial burst is followed by steady synthesis and secretion of growth factors for their remaining life span . No activation agent was used during our procedure, as platelets get activated in vivo when exposed to thrombin which in turn produced in response to injection of platelets using a peppering technique and exposed collagen also acts as a natural activator of platelets . There is concern regarding use of bovine thrombin as activator, being an exogenous substance, it can produce detrimental effects and collagen is naturally involved in clotting cascade and is attractive alternative to bovine thrombin. Use of leukocyte rich or leukocyte depleted PRP is a topic of debate, presence of leukocyte in PRP augments its antibacterial activity and have ability to debride the tendon and start healing (as leukocytes also contains growth factors). Presence of matrix metalloproteinase (released from neutrophils) have detrimental effects on tissue healing but this fact needs to be proved by Randomized control trials. Injection of autologous Platelets has been shown to improve repair in tendinosis in animal studies . Effect of single injection PRP last for 1 year whereas percentage of success rate for corticosteroid injection drops from 51 % to 40 % after 2 years of follow-up . As far as relief of pain is concerned corticosteroid offer better short-term relief as compare to longer term relief offered by PRP injection. Same clinical efficacy is seen with respect to improvement of function assessed by DASH scores. Improvement in DASH Scores were better in corticosteroid group for short term and for longer term in PRP group and these results are consistent with other studies .

## V. CONCLUSION

In treatment of lateral epicondylitis local injection of corticosteroid gives better but short-term pain relief where as local PRP injection offers reasonable and long-term pain relief with no recurrence of symptoms and better functional outcomes. However, a long-term follow-up study with large sample size is advocated to substantiate these findings.

## REFERENCE

- [1]. Cyriax JH. The pathology and treatment of tennis elbow. *J Bone and Joint Surg* 1936 Oct;18(4):921-940.
- [2]. Scott A, Khan KM, Roberts CR, Cook JL, Duronio V. What do we mean by the term “inflammation”? A contemporary basic science update for sports medicine. *Br J Sports Med* 2004 Jun 1; 38(3):372-380.
- [3]. Emilio Lopez Vidriero, Krista A. Goulding, David A. Simon, Mikel Sanchez and Donald H. Johnson. The Use of Platelet-Rich Plasma in Arthroscopy and Sports Medicine: Optimizing the Healing Environment. *The Journal of Arthroscopic and Related Surgery* 2010; Vol 26, No 2 (February): 269-278.
- [4]. Anitua E, Andia I, Sanchez M, Azofra J, del Mar Zaldueño M, de la Fuente M, Nurden P, Nurden AT. Autologous preparations rich in growth factors promote proliferation and induce VEGF and HGF production by human tendon cells in culture. *J Orthop Res* 2005 Mar;23(2):281-286.
- [5]. De Mos M, van Windt AE, Jahr H, van Schie HT, Weinans H, Verhaar JA, Van Osch GJ. Can platelet rich plasma enhance tendon repair: a cell culture study. *Am J Sports Med* 2008 Jun;36(6):1171-1178.

DR.ARJUN ROY, et. al. “A Prospective Study To Compare Efficacy Of Local Corticosteroid And Platelet Rich Plasma Injection For Treatment Of Lateral Epicondylitis.” *IOSR Journal of Dental and Medical Sciences (IOSR-JDMS)* 22(5), 2023, pp. 15-18.