

## **A Case Of Unilateral Isolated Lens Coloboma**

Dr. Nisha Ahuja, Dr. Rashi Kochar

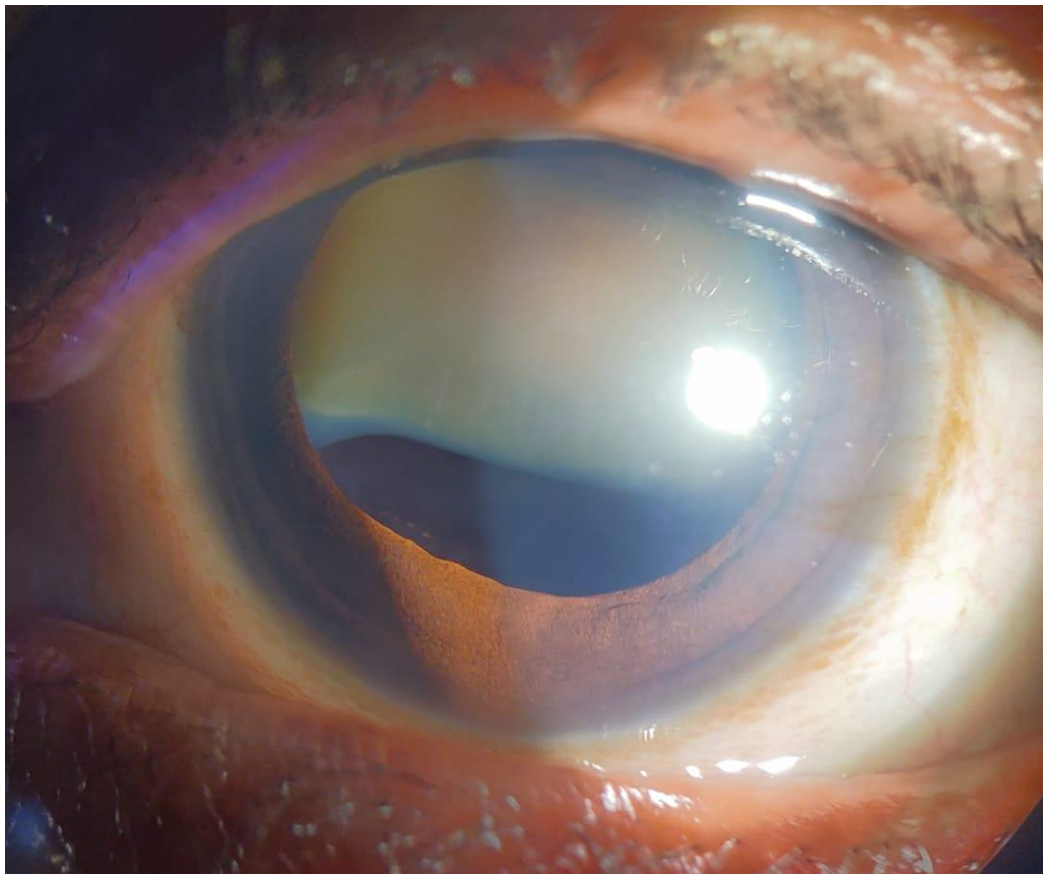
---

Date of Submission: 11-05-2023

Date of Acceptance: 21-05-2023

---

A 63-year-old female presented with gradually progressive diminution of vision in the left eye for 6 months. On ocular examination, the unaided visual acuity in the right eye (RE) was 6/36 and Hand movements with perception of light in the left eye (LE). On dilated slit-lamp examination, RE was pseudophakic and LE had mature senile cataract with inferior lens coloboma. The iris morphology in both eyes was normal with no clinically appreciable iridodonesis or phacodonesis. B scan had no evidence of coloboma, and also no significant findings were found on systemic examination.



**Figure 1 shows mature senile cataract with inferior lens coloboma of the left eye extending from 4 to 8 o'clock hours, with absent zonules leading to flat lens margin**