

Variations In The Course And Branching Of Musculocutaneous Nerve

Subhalakshmi Wahengbam^{1*}, Laishram Biswanath Singh²,

Kalpana Thounaojam³, Joyce Tunglut⁴, Gurumayum Tarunkumar Sharma⁵

^{1*}Professor, ²postgraduate Trainee, ³associate Professor, ⁴demonstrator, Department Of Anatomy, Jawaharlal Nehru Institute Of Medical Sciences (Jnims), Imphal, Manipur, India.

⁵assistant Professor, Department Of Anatomy, Regional Institute Of Medical Sciences (Rims), Imphal, Manipur, India.

Abstract

Background: The musculocutaneous nerve (C5, 6, 7) is one of the terminal branches of the lateral cord of brachial plexus. It pierces coracobrachialis a variable distance below the tip of the coracoid process and then descends laterally between biceps brachii and brachialis to the lateral side of the arm. It supplies coracobrachialis, both heads of biceps brachii and most of brachialis, and continues as the lateral cutaneous nerve of forearm, running down the lateral aspect of the forearm. The musculocutaneous nerve has frequent variations. The present study was carried out to observe the variations in the course and branching of the musculocutaneous nerve in Indian population.

Materials: The musculocutaneous nerve was studied on the upper limbs of 60 adult cadavers.

Result: Variations in the musculocutaneous nerve were present in 10 upper limbs. In 9 cases, the nerve did not pierce coracobrachialis muscle and among which 5 also supplied an additional 3rd head of biceps brachii. 3 cases had a communicating branch given out from musculocutaneous nerve to median nerve and one case had the musculocutaneous nerve adherent to the median nerve. There were 3 cases where the musculocutaneous nerve did not give rise to the nerve to coracobrachialis, which instead came from lateral cord of the brachial plexus directly, in two of these, the musculocutaneous nerve also did not pierce the coracobrachialis while in the third it pierced the muscle.

Conclusion: The knowledge of variations of musculocutaneous nerve is important to avoid damage to this important nerve while performing surgery around the axilla, shoulder and upper arm and to prevent untoward outcomes of surgeries conducted on the musculocutaneous nerve itself and also in interpretation and diagnosis of a nerve compression having unexplained clinical symptoms.

Keywords: musculocutaneous nerve, median nerve, coracobrachialis, biceps brachii, brachialis

Date of Submission: 21-04-2024

Date of Acceptance: 01-05-2024

I. Introduction

The musculocutaneous nerve arises from the lateral cord (fifth, sixth and seventh cervical ventral rami) of the brachial plexus, opposite the lower border of pectoralis minor. It pierces coracobrachialis a variable distance below the tip of the coracoid process and then descends laterally between biceps brachii and brachialis to the lateral side of the arm. The first branch, to coracobrachialis, may pass into the muscle no more than 2 cm distal to the tip of the coracoid. Branches to biceps brachii and brachialis leave after the musculocutaneous nerve has pierced coracobrachialis. There are usually two branches to brachialis; the lower branch also supplies the anterior aspect of the elbow joint. The nerve inclines lateral and deep, into the plane between brachialis posteriorly and biceps anteriorly, where it supplies a small branch to the humerus that enters the shaft with the nutrient artery. Below the branches to brachialis, the musculocutaneous nerve continues as the lateral cutaneous nerve of the forearm [1]. The musculocutaneous nerve has frequent variations which is important from both academic as well as clinical points of view. Thus, the present study was carried out to observe the variations of the musculocutaneous nerve in Indian population and thus to contribute to the existing knowledge on it.

II. Materials And Methods

The present study was carried out on the upper limbs of 60 Indian cadavers during routine dissection classes in the Department of Anatomy, JNIMS, Imphal from 2010-2022. The musculocutaneous nerve was traced from its origin till it emerged lateral to the bicipital tendon as lateral cutaneous of the forearm. Its course,

relation with coracobrachialis, different branches and any communications with the neighbouring nerves, if any, were observed and noted. Photographs were taken for proper documentation.

III. Result

Variations of the musculocutaneous nerve were present in 10 upper limbs (8.3%), 3 on the right side and 7 on the left side. In 9 cases (3 right and 6 left), the nerve did not pierce coracobrachialis muscle (Fig.1a, 1b, 1c, 1d, Fig.2a, 2b, 2c, 2d and Fig.3), in 5 of these upper limbs (1 right and 4 left) it also supplied an additional 3rd head of biceps brachii (Fig.1a,1b,1c,1d and Fig.3); 3 cases (2 left and 1 right) had a communicating branch from musculocutaneous nerve to median nerve (Fig.1c, 1d and Fig.2c) and in one left upper limb, the musculocutaneous nerve was adherent to the median nerve (Fig.3). In 3 left upper limbs, the musculocutaneous nerve did not give rise to the nerve to coracobrachialis, which instead came from lateral cord of the brachial plexus directly, in two of these, the musculocutaneous nerve also did not pierce the coracobrachialis (Fig. 2a and Fig. 3) while in the third it pierced the muscle (Fig. 4).

IV. Discussion

Variations of musculocutaneous nerve may occur in 6.25% cases [2] however, the present study found a higher percentage of variations of musculocutaneous nerve at 8.3%. There are many previous reports of the cases where musculocutaneous nerve did not pierce the coracobrachialis [3-7]. Nakatani et al [8] reported three cases where the musculocutaneous nerve did not penetrate the coracobrachialis but was contained in a common sheath along with lateral cord of brachial plexus and median nerve. Rao and Rao [9] reported 28 cases, found among 300 cases (9.3%) in which the musculocutaneous nerve did not pierce the coracobrachialis but instead passed between it and biceps. In the present study, we found that the musculocutaneous nerve did not pierce coracobrachialis muscle but instead passed either medial or anterior to it in 9 cases (7.5 %) among the 120 upper limbs studied, out of which 3 cases (2.5%) were on the right side and 6 cases (5%) on the left side. Therefore, the musculocutaneous nerve did not pierce the coracobrachialis in 5% of the right limbs and 10% of the left limbs studied.

The musculocutaneous nerve may adhere for some distance to the median nerve and pass behind biceps brachii [1]. In the present study also, there was one case (Fig.3) where the musculocutaneous nerve was adherent to the median in the upper part and sprang out from the median nerve like a branch beyond the axilla in the upper arm. The musculocutaneous nerve supplied the third head of biceps brachii in all the 5 cases where an additional third head of biceps brachii was present and this finding agrees with the previous reports that the third of biceps brachii is innervated by musculocutaneous nerve [10-13].

Communication between median nerve and musculocutaneous nerve had been reported by many authors [2,5-7,14]. If the lateral root of median nerve is small, the musculocutaneous nerve (fifth, sixth and seventh cervical ventral rami) connects with the median nerve in the arm [1]. The primary ventral branches of the spinal nerves that form the musculocutaneous nerve and lateral root of median nerve are common to these nerves (C5 to C7). This common origin of the median nerve and musculocutaneous nerve explains the frequent presence of communicating branch between the two nerves, which are in up to one third of all individuals [15]. Choi et al [16] classified the communication between the musculocutaneous nerve and the median nerve based on a study on 138 cadavers as follows:

Pattern 1: fusion of both nerves (19.2%)

Pattern 2: presence of one supplementary branch between both nerves (72.6%)

Pattern 2a: single root from musculocutaneous nerve, contributes to the connection (69.9%)

Pattern 2b: there are two roots from the musculocutaneous nerve (2.7%)

Pattern 3: presence of two branches between both nerves (6.8%).

In the present study, a communicating branch was given out from musculocutaneous nerve to median nerve in 3 cases (Fig.1c,1d and Fig. 2c) which is similar to Pattern 2a of Choi et al [16] and in one case (Fig.3), the musculocutaneous nerve was adherent to the median nerve as if there was fusion of both nerves as in Pattern 1 of Choi et al [16].

Knowledge of communicating branches between musculocutaneous nerve and median nerve may prove valuable in traumatology of shoulder joint and /or upper arm as well as in relation to surgeries requiring tracing of median nerve and / or musculocutaneous nerve distally [15]. Leffert [17] stressed upon the fact that such communications should definitely be ruled out to prevent unwanted outcomes of operations conducted on musculocutaneous nerve. The knowledge of anatomical variations is of more importance during flap dissections and post traumatic evaluation of the arm after repairing peripheral nerve. After trauma to the arm, when the median nerve seems to be surgically intact, the fibres coursing in the musculocutaneous nerve may be damaged [7]. Sunderland [18] opined that the lesions of communicating nerve may give rise to pattern of weakness that may impose difficulty in diagnosis. An injury to musculocutaneous nerve proximal to the anastomotic branch may lead to unexpected presentation of weakness of the forearm flexors and thenar muscles. The untoward

outcomes of surgery and unusual pattern of weakness might have been there in those three cases of the present study (Fig.1c, 1d and Fig.2c) where there was a communicating branch between the musculocutaneous nerve and the median nerve and in that one case where the two nerves were adherent to each other (Fig.3).

Musculocutaneous nerve usually supplies the coracobrachialis by its first branch which may pass into the muscle no more than 2 cm distal to the tip of the coracoid but the muscle may be innervated by its own nerve, fibres from C7 branch directly from the lateral cord of the brachial plexus [1]. Linnel [19] found the nerve or nerves to coracobrachialis arising from the lateral cord rather than from the musculocutaneous nerve in 4 of 26 dissections. Kerr [20] reported an origin of the nerve from musculocutaneous nerve alone in only 49.4% of 109 limbs while in the remainder it was from the lateral cord, lateral root of median nerve or 7th cervical ventral ramus directly. There has been report of a case of dual innervation of coracobrachialis by a branch from the lateral cord of the brachial plexus and another branch from musculocutaneous nerve which also did not pierce the coracobrachialis [4]. Gumusalan [3] reported a case where the musculocutaneous nerve was coursing downwards medial to coracobrachialis without piercing it and was associated with innervation of the muscle by a nerve branch from the lateral root of the median nerve but not from either the musculocutaneous nerve or the lateral cord of brachial plexus. In the present study, there were 3 left upper limbs where the musculocutaneous did not give a branch to coracobrachialis, instead the nerve to the muscle came directly from lateral cord of brachial plexus, in two of these cases (Fig. 2a and Fig. 3), the musculocutaneous nerve also did not pierce the coracobrachialis while in one of these cases, it pierced the muscle (Fig. 4).

V. Conclusion

The musculocutaneous nerve has frequent variations in its course and branching. The nerve is liable to injury in those cases where it did not pierce coracobrachialis muscle due its more superficial course either anterior or medial to the muscle while performing surgery around the axilla, shoulder and upper arm. Thus, knowledge of these variations of musculocutaneous nerve is important to avoid damage to this important nerve. In those cases where there is a communicating branch between the median nerve and the musculocutaneous nerve, injury or compression of either of these two nerves may be associated with difficulty in interpretation and diagnosis of unexplained clinical symptoms due to involvement of fibres of other nerve. While, on the other hand, in cases of musculocutaneous nerve compression or injury, the coracobrachialis muscle will be spared if it receives its nerve supply directly from lateral cord, not as a branch of the musculocutaneous nerve. Thus, the knowledge of the variations in the course and branching of musculocutaneous nerve is important from both academic as well as clinical point of view.

References

- [1] Alistair Ross. Shoulder Girdle And Arm. In Gray's Anatomy. The Anatomical Basis Of Clinical Practice. 42nd Edition. Edited By Standring S: Elsevier; 2021:830-929.
- [2] Bhattarai C, Poudel PP. Unusual Variation In Musculocutaneous Nerves. Kathmandu Univ Med J 2009;7:408-410.
- [3] Gumusalan, Yazar F, Ozan H. Variant Innervation Of The Coracobrachialis Muscle And Unusual Course Of Musculocutaneous Nerve In Man. Kaibogaku Zasshi 1998;73(3):269-272.
- [4] Subhalakshmi W, Roy S, Kaini A, Devi AJ, Singh NS. Unusual Course Of Musculocutaneous Nerve Associated With Dual Innervation Of The Coracobrachialis. Ind Med J 2006;100(3):105-106.
- [5] Subhalakshmi W, Sharma HP, Chakaraborty D. Unilateral Abnormal Course Of Musculocutaneous Nerve With Bilateral Communication Between The Musculocutaneous And The Median Nerves. Ind Med J 2010;104(2):59-61.
- [6] Patil GV, Shishirkumar. Musculocutaneous Nerve Not Piercing The Coracobrachialis Muscle And Also Having Communication With Median Nerve – A Case Report. Int J Sci Res 2014;3(7):26-27.
- [7] Chitra PS, Shobana M. Anatomical Study Of Variations Of Musculocutaneous Nerve. Nat J Clin Anat 2016;5(3):143-147.
- [8] Nakatani T, Mizukami S, Tanaka S: Three Cases Of Musculocutaneous Nerve Not Perforating The Coracobrachialis Muscle. Kaibogaku Zasshi 1997;72(3):191-194.
- [9] Rao GRKH, Rao VR. Musculocutaneous Nerve Of The Arm. J Ant Soc India 1955:4:48.
- [10] Ashraf YN, Adel MH. Morphology And Clinical Implication Of The Extra-Head Of Biceps Brachii Muscle. Folia Morphol 2013;72(4):349-356.
- [11] Cheema P, Singla R. Lower Incidence Of The Third Head Of Biceps Brachii In North Indian Population. J Clin Diagnostic Res 2011;5(Suppl.2):1323-1326.
- [12] Amar J, Elezy MN. Study Of Variations In The Origin Of Biceps Brachii Muscle In Kerala. Int J Sci Res 2012;2:1-4.
- [13] Subhalakshmi W, Renuka K, Kalpana T, Elizabeth R. Incidence Of Third Head Of Biceps Brachii In Indian Population. Int J Anat Res 2015;3(4):1466-1470.
- [14] Chauhan R, Roy TS. Communication Between Median Nerve And Musculocutaneous Nerve . A Case Report. J Anat Soc India 2002;51:72-75.
- [15] Rao PPV, Chaudhury SC. Communication Of The Musculocutaneous Nerve With The Median Nerve. East Afr Med J 2000;77:498-503
- [16] Choi D, Rodriguez-Niendenfurh M, Varquez T, Parkin I, Sanudo JR. Pattern Of Connections Between The Musculocutaneous Nerve And Median Nerves In The Axilla And Arm. Clin Anat 2002;15:11-17.
- [17] Leffert RD. Anatomy Of Brachial Plexus. In Brachial Plexus Injuries. New York. Churchill Livingstone;1985:384.
- [18] Sunderland S. Nerves And Nerve Injury. In The Median Nerve: Anatomical And Physiological Features, 2nd Edition Edinburg; Churchill Livingstone;1978:691-727.
- [19] Linnel EA. The Distribution Of Nerves In The Upper Limb With Reference To Variabilities And Their Clinical Significance. J Anat 1921;55:79-112.



Fig 1: Photograph Of The Axilla And The Arm Showing Musculocutaneous Nerve Not Piercing The Coracobrachialis Muscle And Supplying An Additional Third Head Of Biceps Brachii. Fig. 1c And 1d Also Show The Presence Of A Communicating Branch Between The Musculocutaneous Nerve And Median Nerve. [Fig.1a Is Right Side; Fig.1b, 1c And 1d Are Left Side]



Fig 2: Photograph Of The Axilla And The Arm Showing Musculocutaneous Nerve Not Piercing The Coracobrachialis Muscle. Fig. 2a Also Shows That The Nerve To Coracobrachialis Arises Directly From Lateral Cord Of Brachial Plexus, Not As A Branch Of Musculocutaneous Nerve. Fig. 2c Also Shows The Presence Of A Communicating Branch Between The Musculocutaneous Nerve And Median Nerve. [Fig. 2a And 2b Are Left Side; Fig. 2c And 2d Are Right Side).




Fig 3: Photograph Of Left Axilla And Arm Showing Musculocutaneous Nerve Not Piercing The Coracobrachialis Muscle. The Nerve Supplies An Additional Third Head Of Biceps Brachii But Does Not Supply Coracobrachialis Muscle Which Is Supplied By A Branch From Lateral Cord Of The Brachial Plexus And The Nerve Is Also Adherent To The Median Nerve.

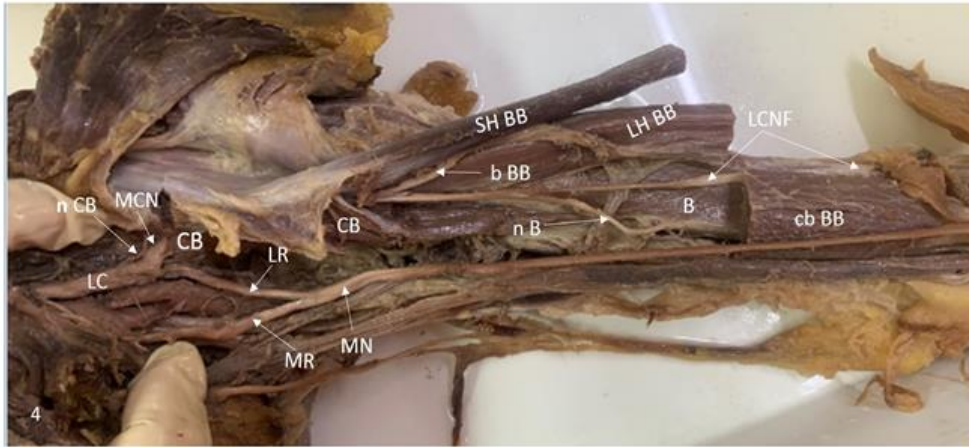


Fig 4: Photograph Of Left Axilla And Arm Showing Musculocutaneous Nerve Not Giving A Branch To The Coracobrachialis Muscle Which Is Supplied By A Branch Arising Directly From The Lateral Cord Of Brachial Plexus.

Legends to figures:

LC-Lateral Cord of brachial plexus, MC-Medial Cord of brachial plexus, MCN-Musculocutaneous nerve, LR-Lateral Root of Median nerve, MR-Medial Root of Median nerve, MN-Median Nerve, CB-Coracobrachialis, n CB-nerve to Coracobrachialis, b BB-branch to Biceps Brachii, SH BB-Short head of Biceps Brachii, n SH BB-nerve to Short head of Biceps Brachii, LH BB-Long Head of Biceps Brachii, n LH BB-nerve to Long Head of Biceps Brachii, cb BB-common belly of Biceps Brachii, Bt-Bicipital tendon, 3rd H BB-3rd Head of Biceps Brachii, n 3rd LH BB-nerve to 3rd Head of Biceps Brachii, B-Brachialis, n B-nerve to Brachialis, LCNF-Lateral Cutaneous Nerve of Forearm