

Retrospective Analysis Of Oral Lesions In Vellore From 2019-2023

Parasuraman Varalakshmi Mds¹, Vanmathi Vasanthkumar Mds¹
Department Of Oral & Maxillofacial Surgery, Government Vellore Medical College & Hospital, Vellore

Abstract

Aim

To determine the prevalence of hard and soft tissue lesions biopsied in the Department of Oral maxillofacial surgery at the Government Vellore Medical College and hospital.

Study design

A retrospective descriptive study was made with the biopsies and surgery performed between 2019 and 2023. From total of 292 samples, 257 were included in the study. The data with missing reports were excluded from the study. The following variables were recorded: age, sex, location of the lesion, biopsy technique, and histological results obtained using SPSS software.

Result

A total of 257 lesions subjected to histological study were analysed. The most frequent biopsied lesions were squamous cell carcinoma, followed by fibroma, mucocele, pyogenic granuloma, and lichen planus.

Conclusions

Being a tertiary centre, the most prevalent hard and soft tissue lesions were squamous cell carcinoma. The next most frequent were cysts in hard tissue, fibroma and mucocele in soft tissue, respectively.

Keywords: oral lesions, biopsy, hard tissue lesion, soft tissue lesions.

Date of Submission: 03-06-2024

Date of Acceptance: 13-06-2024

I. Introduction

The stratified squamous epithelium that lines the oral cavity with underlying mesenchymal tissue. The oral disease can manifest itself in different ways. Benign and malignant neoplasms may originate from any of these tissues. Usually, epithelial origin lesions are red or white in colour. Hyperplasia of the epithelium and build-up of keratin form a white lesion, but epithelial atrophy allows more sight of the underlying vasculature, which leads to a red appearance. Ulceration is the term for the disruption of epithelial integrity. Exuberant tissue proliferation may follow, resulting in a papillary or verruciform appearance[1].

Histopathological studies play a vital role in facilitating treatment strategies with proper documentation and confirming the definitive clinical diagnosis[2]. The aim of this study was to determine the prevalence of oral lesions in and around Vellore by evaluating the biopsy record of the department of oral and maxillofacial surgery in the Government Vellore medical college and hospital.

II. Materials & Methods

A descriptive retrospective study was carried out with histopathological reports obtained during the surgeries and biopsies that were performed during five years between 2019 and 2023 from the Department of oral and maxillofacial surgery in the Government Vellore Medical College and Hospital. The samples were submitted in 10% formalin solution with the corresponding registry form.

Inclusion criteria: The study included all the patients reported with oral lesions and biopsied in the department of oral and maxillofacial surgery from 2019 to 2023. Patients with age group 10 to 90 years were included in the study.

Exclusion criteria : The reports with missing information such as age, gender, and without definite histopathological diagnosis due to inappropriate biopsied sample or lack of adequate clinical data were excluded from the study.

Method : A total of 292 samples were tested for histopathology from 2019 to 2023. After exclusion criteria, 257 were included in the study. From each of the clinical histories, the following data were obtained: patient demographic data (age and sex), clinical manifestation, location of the lesion, biopsy technique used, and histopathology result. The patients were divided by age to evaluate the distribution of the lesions. The anatomical sites were divide into hard (maxilla and mandible) and soft tissue lesions (lips, buccal mucosa, alveolar mucosa,

palate, tongue, floor of the mouth). The data obtained were subjected to a descriptive statistical analysis using the SPSS software version 29.0.2.0 (20).

III. Result:

In this retrospective study, 257 lesions were reviewed. The mean age of the patient was 48 years (SD 18.1, range: 5–85 years). There was a slight male preponderance (female: 118; male: 139)(Figure1) . The highest frequency of the disease was between the ages of 60 and 69(Table -1). Most of the biopsy performed was an incisional biopsy, 57.6 %(148), while 42.4% (109) was an excisional biopsy(Figure 2). The most common affected areas were the buccal mucosa (30.4%), tongue (21%), and lip (12%) in soft tissue (77%) (Figure 3, Table 2 & 3). The most frequent hard tissue lesion (23%) was cystic (8.6%) in nature. The most common were radicular/periapical cysts (3.5%), followed by dentigerous cysts (2.3%) and odontogenic keratocysts (1.6%). Ameloblastoma constituted 2.3% of the lesions in the hard tissue. The most prevalent malignant neoplasm was squamous cell carcinoma (37.4%). In soft tissue, the next most frequently recorded lesion was fibroma (14.4%), lichen planus (8.2%), and mucocele (6.6%) (Table 4).

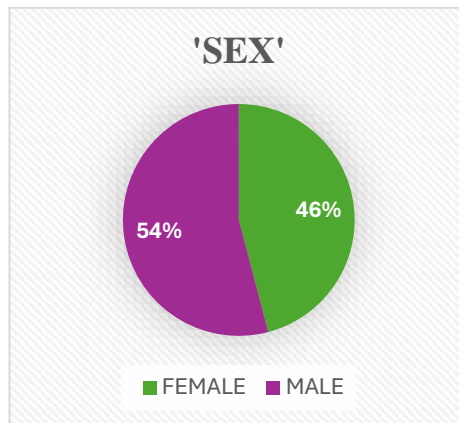


Figure - 1 – Sex distribution

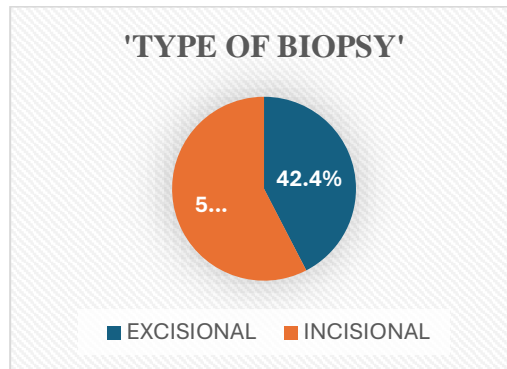


Figure – 2 Type of biopsy distribution

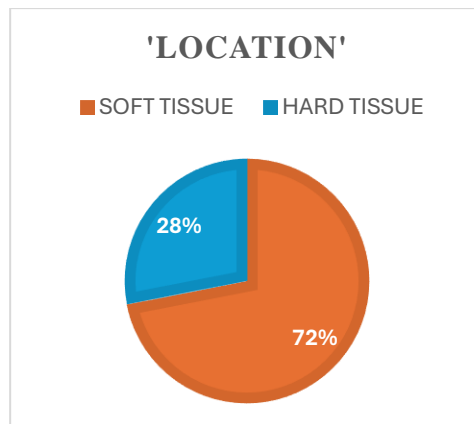


Figure - 3 – Location of lesion

TABLE 1 - AGE DISTRIBUTION

AGE	Number of cases	Percentage
10-19	22	8.6
20 - 29	21	8.2
30- 39	37	14.4
40-49	52	20.2
50-59	40	15.6
60-69	57	22.2
70-79	19	7.4
80-89	9	3.5

TABLE 2- DISTRIBUTION OF SOFT TISSUE LESION

Location	Number of cases	Percentage
Soft tissue	198	76.7
Lips	33	12.8
Buccal mucosa	78	30.4
Alveolar mucosa	23	9
Palate	4	1.2
Tongue	54	21
Floor of the mouth	6	2.3

TABLE 3 – DISTRIBUTION OF HARD TISSUE LESION

Location	Number of cases	Percentage
Hard tissue	59	23.3
Maxilla	22	9
Mandible	37	14.3

TABLE 4 - ORAL LESIONS RECORDED

Oral lesions	Number of cases	Percent
Squamous cell carcinoma	96	37.4
Actinic keratitis	2	0.8
Epithelial hyperplasia	7	2.7
Hyperkeratosis	4	1.6
Fibroma	37	14.4
Pyogenic granuloma	15	5.8
Lichen planus	21	8.2
Pemphigus	2	0.8
Mucocele	17	6.6
Haemangioma	3	1.2
Lupus erythematosus	1	0.4
Steven johnson syndrome	2	0.8
Papilloma	1	0.4
Nasolabial cyst	4	1.6
Dentigerous cyst	6	2.3
Odontogenic keratocyst	4	1.6
Radicular cyst	9	3.5
Residual cyst	2	0.8
Lateral periodontal cyst	1	0.4
Periapical granuloma	2	0.8
Cemento- ossifying fibroma	6	2.3
Giant cell granuloma	1	0.4
Ameloblastoma	6	2.3
Pleomorphic adenoma/salivary gland tumour	1	.04
Osteoma	1	0.4
Osteomyelitis	2	0.8
Non specific inflammatory pathology	4	1.6
	257	100

IV. Discussion

In this study, we analysed the prevalence of oral lesions biopsied during 5 years from 2019 to 2023 and found 257 lesions. The mean age of the study was 48 years, and 58 % of the lesions were present among the age group of 40–69 years (Table 1). In the study conducted by Ulaganathan et al [3], it was reported that 50.4% were between 31 and 60 years old. In addition, the mean age in the survey of Kniest et al was 47.2 years [4]. The result was consistent with the above study. In the present study, we found a slight male predominance (Figure 1). In addition, Jahanbani et al [5], in a clinical-based study on an Iranian population, revealed a higher frequency of lesions among men. However, in the study by Moridani et al the frequency of oral lesions was higher in females due to the different study population [6].

Concerning the anatomical location, about two-thirds of the lesions were located in soft tissues (76.7%). In a similar survey of the Iranian population, peripheral lesions were more common than intraosseous lesions [7]. However, intraosseous lesions were more frequent than peripheral lesions in Fierro-Garibay C et al [2] than in the present study (56.4% vs. 23.3%). This may be due to a different geographical location.

In this study, about one-third (30.4%) of lesions were in the buccal mucosa (Table 2). It was followed by the tongue (21%), followed by the lower lip (12.8%). The most common inflammatory or reactive lesion was traumatic fibroma and pyogenic granuloma which constituted about 14.4% and 0.8%, respectively, in the present study. The total frequency of fibromas in other studies (Fierro-Garibay C et al and Kniest G et al.) was 10% and 11.4%, respectively [2,4]. In a retrospective study by Seyedmajidi et al the most common fibrous lesion of the oral cavity was the irritation fibroma, and the most common haemorrhagic soft tissue lesion was the pyogenic granuloma [8]. Mucocele presented 6.6% in our study, which was in contrast to Fierro-Garibay C et al who reported 0.9% in 460 biopsies [2].

In this study, radicular cysts with an inflammatory origin (3.5%) were more prevalent in hard tissue lesions compared to dentigerous (2.3%) and odontogenic keratocysts/keratocystic odontogenic tumor (1.6%). This result was consistent with the study conducted by Fierro-Garibay C et al [2], Jones et al [9] and Ochsenius et al [10] considered the frequency of lesions to be greater in the anterior maxilla, as this region is characterized by the presence of large epithelial remnant and is exposed to a higher risk of trauma. Root cysts of inflammatory origin accounted for 19.5% of all biopsy lesions in the Satorres et al [11] study. They were common in the second and third decades of life, which is consistent with the results of De Souza et al. [12] and more prevalent in males. In a study conducted by Satorres et al [11] with documented 77 periapical alterations, 52% were root cysts and 48% were periapical granulomas.

The dentigerous cyst (2.3%) was more common in the posterior mandibular region with impacted third molars, followed by upper canines. In the study published by Satorres et al 58% of the hard tissue lesions were in the mandible and 42% in the maxilla [11]. In our study, 23% of the biopsies were tumours located in the hard tissues. This is inconsistent with the present study, with a prevalence of 23% in hard tissue, 14.4% in the mandible, and 9% in the maxilla.

The most prevalent benign neoplasm was ameloblastoma constituting about 2.3%. A 10-year retrospective study of the biopsied oral soft tissue lesions in an Iranian population revealed 18.4% benign soft tissue tumours, including 91.2% reactive and 8.8% neoplastic lesions [13]. In the current study, the most common malignancies were squamous cell carcinoma 37.4% (Table 4). Ikeda et al evaluated the incidence of malignant changes in the oral cavity in 1319 subjects [14]. He reported 1.4% malignant tumours in 4.9% patients with oral lesions. This prevalence of higher percentage in the present study may be due to the referral, as Government Vellore medical college is a tertiary center. It should be considered as referral bias. The most common location was lower lip and tongue. This result was consistent with result of Shahsavari F et al [15].

V. Conclusion

Within the limits of the study, the most prevalent lesion in our study was squamous cell carcinoma in a tertiary care center. Other studies may show contradictory results because of age, gender, geographic location, and population reported to the department of maxillofacial surgery. However, the result may be related to referral. The importance of biopsies in the study of premalignant and malignant lesions, considering the prognostic relevance of establishing an early diagnosis.

Reference

- [1] Melrose Rj, Handlers Jp, Kerpel S, Summerlin Dj, Tomich Cj, American Academy Of Oral And Maxillofacial Pathology. The Use Of Biopsy In Dental Practice. The Position Of The American Academy Of Oral And Maxillofacial Pathology. Gen Dent. 2007;55(5):457-61.
- [2] Fierro-Garibay C, Almendros-Marqués N, Berini-Aytés L, Gay-Escoda C. Prevalence Of Biopsied Oral Lesions In A Department Of Oral Surgery (2007-2009) J Clin Exp Dent. 2011;3:E73-7
- [3] Ulaganthan G, Babu S S, Asok Kumar Rs. Retrospective Analysis Of Oral And Maxillofacial Biopsies : An Institutional Study. J Pharm Bioallied Sci. 2020 Aug; 12(Suppl 1): S468-S471.
- [4] Kniest G, Stramandinoli Rt, Avila Lfd, Izidoro Ac. Frequency Of Oral Lesions Diagnosed At The Dental Specialties Center Of Tubarao (Sc). Rsbo. 2011;8(1):13-8.
- [5] Jahanbani J, Sandvik L, Lyberg T, Ahlfors E. Evalu- Ation Of Oral Mucosal Lesions In 598 Referred Iranian Patients. Open Dent J 2009 27;3:42-7.
- [6] Moridani S.G, Shaahsavari F, Adeli Mg. A 7 Year Retrospective Study Of Biopsied Oral Lesions In 460 Iranian Patients. Rsbo. 2014 Apr-Jun;11(2):118-24
- [7] Ghasemi Moridani S, Mohtasham Z, Sazesh Sf. Correlation Between Clinical And Histopathological Diagnosis Of Oral Lesions Surgery In The City Of Rasht (2000-2002). J Islam Dent Assoc Ir. 2005;17(2):95-9.
- [8] Seyedmajidi M, Hamzehpoor M, Bagherimoghaddam S. Localized Lesions Of Oral Cavity: A Clinicopathologic Study Of 107 Cases. Res J Med Scie. 2011;5(2):67-72.
- [9] Jones Av, Craig Gt, Franklin Cd. Range And Demographics Of Odontogenic Cysts Diagnosed In A Uk Population Over A 30-Year Period. J Oral Pathol Med. 2006;35:500-7.

- [10] Ochsenius G, Ortega A, Godoy L, Peñafiel C, Escobar E. Odontogenic Tumors In Chile: A Study Of 362 Cases. *J Oral Pathol Med.* 2002;31:415-20.
- [11] Satorres M, Faura M, Bresco M, Berini L, Gay Escoda C. Prevalencia De Lesiones Orales Biopsiadas En Un Servicio De Cirugía Bucal. *Med Oral Patol Oral Cir Buc.* 2001;6:296–305.
- [12] De Souza Lb, Gordón-Núñez Ma, Nonaka Cf, De Medeiros Mc, Torres Tf, Emiliano Gb. Odontogenic Cysts: Demographic Profile In A Brazilian Population Over A 38-Year Period. *Med Oral Patol Oral Cir Bucal.* 2010;15:E583–90
- [13] Shahsavari F, Khourkiaee S, Ghasemi Moridani S. Epidemiologic Study Of Benign Soft Tissue Tumors Of Oral Cavity In An Iranian Population. *3 2012; 1 (1) :10-15*
- [14] Ikeda N, Handa Y, Khim Sp, Durward C, Axéll T, Mizuno T, Et Al. Prevalence Study Of Oral Mucosal Lesions In A Selected Cambodian Population. *Community Dent Oral Epidemiol.* 1995;23:49–54.
- [15] Shahsavari F, Sadri D, Jolehar M, Farzanehnejad R. Epidemiologic Study Of The Prevalence Of Oral Mucosal Lesions In The Biopsied Samples At Buali And Imam Khomeini Hospitals From 2000 To 2014 *J Res Dentomaxillofac Sci.* 2016;1(1):28-33.