

# Atypical Meningioma Of Spine – Role Of Pathologist In Predicting Prognosis

Author

---

Date of Submission: 15-07-2024

Date of Acceptance: 25-07-2024

---

## I. Introduction:

Spinal tumors comprise 5% to 10% of all central nervous system tumors and most of them are intradural and extramedullary in location. Among spinal tumors neurofibromas, and meningiomas are the most common ones.

Meningiomas are known to arise from arachnoid cap cells and are classified into three groups namely grade 1, grade 2, and grade 3 as per the World Health Organization. Though a majority of these tumors are of Grade 1, some of them can be of Grade 3 which is highly anaplastic and has a high rate of metastasis.<sup>1</sup> Risk for tumor recurrence and prognosis depends on pathological features such as the grade of the tumor, Ki67 index, size of the tumor, and expression of hormone receptors. This case report reviews the clinicopathological features of spinal meningioma and to role of the pathologist in grading these tumors so that the mode of treatment and follow-up can be planned accordingly.<sup>2</sup>

## II. Case History:

We report a case of 75-year-old female who presented with lower backache for 2 years. Pain which was insidious in onset, gradually progressive in nature and radiated to both lower limbs.

She was nondiabetic, non-hypertensive, and didn't have any significant past history. On examination of the spine she had 70° Straight leg raising test showed 0/5 power from L<sub>2</sub>-S<sub>1</sub> on the right side and 1/5 power from L<sub>2</sub>-S<sub>1</sub> on the left side. Sensation on both limbs was normal. Laboratory investigations were normal.

MRI Dorsal spine revealed a well-defined T<sub>1</sub> isointense and T<sub>2</sub> /STIR heterogeneously hyper-intense extramedullary intradural lesion in the left posterior aspect of the spinal cord at the level of T<sub>8</sub>-T<sub>9</sub> extending into left neural foramina showing patchy restricted diffusion and avid homogenous enhancement cause cortical displacement and compression. Differential diagnosis of spinal meningioma and spinal schwannoma were considered.

Laminectomy D<sub>8</sub>-D<sub>9</sub> with excision of intradural extramedullary mass and stabilization with pedicle screw fixation was planned.

Intraoperatively the tumor was fleshy, yellowish, and firm inconsistency. It was attached to the dura and adherent to the root but was not arising from the root. The tumor was excised in toto by subcapsular dissection and sent for histopathological analysis.

Grossly we received a single grey white soft tissue mass measuring 1.5x1 centimeters. It was firm, gray-white in appearance. No attached nerve roots/calcification was seen. The entire tumor was processed.

## III. Results-

### Microscopy:

- Hematoxylin and Eosin stained sections studied from the lesional tissue show meningotheial cells arranged predominantly in a **sheeting pattern**, arranged in fascicles and interlacing bundles with areas of whorl formation.
- Tumor is **hypercellular** with enlarged moderately pleomorphic cells. Individual tumor cells are spindle-shaped with elongated nuclei, **prominent nucleoli**, and eosinophilic cytoplasm. **5 mitotic figures seen/10 hpf**
- **IHC:** In our case EMA - positive. S100-negative, PR showed low positivity and Ki67 showed high positivity.
- **Impression:** Features are suggestive of- **Atypical meningioma- WHO grade 2.**

## IV. Discussion:

Spinal meningiomas are more common in the thoracic region followed by the cervical and lumbar region though MRI is the diagnostic modality of choice. Spinal meningiomas are common in adult women with a mean age of 64 years and the highest prevalence in the 75- 79 years age group, 9:1 (M: F) ratio, with 80% of them being Grade 1.<sup>3</sup>

Our patient was a 75-year-old female patient with grade 2 histology.

Ionizing radiation, hormonal variation (treatment with endogenous and exogenous hormones, obesity, tobacco use, and lack of breastfeeding are known to be associated with a high risk of meningioma. Our patient did not have any of the above risk factors. <sup>4</sup>

Most of the spinal meningiomas in adults are sporadic and genetically acquired meningiomas are usually multiple, occur in young, and are associated with neurofibromatosis type 2 or schwannomatosis. <sup>5</sup> Since our case was an elderly lady genetic analysis was not done.

Size of the tumor, histopathological features such as high cellularity, grade, Ki 67, and expression of progesterone receptor are known to have prognostic value. <sup>6</sup>

WHO grading is based on MAJOR CRITERIA- (at least 1) - 4 to 19 mitoses per ten high-power fields, direct invasion of the brain parenchyma and MINOR CRITERIA (3 or more of the following 5 histologic features) necrosis, sheet-like growth, small cell change, increased cellularity and prominent nucleoli. <sup>1</sup> Since our cases had high mitotic activity, sheet-like growth pattern, increased cellularity, and prominent nucleoli a diagnosis of grade 2 meningioma was made.

In a study by Ki 67 expression in atypical meningioma ranged between 4 to 16 % with a mean value of 7.55 %. However, recurrent tumors had a mean Ki 67 value of 10.4%. They concluded that the proliferative index is a powerful independent predictor for recurrence and must be assessed regularly. <sup>7</sup>

Hormonal factors such as higher association with females and expression of progesterone receptors are known to be associated with meningiomas with an expression of 96.8%, 20%, and 0%, respectively in grades I, II, and III. Less expression of PR is known to be associated with recurrence and/or malignant transformation. <sup>8</sup>

Progression-free survival is predicted by the degree of resection, tumor multiplicity, location, histopathological factors such as mitotic index, grade, tumor size (> 6 cms), and high cellularity. In atypical cases, a combined assessment of PR status and Ki 67 may help in predicting the recurrence. <sup>9</sup> Grade 2 tumors have a recurrence of 18.4% while grade 1 has 4.9% and grade 3 has 27.3% mitotic index <5%, tumor size of 6cms is associated with a better prognosis.

Adjuvant radiotherapy is an essential treatment arm in patients with anaplastic meningiomas. In this case the patient was advised for radiotherapy, but unfortunately patient refused and during follow-up up patient showed very minimal clinical improvement.

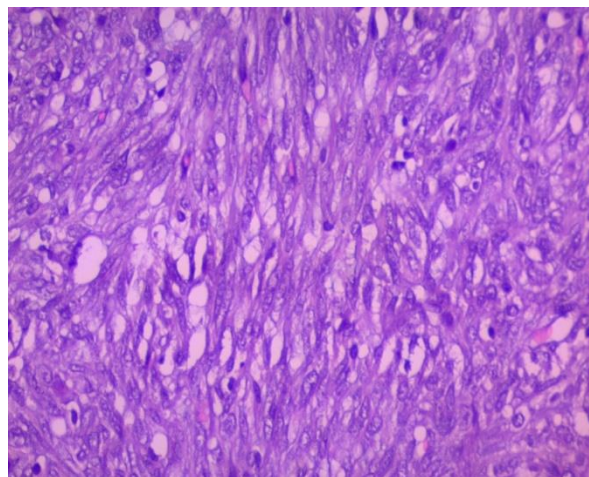
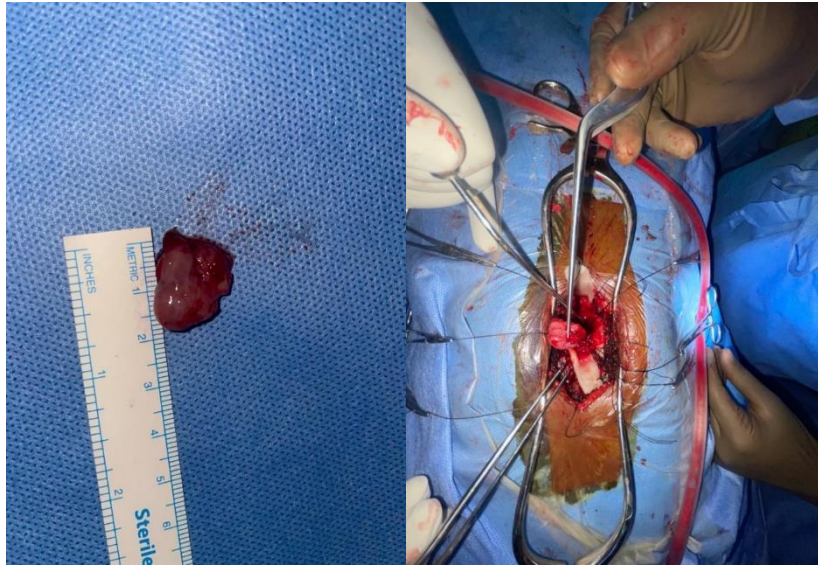
This case is reported due to the low incidence of atypical meningiomas of the spine, and the role of looking into histopathological features such as cellularity Ki67, and PR status.

## V. Conclusion

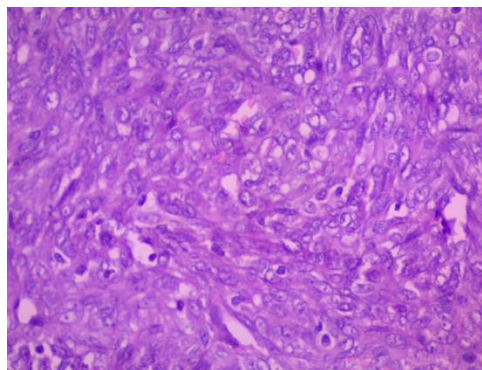
The case report emphasizes the significance of a multidisciplinary approach involving clinicians, pathologists, and radiologists in the management of spinal meningiomas, particularly in rare cases such as Grade 2 atypical meningiomas of the spine.

## References-

- [1] International Agency For Research On Cancer. WHO Classification Of Tumours Of The Central Nervous System: Who Classification Of Tumours. 5th Ed. Who Classification Of Tumours Editorial Board, Editor. IARC; 2022
- [2] El-Hajj VG, Pettersson Segerlind J, Burström G, Edström E, Elmi-Terander A. Current Knowledge On Spinal Meningiomas: A Systematic Review Protocol. *BMJ* 2022;12(6):E061614.
- [3] Koeller KK, Shih RY. Intradural Extramedullary Spinal Neoplasms: Radiologic-Pathologic Correlation. *Radiographics* 2019 39:2, 468-490.
- [4] Kobayashi K, Ando K, Matsumoto T, Clinical Features And Prognostic Factors In Spinal Meningioma Surgery From A Multicenter Study. *Sci Rep* 2021; 11: 1163.
- [5] Meningiomas
- [6] Pathmanaban ON, Sadler KV, Kamaly-Asl ID, King AT, Rutherford SA, Hammerbeck-Ward C Et Al. Association Of Genetic Predisposition With Solitary Schwannoma Or Meningioma In Children And Young Adults. *JAMA Neurol.* 2017;74(9):1123-1129
- [7] Levy WJ, Bay J, Dohn D: Spinal Cord Meningioma. *J Neurosurgery* .
- [8] (Lee SH, Lee EH, Sung KS, Kim DC, Kim YZ, Song YJ. Ki67 Index Is The Most Powerful Factor For Predicting The Recurrence In Atypical Meningioma: Retrospective Analysis Of 99 Patients In Two Institutes. *J Korean Neurosurg Soc.* 2022;65(4):558-571.
- [9] Mnango I, Mwakimonga A, Ngaiza AI, Yahaya JJ, Vuhahula E, Mwakigonja AR. Expression Of Progesterone Receptor And Its Association With Clinicopathological Characteristics In Meningiomas: A Cross-Sectional Study, *World Neurosurgery* 2021; 12:100111.
- [10] Sadiya N, Pande A, Salapathi S, Ghosh S. Recurrent Atypical Meningioma Of The Lumbosacral Spine. *Neurol India* 2019;67:300-2
- [11]

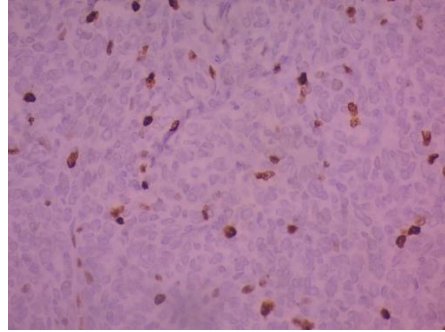
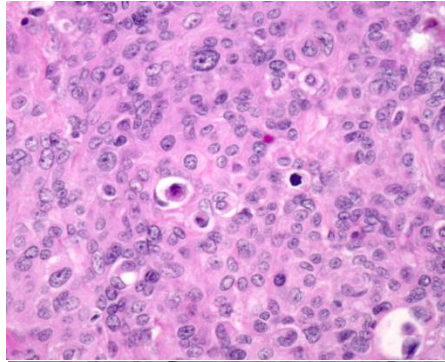


**Tumor cells in interlacing bundles and in sheet-like pattern**

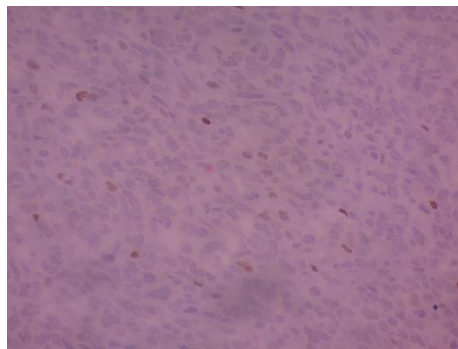


**tumor is hypercellular with individual tumor cells showing enlarged moderately pleomorphic cells and prominent nucleoli- Meningothelial cells**

**MITOTIC FIGURES**



KI67



PR