

# Frontiers In Oral And Maxillofacial Reconstruction: Emerging Trends And Innovations In Modern Flap Techniques

Richa Wadhawan<sup>1</sup>, Shakti Kumar Sonu<sup>2</sup>, Paras Nath Sahu<sup>3</sup>, Sushma Mishra<sup>4</sup>,  
Deepali Verma<sup>5</sup>, Laxmi Chauhan<sup>6</sup>

Professor, Department Of Oral Medicine, Diagnosis & Radiology, PDM Dental College & Research Institute,  
Bahadurgarh, Haryana

Consultant, Department Of Oral And Maxillofacial Surgery, Rukmini Dental Implant Clinic And Maxillofacial  
Trauma Centre, Purnea, Bihar

Assistant Professor, Department Of General Surgery, Government Medical College, Singrauli, Madhya  
Pradesh

Private Practitioner, Shree Sai Dental Clinic, Tikamgarh, Madhya Pradesh

Private Practitioner, My Dentist Dental Clinic, Bhopal, Madhya Pradesh

Dental Surgeon & Cosmetologist, Coulombiya Aesthetics, Pune, Maharashtra

---

## Abstract:

Oral and maxillofacial reconstruction has undergone significant advancements with the advent of modern flap techniques, expanding the possibilities for effective surgical outcomes. This review explores the latest trends and innovations in the field, including breakthroughs in 3D printing, tailored flap designs, and refined microsurgical techniques. These innovations are examined for their potential to enhance tissue healing, precision, and customized outcomes. This review consolidates various local and regional flaps for the reconstruction of oral and maxillofacial defects, detailing their indications, contraindications, and harvesting techniques. Emerging research directions, such as the integration of artificial intelligence for predictive analytics, the improvement of flap vascularisation, and the exploration of novel and hybrid flap designs, are also examined. Additionally, the review addresses the importance of long-term outcomes, quality of life considerations, and the ethical and cost-effectiveness implications of these advancements. Overall, the dynamic evolution of oral reconstruction techniques promises to significantly improve surgical results and patient care.

**Key words:** Oral Reconstruction, Flap Techniques, Free Tissue Transfer, Microsurgery, 3D Imaging, Donor Site Morbidity Functional & Aesthetic Outcomes, Head and neck cancer

---

Date of Submission: 19-08-2024

Date of Acceptance: 29-08-2024

---

## I. Introduction:

Flap surgery, a pivotal aspect of reconstructive procedures, involves transferring tissue from one area to another while maintaining its blood supply to ensure viability. Unlike grafts, which rely on the recipient site's vascularity, flaps sustain their own blood flow, making them crucial for repairing tissue defects that cannot be closed directly.<sup>1</sup>The origins of flap surgery trace back to 600 BC, with the Sushruta Samhita detailing cheek flaps used for nasal reconstruction.<sup>2</sup> Classification of Flaps: Flaps are categorized by their blood supply (random or axial), tissue type (cutaneous, myocutaneous, osseocutaneous), and distance from the donor site (local, regional, or distant).<sup>3</sup> Random flaps, which depend on the subdermal vascular plexus, are limited to a length-width ratio of no more than 3:1.<sup>4</sup> In contrast, axial flaps, such as the deltopectoral flap, have a named artery providing a more reliable blood supply.<sup>5</sup>Tissue types range from simple cutaneous flaps for small defects to complex composite flaps like the radial forearm free flap or the fibula free flap for extensive reconstructions.<sup>6</sup> Local flaps, derived from nearby donor sites, are essential for integrating the donor site into the closure process.<sup>7</sup>They can be advanced, rotated, transposed, interpolated, or combined. Examples include O-to-H, O-to-Z, rhombic, bilobed, and melolabial flaps.<sup>8</sup>These rely on random pattern blood supplies and are used for smaller defects.<sup>9</sup>Key considerations include scar formation and placement within aesthetic boundaries such as the nasolabial fold or hairline.<sup>10</sup> Local flaps generally adhere to a length-width ratio where the length does not exceed three times the width of the base. Wide undermining of up to 2 to 4 cm helps close the primary defect,

though care is needed to avoid disturbing delicate structures.<sup>11</sup>V-to-Y advancement flaps require about one-third of their surface area to remain connected to the subdermal fat.<sup>12</sup> Regional flaps involve tissues from specific body areas not immediately adjacent to the defect.<sup>13</sup> Key regional flaps include the Radial Forearm Flap, Anterolateral Thigh Flap, Temporalis Myocutaneous Flap, and Omental Flap. Regional flaps offer versatility and are suitable for larger or more complex defects. Flaps within or close to the oral cavity, such as the Buccal Fat Pad Flap and the Facial Artery Musculomucosal Flap, are effective for limited intraoral defects.<sup>14</sup> External flaps like the Platysma, Temporalis Muscle, Pectoralis Major, and various Trapezius Flaps provide coverage from areas outside the oral cavity.<sup>15</sup>Free flaps are entirely removed and micro surgically reattached. They include complex reconstructions such as latissimus dorsi free flaps for traumatic scalp avulsions and radial forearm free flaps for hemiglossectomies. Free tissue transfer involves various techniques based on flap type and surgeon preference, with critical considerations including correct tissue type and sufficient vascular pedicle length.<sup>16</sup>Techniques vary, such as identifying and dissecting the vascular pedicle before flap elevation or starting with flap elevation followed by vascular dissection.<sup>17</sup> Basic flap design is a fundamental aspect of reconstructive surgery, involving the creation of tissue flaps to restore form and function in areas of tissue loss or defect.<sup>18</sup> Flap design aims to provide adequate blood supply to the transferred tissue while ensuring optimal aesthetic and functional outcomes.<sup>19</sup> Key principles include selecting the appropriate flap type based on the defect's location and size, considering the surrounding tissues' vascularity, and planning incisions to preserve neurovascular structures and minimize donor site morbidity.<sup>20</sup>Common flap designs include local, regional, and free flaps, each offering distinct advantages and limitations depending on the specific clinical scenario.<sup>21</sup> Preparation involves thorough patient assessment and medical history review to develop a customized treatment plan. Preoperative considerations include smoking status, vascular health, steroid use, diabetes, prior surgeries, defect extent, and patient condition.<sup>22</sup>Preoperative angiograms may be employed to assess circulation for free or regional flaps. The "Reconstructive Ladder" guides flap selection, from least invasive methods like secondary intention healing to complex solutions like tissue transplants. In-office local flap procedures, such as Mohs defect closures, use scalpels, forceps, needle holders, dissecting scissors, and sutures.<sup>23</sup>

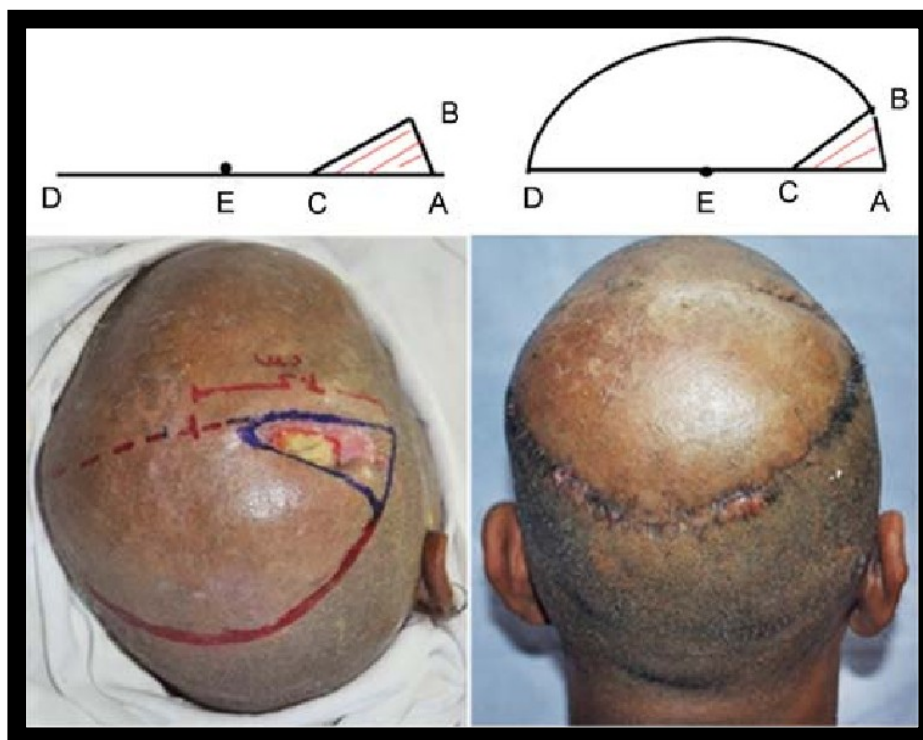
Personnel requirements range from a minimum of a surgeon and nurse to including an anesthesia provider, surgical technician, and first assistant for more complex cases.<sup>24</sup>Equipment needs vary. Local flaps may require only basic tools and local anesthesia, while larger regional and free flaps demand extensive instrumentation, including bone saws, operating microscopes, and microvascular tools.<sup>25</sup>The risk decreases as neovascularization occurs, typically 2 to 3 weeks post-surgery.<sup>26</sup> Secondary donor site reconstruction, usually with a split-thickness skin graft, is common for large free flaps.<sup>27</sup>Regional tissue transfer, similar to free tissue transfer, offers versatility with flaps adaptable for both regional and free transfer, maintaining a continuous blood supply and not detached from the body.<sup>28</sup> Notable examples include the paramedian forehead flap and the pectoralis major myocutaneous flap.<sup>29</sup> Regional flaps require less complex equipment and operative time compared to free flaps but may also need secondary reconstruction.<sup>30</sup>Complications in flap surgery can involve donor site issues such as bleeding, infection, scarring, and functional impairment, as well as flap-specific problems related to blood supply that can lead to flap necrosis.<sup>31</sup> The severity of complications often correlates with the size and complexity of the flap and the patient's overall health.<sup>32</sup>Managing complications effectively and monitoring closely are essential to ensure optimal outcomes.<sup>33</sup> For larger defects, flap failure has more extensive consequences and presents significant challenges in achieving successful reconstruction.<sup>34</sup>Vascular compromise, often due to venous outflow obstruction, is a common issue, with clot formation in the main draining vein being frequent in larger flaps.<sup>35</sup>Local flaps may encounter issues from excessive tension or torsion, and hematoma compression can affect vascular flow. Venous obstruction may be managed with medicinal leeches and prophylactic antibiotics.<sup>36</sup> Early flap failure can be due to infection, inadequate blood pressure, poor nutrition, and noncompliance, while flaps with no signs of venous obstruction or arterial insufficiency in the first week are likely to remain viable.<sup>37</sup> Chronic complications can affect function and aesthetics, necessitating close monitoring and timely intervention.<sup>38</sup> An ideal flap uses minimal tissue, reduces donor site morbidity, and ensures optimal viability to avoid future revisions.<sup>39</sup>Achieving the best patient outcomes in flap procedures requires a collaborative, multidisciplinary approach. Physicians evaluate patient suitability, select surgical techniques, and manage complications. Advanced practitioners conduct preoperative evaluations, assist in procedures, and provide patient education.<sup>40</sup>Nurses monitor patients, assess flap viability, manage wound care, and offer education. Pharmacists handle medications, including prophylactic antibiotics and pain management. Physical therapists support postoperative rehabilitation, prevent complications, and encourage early mobilization. Interprofessional communication and teamwork are crucial for ensuring seamless care, managing complications, and improving patient outcomes.<sup>41</sup>

## **II. Discussion:**

A fundamental skill of reconstructive surgery is flap design and transfer to close tissue defects that cannot be sutured primarily.<sup>42</sup> Given the diverse spectrum of tissue defects encountered in patients, ranging from small, skin-only defects to extensive, multi-tissue-type defects, and the various underlying causes, the skill set required for flap transfer must be adaptable and continually evolving as new techniques are described.<sup>43</sup> Flaps are often employed for wound closure when substantial tissue loss occurs during trauma or as a result of oncologic resection.<sup>44</sup> Classic examples include traumatic scalp avulsions requiring closure with latissimus dorsi free flaps and hemiglossectomies requiring reconstruction with radial forearm free flaps.<sup>45</sup> Understanding the anatomy and physiology of the defect and potential donor sites is critical to successful flap transfer, as is mastery of atraumatic soft tissue surgical technique. Ultimately, flap design and transfer represent the clinical intersection of the science of medicine and the art of surgery, which renders these procedures either immensely rewarding or singularly frustrating, depending on the outcome.<sup>46</sup>

**Scalp:**

The scalp's vascular network extends from the edges toward the center, necessitating that scalp flaps be based peripherally. When forming a skin flap, it should be raised in the loose areolar tissue layer above the galea aponeurotica. For small defects, the rotation flap is a preferred technique. Design this flap by creating an isosceles triangle ABC, with the pivot point D along the line projection AC.<sup>47</sup> Ensure that line CD is 50% longer than AC, and use the midpoint of AD as the center to draw an arc from B to D. For defects less than 3 cm<sup>2</sup>, primary closure is usually adequate (**Figure 1**). For defects up to 50 cm<sup>2</sup>, effective options include rotation flaps, transposition flaps, pinwheel flaps, bipedicle advancement flaps, double opposing rotation flaps, and the Orticochea four-flap technique.<sup>48</sup> For defects larger than 50 cm<sup>2</sup>, free tissue transfer is often necessary, with the anterolateral thigh flap or latissimus dorsi free flap being optimal choices. In the case of forehead flap reconstruction for the lower eyelid following the excision of basal cell carcinoma, or for basal cell carcinoma affecting the left nasal ala, the proximal pedicle is carefully untubed and repositioned to the medial brow, securing it in place with an inverted 'V' suture.<sup>49</sup>



**Figure 1: Rotation flap for scalp defect**

**Upper Face-Eyelid:** Reconstructing eyelid defects necessitates careful consideration of both skin coverage and conjunctival lining. For partial-thickness defects in the upper eyelid, if the defect is less than 50% of the lid, primary closure with a V-Y advancement flap is usually sufficient. Defects exceeding 50% in size are best addressed with a full-thickness skin graft.<sup>50</sup> For full-thickness defects less than 25%, primary closure can be achieved using techniques such as canthotomy and advancement, or Tessier's flap (**Figure 2**).<sup>51</sup> For larger full-thickness defects, the Hughes sliding tarsoconjunctival flap (**Figure 3**) is highly effective, with other viable

options including the Mustarde cheek advancement flap, the nasolabial flap, and the forehead flap. In cases of total eyelid defects, a supratrochlear artery-based median forehead flap is employed. This technique involves raising the distal third of the flap in the subcutaneous plane, the middle third with the frontalis muscle, and the proximal third in the subperiosteal plane to incorporate the supratrochlear artery.<sup>52</sup> If the flap extends beyond the frontal hairline, depilation is necessary. Buccal mucosa is used for prelamination of the forehead flap to replace the conjunctiva, and the flap is positioned over the defect, with division occurring after three weeks.

**Buccal (BICHAT) fat pad flap:** The buccal fat pad (BFP) is a specialized adipose tissue located in the masticatory space between the buccinator and masseter muscles, serving to prevent cheek collapse during infant sucking and aiding intermuscular movement in adults. It is enclosed in a thin fascial layer and has a rich venous network that may influence cranial and extracranial blood flow. The BFP (**Figure 4**) comprises a central body and four extensions: the buccal, pterygoid, deep temporal and superficial temporal. The central body is situated deep along the posterior maxilla and maxillary buccinator muscle fibers, while the buccal extension is superficially positioned on the inner cheek.<sup>53</sup> The pterygoid extension is located deep to the medial mandibular ramus, between the medial and lateral pterygoid muscles. The deep temporal extension lies beneath the zygomatic arch on the temporalis muscle, extending medially behind the lateral orbital wall, and the superficial temporal extension is enclosed by deep temporal fascia, stretching from the superior orbital rim to the zygomatic arch. The BFP is utilized in various oral and maxillofacial surgeries due to its unique properties. It is highly effective for reconstructing oral defects, including filling soft tissue defects resulting from trauma, tumors, or surgical resections, such as those following oral cancer surgeries. It is also employed to support areas affected by osteonecrosis where other tissue options may be inadequate. In palate and buccal mucosa reconstruction, the BFP enhances closure and improves functional outcomes in cleft palate surgeries and covers defects resulting from surgery or disease. It manages chronic oral infections or abscesses by filling cavities and promoting healing, and it may also be used in aesthetic procedures to improve facial contour and volume. In dental implant procedures, the BFP serves as a graft material to enhance implant sites, especially where soft tissue is limited. The BFP is advantageous due to its ease of dissection, suitability for local anesthesia, and lack of visible scarring. It integrates well with surrounding tissues, providing a vascularized and well-accepted graft. Typically, the BFP weighs about 9.3 grams and has a volume of 9.6 millilitres, and when mobilized, it can provide a pedicled graft approximately  $6 \times 4 \times 3$  cm in size. Harvesting the BFP involves accessing the body and buccal extension through a small incision in the buccal mucosa using a horizontal mucosal incision along the superior vestibular sulcus, which is preferred for its efficacy. After incision and exposure, the BFP is gently extracted, rotated or tunnelled into the defect site, sutured into position, and immobilized with a splint or bite block for 12 days. It fully epithelializes within 3 to 4 weeks and is covered with healthy mucosa by 3 months. Despite its advantages, challenges include the delicate blood supply and lack of a distinct pedicle, which necessitates minimizing the flap's rotation arc and avoiding tension during placement. Preserving the thin capsule over the BFP is crucial to protect the small blood vessels. For patients with prior neck dissection or extensive head and neck radiation, careful assessment of the BFP's blood supply and viability is essential. Additionally, the flap may affect cheek contour and malar projection, and a nasogastric tube may be necessary for feeding during the stabilization period. Overall, the buccal fat pad is a valuable resource in oral and maxillofacial surgery, offering a versatile and effective solution for managing defects, enhancing healing, and improving both functional and aesthetic outcomes.<sup>54</sup>

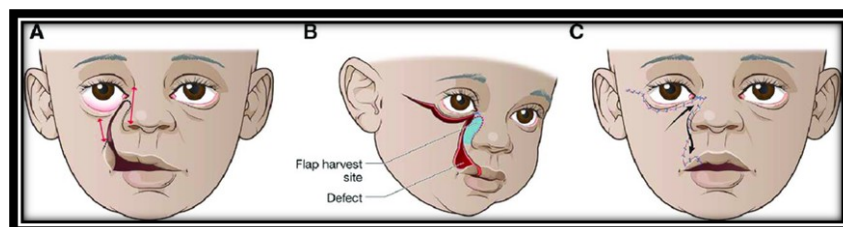
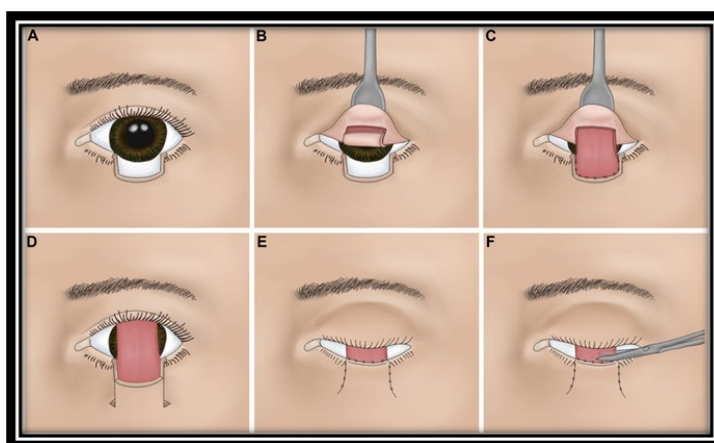
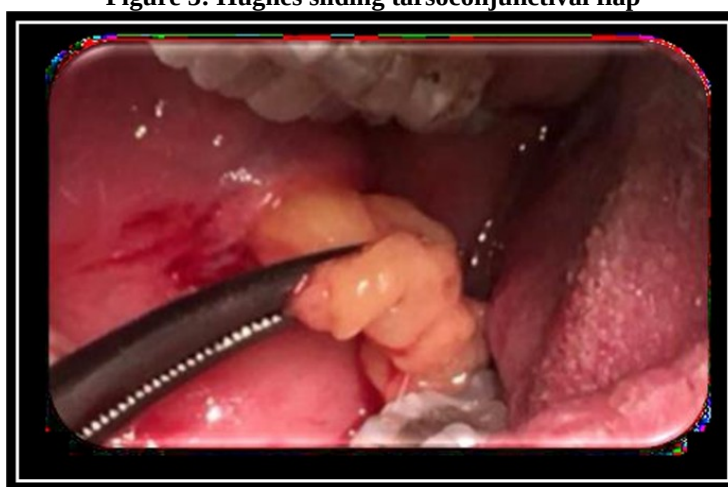

Figure 2: Tessier's flap



**Figure 3: Hughes sliding tarsoconjunctival flap**



**Figure 4: Buccal fat pad**

**Nose:**For nasal reconstruction, which addresses the tip, dorsum, columella, paired alae, sidewalls, and soft triangle subunits, the method depends on the defect's size and depth. Small defects are typically managed with local flaps such as the nasolabial flap (**Figure 5**) or bilobed flap.<sup>55</sup> For larger defects, options include the frontalis flap or forehead flap, chosen based on the defect's size, location, and the desired aesthetic and functional results. Superficial defects affecting only skin and subcutaneous tissue can be reconstructed with a bilobed flap or a V-Y advancement flap.<sup>56</sup> For extensive nasal defects or complete loss of the nose, the forehead flap is used, with the defect's outline marked on the median forehead to guide flap creation. For defects in difficult or less accessible locations, the nasolabial flap and forehead flap are effective choices.<sup>57</sup> For large defects exceeding 1.5 cm, both the nasolabial flap and forehead flap are recommended.<sup>58</sup> In cases of composite defects involving skin and adjacent structures, a free radial artery forearm flap is an appropriate option.<sup>59</sup> Reconstructing eyelid defects necessitates careful consideration of both skin coverage and conjunctival lining. For partial-thickness defects in the upper eyelid, if the defect is less than 50% of the lid, primary closure with a V-Y advancement flap (**Figure 6**) is usually sufficient.<sup>60</sup> Defects exceeding 50% in size are best addressed with a full-thickness skin graft. For full-thickness defects less than 25%, primary closure can be achieved using techniques such as canthotomy and advancement, or Tessier's flap.<sup>61</sup> For larger full-thickness defects, the Hughes sliding tarsoconjunctival flap is highly effective, with other viable options including the Mustarde cheek advancement flap, the nasolabial flap, and the forehead flap.<sup>62</sup> In cases of total eyelid defects, a supratrochlear artery-based median forehead flap is employed.<sup>63</sup> This technique involves raising the distal third of the flap in the subcutaneous plane, the middle third with the frontalis muscle, and the proximal third in the subperiosteal plane to incorporate the supratrochlear artery.<sup>64</sup> If the flap extends beyond the frontal hairline, depilation is necessary. Attention is given to the nasal projection, ensuring the flap design is slightly larger to account for potential foreshortening. Adequate nasal mucosal lining is also considered. The supratrochlear artery-based flap is raised and sutured over the defect. After 3 to 4 weeks, the pedicle is divided and the flap is contoured at the superior aspect of the defect. The proximal pedicle is untubed, repositioned to the medial brow, and sutured in an inverted 'V' configuration.<sup>65</sup>

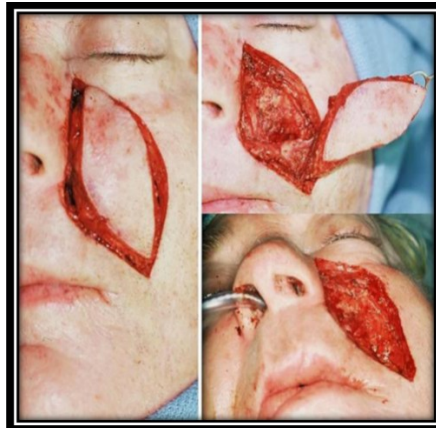


Figure 5: The nasolabial flap is narrowly pedicled on the facial artery, and then is tunneled via the buccal space into the oral cavity

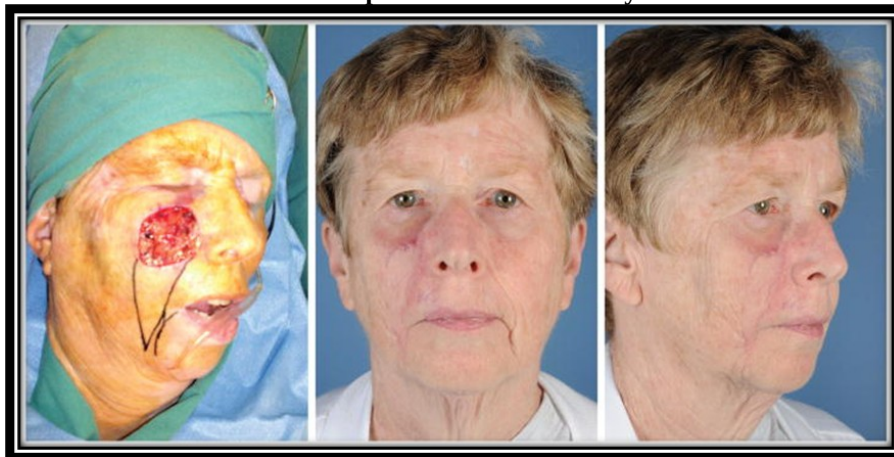

Figure 6: V-Y advancement flap

**Cheek:** When addressing cheek defects with excess skin laxity, local advancement flaps are preferred, provided there is adequate surrounding skin. For superficial defects, options include a full-thickness skin graft, rhomboid flap, bilobed flap, or cervicofacial advancement flap. For soft tissue defects, the temporoparietal fascia flap or temporalis muscle flap (Figure 7) are suitable choices. Small full-thickness defects can be effectively managed with the submental flap, deltopectoral flap, forehead flap, or free radial forearm flap. For larger full-thickness defects, the free radial forearm flap and the free anterolateral thigh flap are recommended.<sup>66</sup>

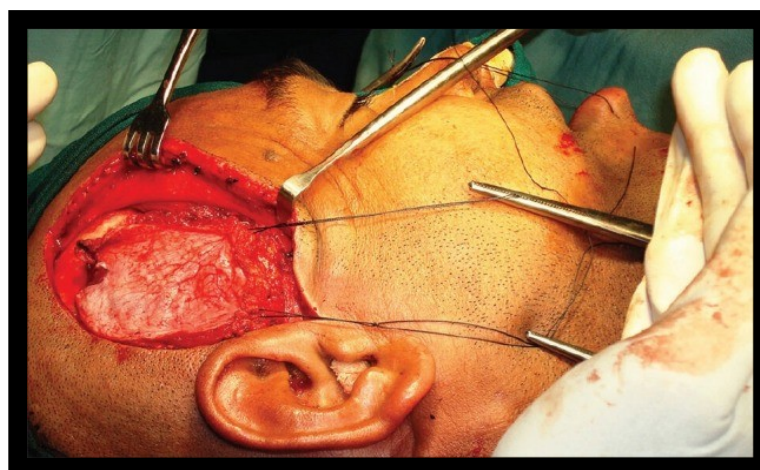
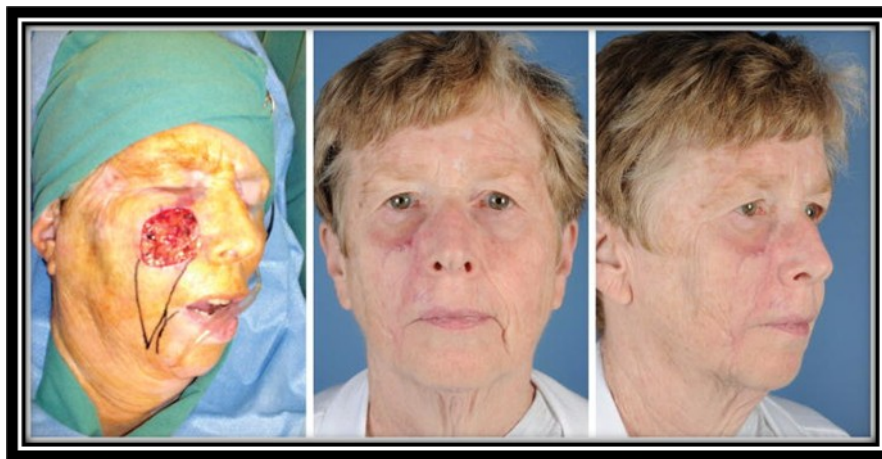

Figure 7: Temporalis muscle flap

**Rhomboid Flap for Superficial Cheek Defects:** For small superficial cheek defects, the rhomboid flap (**Figure 8**) is a highly effective and adaptable technique. Initially, the defect is reshaped into a rhomboid with 60° and 120° angles.<sup>67</sup> The flap is then designed in a region of loose skin to facilitate direct wound closure.<sup>68</sup> The rhomboid shape of the flap allows for rotation and advancement to cover the defect, minimizing tension and ensuring an optimal cosmetic outcome.<sup>69</sup> The flap design is tailored to the defect's shape and size, ensuring effective coverage. The marking is done in an area of loose skin to enable primary closure of the donor site with minimal tension. The flap is meticulously elevated from the surrounding tissue, preserving its vascular supply to maintain viability and prevent complications.<sup>70</sup> Once elevated, the flap is rotated into position to cover the defect. Its unique rhomboid shape allows it to be moved or rotated in various directions to accurately fit the defect, achieving a smooth and well-aligned closure. After securing the flap over the defect, the donor site is closed, with the design allowing for primary closure with minimal tension, thus reducing the risk of dehiscence and other issues.<sup>71</sup> Postoperative care is crucial for optimal healing and integration of the flap. This includes monitoring for signs of flap compromise or complications at both the flap and donor sites.<sup>72</sup> The rhomboid flap's flexibility makes it a valuable option in reconstructive surgery for superficial cheek defects, providing a functional and aesthetically pleasing result with a relatively simple technique. After incising the flap margins, the flap is transposed into the rhomboid defect, with the donor site closed along natural skin tension lines.<sup>73</sup>



**Figure 8: Rhomboidal flap**

**Submental Flap for Intraoral and Cheek Defects:** The submental flap (**Figure 7**) is a valuable option for reconstructing intraoral cheek defects, providing both skin and mucosa essential for functional and aesthetic restoration. Supplied by the submental artery, a direct branch of the facial artery located 5 to 6.5 cm distal to the facial artery's origin, the flap's vascular supply ensures robust blood flow, crucial for its viability and successful integration. The flap is harvested from the submental region beneath the chin and includes skin, subcutaneous tissue, and occasionally underlying muscle. Its size ranges from 4 × 5 cm to 15 × 7 cm, and it typically extends from the ipsilateral to the contralateral mandible angle, though larger dimensions are also feasible.<sup>74</sup> The flap's upper margin is aligned with the inferior mandible border. During the procedure, an incision is made along the inferior flap margin, through the platysma muscle (**Figure 10**), and includes dissection of the anterior belly of the digastric muscle to ensure inclusion of the submental perforator.<sup>75</sup> The flap is carefully elevated to preserve its vascular pedicle and then transposed to cover the defect, ensuring optimal coverage. It is sutured into place, with the donor site closed primarily to minimize tension. Postoperative care involves monitoring for signs of flap compromise and maintaining good oral hygiene to prevent infection and promote healing. The submental flap's versatility makes it suitable for various intraoral defects, effectively matching surrounding tissue and restoring both function and appearance, thus offering a straightforward and effective reconstruction solution.<sup>76</sup>

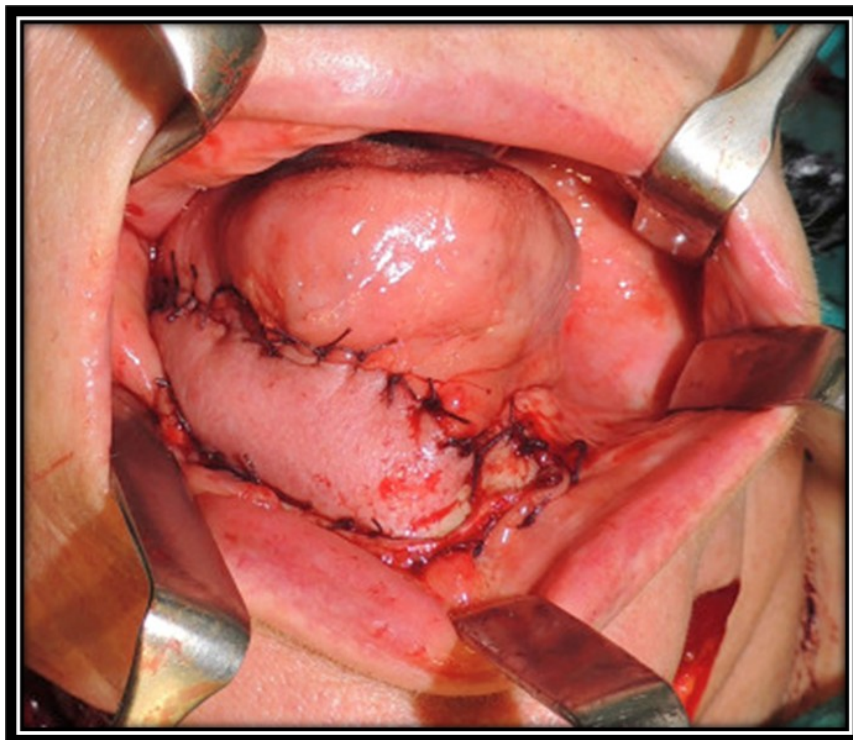


Figure 9: Submental flap

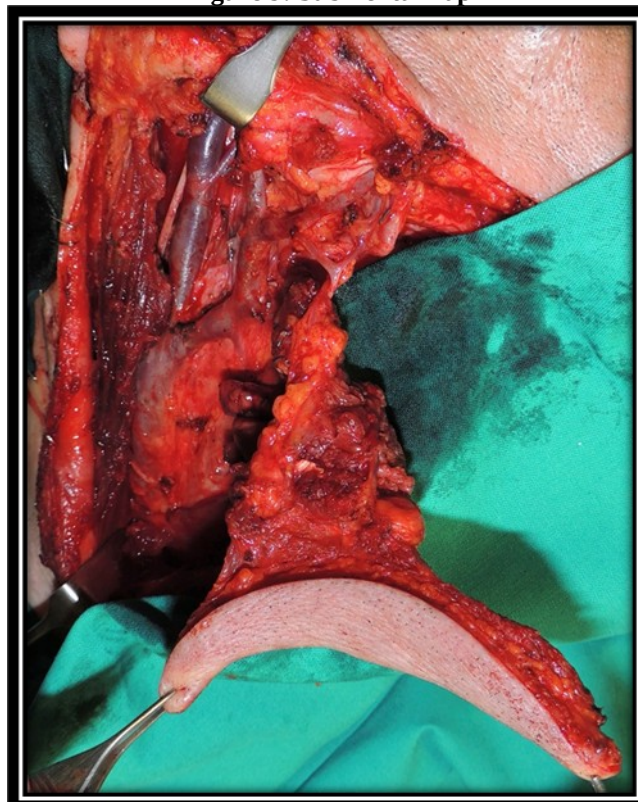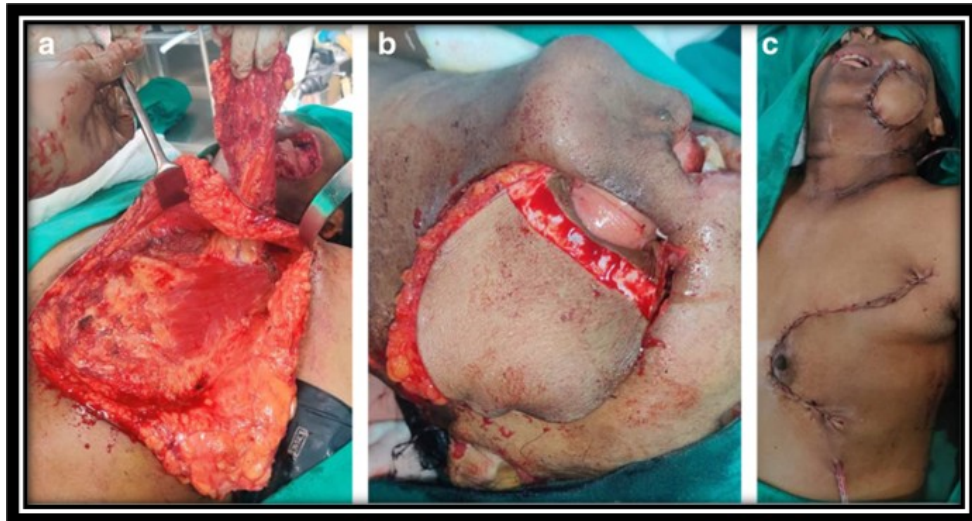


Figure 10: Island Platysma Flap

**Deltopectoral Pedicled Flap for Cheek Defects:**The deltopectoral flap (Figure 11) is a reliable technique for reconstructing large or complex cheek defects, utilizing its vascular supply from the perforators of the internal thoracic artery and the thoracoacromial artery.<sup>77</sup> The flap is designed between the deltoid and pectoralis major muscles, extending horizontally from 2 cm lateral to the parasternal border to the anterior shoulder, with dimensions tailored to cover the defect effectively. It is elevated in the subfascial plane from

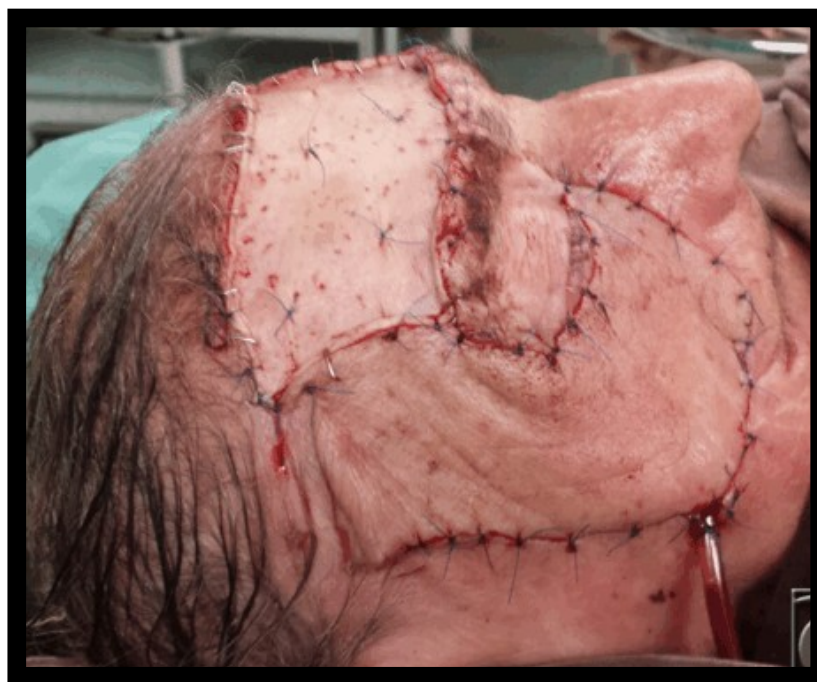

distal to proximal, with the flap's vascular pedicle carefully preserved to ensure viability. If the flap needs to extend beyond the anterior deltoid border, a delay procedure either through traditional elevation and resuturing or strategic delay involving incising and undermining in the infraclavicular fossa is required. The flap is then transferred to the defect site, positioned for optimal coverage, and sutured into place, while the donor site is closed with minimal tension. Postoperatively, careful monitoring for flap perfusion and wound care is essential to prevent complications and support healing. The deltopectoral flap's versatility makes it suitable for covering a wide range of defect sizes, offering both aesthetic and functional benefits in reconstructive surgery.<sup>78</sup>



**Figure 11: Deltopectoral flap**

**Superficial Temporal Artery Forehead Flap for Cheek and Intraoral Defects:** The Superficial Temporal Artery (STA) forehead flap (**Figure 12**), based on the frontal branch of the superficial temporal artery, is a versatile and effective method for reconstructing large or complex cheek and intraoral defects. The flap is designed to extend from the hairline to the superior edge of the eyebrow and is elevated in the loose areolar tissue plane above the galea aponeurotica, starting from the distal margin at the outer canthus of the contralateral eye. Dissection proceeds from the flap's superior edge toward the zygomatic arch, incorporating the parietal branch of the superficial temporal artery and its associated vein. To preserve facial expression, the flap can be elevated superficially to the frontalis and corrugator muscles, requiring careful protection of the frontal branch of the facial nerve.<sup>79</sup> The flap is transferred to the defect site, where it is secured with sutures for effective coverage. The donor site is closed primarily with attention to minimizing tension and enhancing cosmetic results. Postoperative care includes monitoring flap perfusion, checking for complications, and ensuring proper wound care to support healing. The STA forehead flap's ability to cover a wide range of defect sizes and its excellent aesthetic and functional outcomes make it a reliable choice for reconstructive surgery.<sup>80</sup>



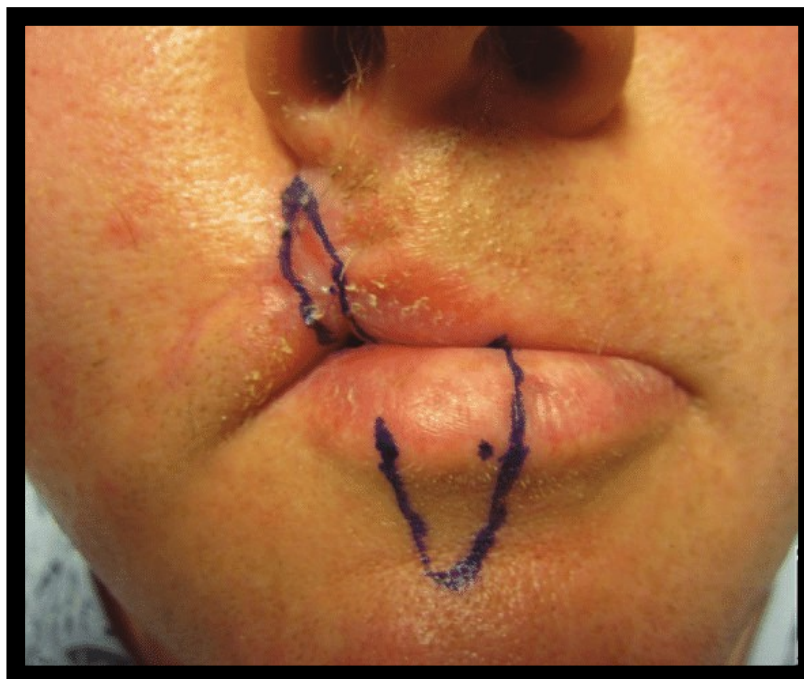**Figure 12: Superficial Temporal Artery Forehead Flap**

**Deep Circumflex Iliac Artery Flap for Maxilla Defects:** The deep circumflex iliac artery (DCIA) flap, based on the deep circumflex iliac artery—an external iliac artery branch—is a valuable reconstructive option for maxillary defects, especially when other methods are unsuitable. To harvest the flap, a line is drawn from the femoral artery at the midinguinal point to the inferior angle of the scapula. The skin paddle, typically 8 × 18 cm, is positioned one-third caudal and two-thirds cephalad along this line, starting at the anterior superior iliac spine and extending posteriorly.<sup>81</sup> An incision is made along the flap's upper margin, exposing the external oblique muscle fibers while preserving the musculocutaneous perforators. The external oblique muscle is then incised parallel to the iliac crest, and dissection continues medially and inferiorly over the inguinal ligament to expose the external iliac artery and vein. The deep circumflex iliac artery is traced laterally to the iliac crest, avoiding the lateral cutaneous nerve of the thigh. Osteotomies complete the elevation of the bone. This flap, which includes skin, abdominal wall muscles, and iliac crest bone, is used to reconstruct maxillary and mandibular defects.<sup>82</sup> The flap vessels are anastomosed to facial vessels, providing a reliable blood supply and versatility for large defects due to tumor resections, trauma, or congenital anomalies. Advantages of the DCIA flap include its adaptability to various defect sizes, low donor site morbidity, and dependable vascularization. Postoperative care involves monitoring flap viability and managing donor site healing, with potential complications including flap necrosis or donor site pain and numbness. With careful planning and execution, the DCIA flap offers excellent functional and aesthetic outcomes, although long-term results depend on the underlying condition and patient health.<sup>83</sup>

**Lip:** The complex anatomy of the lips, comprising skin, mucosa, minor salivary glands, muscles, and neurovascular structures, is vital for aesthetics, oral competence, speech articulation, facial expression, and the oral phase of swallowing. The primary goal of lip reconstruction is to restore these elements while maintaining lip competence and vermilion alignment. For defects less than 25%, direct closure is typically sufficient. For intermediate defects, up to two-thirds of the lip, options include the Abbe flap (**Figure 13**), Abbe-Estlander flap, Gillis flap, Karapandzic flap, and Webster crescentic advancement flap.<sup>84</sup> For total lip defects, reconstruction options include the free radial forearm flap, lateral arm flap, bilateral nasolabial Fuzimori gate flap, and unilateral nasolabial Fuzimori gate flap.

The Abbe flap, based on the inferior labial artery, covers two-thirds of the upper lip defect and includes skin, orbicularis oris muscle, and mucosa of the lower lip, with the pedicle placed at the midpoint of the defect and typically divided after 14 to 21 days.<sup>85</sup> The Estlander flap, based on the superior labial artery and raised from the upper lip's lateral aspect, is rotated downward into the lower lip defect to create a rounded commissure. The Karapandzic flap, utilizing bilateral facial arteries, can address up to three-fourths of the lower lip length while preserving the neurovascular bundle.<sup>86</sup> For extensive defects, the free radial forearm flap is harvested from the flexor side of the forearm, including skin supplied by radial artery perforators and optionally the palmaris longus tendon and part of the radius bone. Allen's test should confirm adequate hand vascular

supply before harvesting. Dissection starts in the subfascial plane, preserving superficial veins and avoiding damage to the superficial radial nerve, with the radial artery divided at the distal edge and dissection extended proximally. Suprafascial dissection helps reduce donor site morbidity. The lateral arm flap, supplied by perforators from the posterior radial collateral artery, is harvested along an axis from the deltoid insertion to the lateral epicondyle, with an average flap size of 12 × 6 cm. Dissection is performed in the subfascial plane, including the posterior cutaneous nerve for sensory function, and the flap may need defatting. This flap is also suitable for small oral mucosa defects.<sup>87</sup>



**Figure 13: Abbe flap**

**Oral Cavity:** The recommended reconstruction strategies for oral cavity defects depend on the defect's size and location. For defects exceeding 2 cm, available options include the nasolabial flap, submental flap, forehead flap, large pectoralis major myocutaneous flap (**Figure 14**), free radial forearm flap (**Figure 15**), and free anterolateral thigh flap (**Figure 16**). The nasolabial flap, used for intraoral mucosa defects, is typically an inferiorly based flap harvested from the nasolabial fold in the subcutaneous plane, usually supplied by perpendicular branches of the angular artery.<sup>88</sup> During dissection, the facial artery is preserved, and a tunnel is created in the buccal mucosa to position the flap inside the oral cavity. To avoid the need for a secondary procedure to close an orocutaneous fistula, the base of the flap where it enters the oral cavity is deepithelialized.<sup>89</sup> The pectoralis major myocutaneous flap is another option, with the thoracoacromial vessels supplying it running perpendicularly from the midpoint of the clavicle to the line connecting the acromion process and xiphisternum. The entire skin over the pectoralis major muscle can be raised, with flap size adjusted to reconstruct either the oral mucosa alone or both the mucosa and cheek skin. Commonly, a flap size of 6 × 7 cm is used, with adjustments made to avoid hair-bearing skin in males and breast tissue in females. The flap is elevated through a lateral incision to expose the pectoralis major muscle, followed by dissection to include the thoracoacromial vessels. Once the muscle and feeding vessel are identified, the planned skin paddle is incised, and the muscle is detached while preserving the vascular pedicle. If a deltopectoral flap is harvested simultaneously, care is taken to preserve internal mammary perforators by leaving a sufficient portion of the pectoralis muscle near the parasternal border.<sup>90</sup>

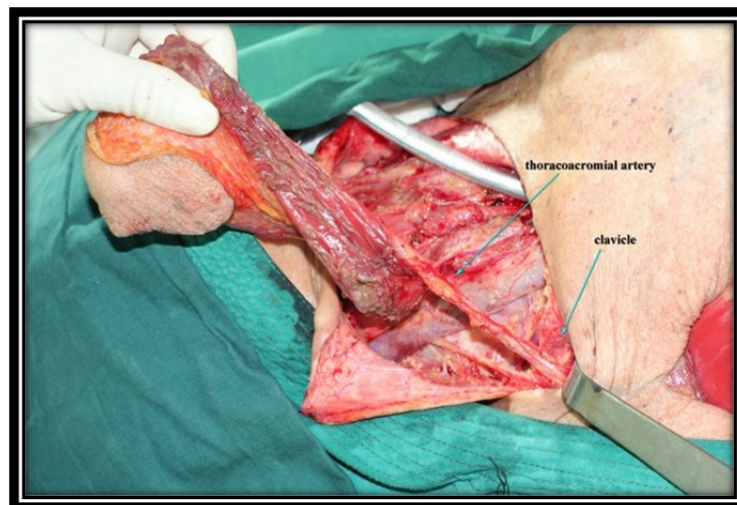


Figure 14: Pectoralis major myocutaneous flap

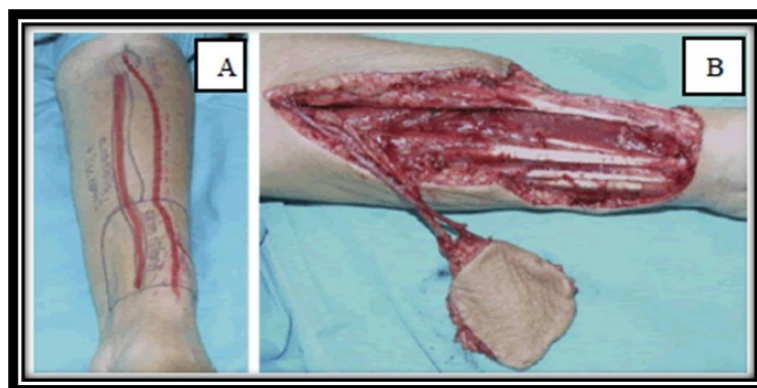


Figure 15: Free radial forearm flap

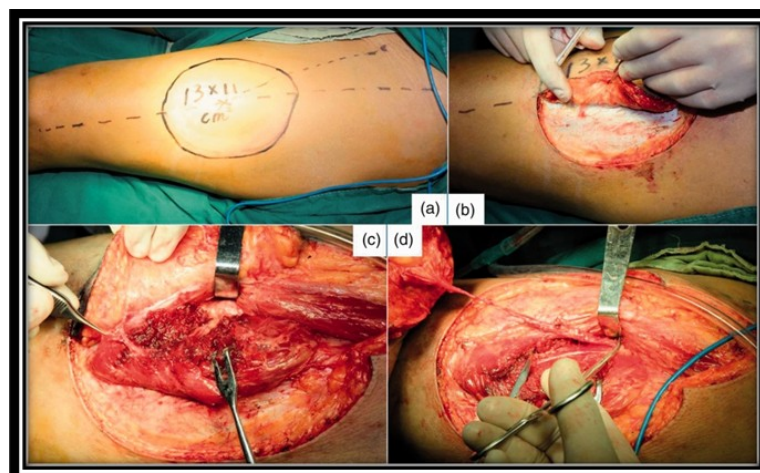


Figure 16: Anterolateral thigh flap

**Tongue:** Achieving three-dimensional reconstruction of the tongue is crucial for effective swallowing and speech, and the functional outcome largely depends on the amount of residual tongue tissue. For tongue defects, the recommended reconstruction options are as follows: the free radial forearm flap is suitable for hemiglossectomy, the free anterolateral thigh flap is recommended for subtotal glossectomy, and a pentagonal free anterolateral thigh flap is indicated for total glossectomy with floor of mouth involvement. Specifically, the radial artery forearm flap, designed in an omega shape with a wider base, can address defects from hemiglossectomy to subtotal glossectomy, covering both the base of the tongue and the floor of the mouth. For

total glossectomy, reconstructing the floor of the mouth requires a pentagonal-shaped flap, and the anterolateral thigh flap can be effectively used for this purpose as well.<sup>91</sup>

**Mandible:** Mandible reconstruction is essential for restoring facial contour, maintaining oral continence, enabling swallowing function, and supporting dental rehabilitation. The fibula flap (**Figure 17**) is the preferred method for this reconstruction, available as an osteocutaneous flap or an osteomusculocutaneous flap, tailored to specific needs. The deep circumflex iliac artery composite flap is also effective for defects from lateral or hemimandibulectomy. Recommended approaches for different mandible defects include using a free fibula flap for central 1/3rd defects, lateral defects, and total mandibulectomy, while a free fibula flap or deep circumflex iliac artery flap is suitable for lateral defects, and a free fibula flap or pectoralis major myocutaneous flap for hemimandibulectomy. For free fibula osteocutaneous flap harvesting, the patient is positioned supine with the knee flexed at 135°, the hip at 60°, and the leg internally rotated.<sup>92</sup> Skin perforators are marked in the middle third of the leg along an axis about 3 cm parallel and behind the line from the fibula head to the lateral malleolus, with a skin paddle outlined around the perforator. The anterolateral thigh flap, particularly in females, is often thick and may require thinning by excising excess subcutaneous fat without compromising perfusion. The flap, being bulky, necessitates thinning either during the initial operation or later, while the vastus lateralis muscle, nourished by the same pedicle, can be included as needed for various reconstructions.<sup>93</sup>

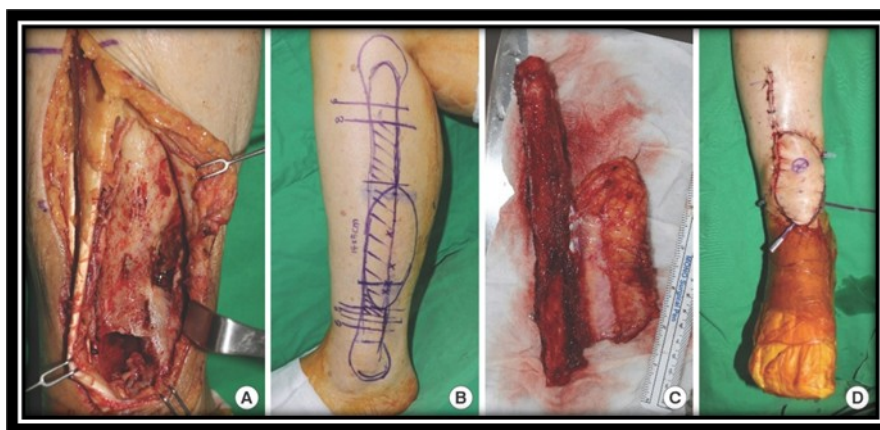


Figure 17: Osteofasciocutaneous Fibula Free Flap

**Pharynx:** For the reconstruction of pharyngeal defects, the choice of technique depends on the location and size of the defect. For anterior wall defects, options include the free anterolateral thigh flap, pectoralis major myocutaneous flap, and free radial forearm flap. If the pectoralis major myocutaneous flap fails, the free anterolateral thigh flap is recommended for addressing defects involving the neck and intraoral mucosa. For circumferential defects, suitable methods are the free anterolateral thigh flap, free radial forearm flap, and free jejunal flap.<sup>94</sup>

**Anterolateral Thigh Flap for Anterior Wall Defects of the Pharynx:** The anterolateral thigh flap must be thinned during the initial surgery to achieve a secure closure. Proximally, the flap is connected to the base of the tongue and posterior pharyngeal mucosa. The anterior wall of the cervical esophagus is split longitudinally for approximately 1.5 cm to facilitate a spatulated distal anastomosis, which enlarges the anastomosis and minimizes the risk of ring stricture. A triangular extension is created at the distal edge of the flap and inserted into the longitudinal split of the esophagus to complete the spatulation. For pharyngeal reconstruction, it is preferable to raise the anterolateral thigh flap with two perforators and two distinct skin paddles. One skin paddle is used for pharyngeal reconstruction, while the second paddle is oriented outward to cover the neck and allow for flap monitoring. If two skin paddles are not feasible, flap monitoring can be accomplished using an implantable Doppler or a handheld Doppler device.<sup>95</sup>

**Future Research:** Looking ahead, ongoing innovation in oral reconstruction is expected to focus on several key areas. Future research should concentrate on refining flap techniques to further enhance surgical precision and patient-specific outcomes. This includes optimizing current methods and exploring new technologies to reduce complications and recovery times. Further advancements in imaging and navigational systems are anticipated to improve flap design and placement, while emerging trends in biomaterials and tissue engineering offer promising avenues for reducing donor site morbidity and enhancing tissue integration. Additionally, the exploration of regenerative medicine and stem cell therapy could revolutionize reconstructive surgery by promoting tissue regeneration and shortening recovery periods. Continuous research and development will be crucial in evolving oral reconstruction strategies to meet the diverse needs of patients with

oral and maxillofacial conditions. Staying informed about these advancements and incorporating the latest techniques will be essential for professionals in the field to maintain high standards of care and achieve optimal patient outcomes.<sup>96</sup>

### **III. Conclusion:**

The field of oral reconstruction has experienced significant advancement due to the introduction of innovative flap techniques and methodologies. These developments have markedly enhanced the precision and outcomes of reconstructive surgeries, leading to improved patient recovery and quality of life. The integration of advanced imaging technologies and sophisticated flap designs has transformed oral reconstruction practices, enabling more tailored and effective solutions for complex oral defects through techniques like perforator flaps, free flaps, and tissue engineering. These innovations reflect a broader trend towards personalized and minimally invasive approaches, leveraging progress in surgical technology, material science, and regenerative medicine to achieve superior functional and aesthetic results. The current classification system assists in selecting and designing specific free flaps for addressing various oral and maxillofacial defects, with perforator-based, branch-based ALT flaps, and carefully designed fibular flaps proving effective for different defect types. Nonetheless, it is crucial to account for anatomical variations in patients to optimize surgical outcomes.

#### **Financial support and sponsorship Nil**

**Conflicts of interest** There are no conflicts of interest

#### **References**

1. Wong C & Wei F. Microsurgical free flap in head and neck reconstruction. *Head. Neck.* 2010; 32, 1236–1245.
2. Liu WW, Yang A & Ou YD. The harvesting and inseting of a chimeric anterolateral thigh flap to reconstruct through and through cheek defects. *Int. J. Oral. Maxillofac. Surg.* 2011; 40, 1421–1423.
3. Liu WW, Zhang CY, Li JY, Zhang MF & Guo ZM. A novel classification system for the evaluation and reconstruction of oral defects following oncological surgery. *Oncol. Lett.* 2017; 14, 7049–7054.
4. Wehage IC & Fansa H. Complex reconstructions in head and neck cancer surgery: decision making. *Head. Neck Oncol.* 2011; 3, 14.
5. Huang W, Chen H, Wei F, Cheng M & Schnur DP. Chimeric flap in clinical use. *Clin. Plast. Surg.* 2003; 30, 457–467.
6. Lin Y, Lin C & Wei F. More degrees of freedom by using chimeric concept in the applications of anterolateral thigh flap. *J. Plast. Reconstr. Aesthet. Surg.* 2006; 59, 622–627.
7. Hallock, GG. The complete nomenclature for combined perforator flaps. *Plast. Reconstr. Surg.* 2011; 127, 1720–1729.
8. Zimany A. A bilobed flap. *Plastic Reconstr Surgery.* 1953; 11:424.
9. Martin D, Legallard Ph, Bakhach J, Hu W, Baudet J. Reverse flow YV pedicle extension: a method of doubling the arc of rotation of a flap under certain conditions. *Ann Chir Plast Esthet.* 1994; 39:403–414.
10. Bar-dach J. Local flaps and free skin grafts in head and neck reconstruction. *Plastic and Reconstructive Surgery.* 1992; 90 (6): 1117.
11. Kuo, Y. et al. Versatility of the anterolateral thigh flap with vascularized fascia lata for reconstruction of complex soft-tissue defects: clinical experience and functional assessment of the donor site. *Plast. Reconstr. Surg.* 2009; 124, 171–180.
12. Wong, C. S., Wei, F., Fu, B., Chen, Y. & Lin, J. Z. Alternative vascular pedicle of the anterolateral thigh flap: the oblique branch of the lateral circumflex femoral artery. *Plast. Reconstr. Surg.* 2009; 123, 571–577.
13. Masià-Gridilla J, Gutiérrez-Santamaría J, Álvarez-Sáez I, Pamiás-Romero J, Saez-Barba M, Bescós-Atin C. *Cancers (Basel)*. Outcomes Following Autologous Fat Grafting in Patients with Sequelae of Head and Neck Cancer Treatment. 2023; 15(3):800.
14. Ashtiani AK, Emami SA, Rasti M. Closure of complicated palatal fistula with facial artery musculomucosal flap. *Plast Reconstr Surg.* 2005; 116:381–386. discussion 387–388.
15. Roan, T. et al. A modified free chimeric osteocutaneous fibular flap design for head and neck reconstruction: experience on a series of 10 cases. *Microsurgery.* 2013; 33, 439–446.
16. Papadimas D, Paraskeuopoulos T & Anagnostopoulou, S. Cutaneous perforators of the peroneal artery: Cadaveric study with implications in the design of the osteocutaneous free fibular flap. *Clin. Anat.* 2009; 22, 826–833.
17. Wong C & Tan B. Three-step approach to the harvest of the fibula osteoseptocutaneous flap. *J. Trauma.* 2010; 69, 459–465.

18. Wong C, Ong Y, Chew K, Tan B & Song C. The fibula osteoseptocutaneous flap incorporating the hemisoleus muscle for complex head and neck defects: anatomical study and clinical applications. *Plast. Reconstr. Surg.* 2009; 124, 1956–1964.
19. Cheng, M. et al. Osteomyocutaneous peroneal artery-based combined flap for reconstruction of composite and en bloc mandibular defects. *Head. Neck.* 2009; 31, 361–370.
20. Mathes SJ, Nahai F. Classification of the vascular anatomy of muscles: experimental and clinical correlation. *Plast Reconstr Surg.* 1981; 67:177–187.
21. Liu WW & Guo ZM. Reconstruction of Wide-apart Double Defect Using a Branch-based Chimeric Anterolateral Thigh Flap. *Plast. Reconstr. Surg. Glob. Open.* 2014; 2:e96.
22. Chien CY, Hwang CF, Chuang H C, Jeng SF, Su CY. Comparison of radial forearm free flap, pedicled buccal fat pad flap and split-thickness skin graft in reconstruction of buccal mucosal defect. *Oral Oncol.* 2005; 41:694–697.
23. Amin M A, Bailey B M, Swinson B, Witherow H. Use of the buccal fat pad in the reconstruction and prosthetic rehabilitation of oncological maxillary defects. *Br J Oral Maxillofac Surg.* 2005; 43:148–154.
24. Poeschl P W, Baumann A, Russmueller G, Poeschl E, Klug C, Ewers R. Closure of oroantral communications with Bichat's buccal fat pad. *J Oral Maxillofac Surg.* 2009; 67:1460–1466.
25. Pribaz J J, Stephens W, Crespo L, Gifford G. A new intraoral flap: facial artery musculomucosal (FAMM) flap. *Plast Reconstr Surg.* 1992; 90:421–429.
26. Bakamjian VY. A technique for primary reconstruction of the palate after radical maxillectomy for cancer. *Plast Reconstr Surg.* 1963; 31:103.
27. Ayad T, Kolb F, De Monés E, Mamelle G, Temam S. Reconstruction of floor of mouth defects by the facial artery musculo-mucosal flap following cancer ablation. *Head Neck.* 2008; 30:437–445.
28. Neligan PC. Strategies in lip reconstruction. *Clin Plast Surg.* 2009; 36(3):477–485.
29. Worthen EF. Repair of forehead defects by rotation flaps. *Plast Reconstr Surg.* 1976; 57:204.
30. Guriek A, Miller MJ, Jacob RF. Functional result of osteointegrated dental implants into free fibula for mandible reconstruction. *Plast Reconstr Surg.* 1998; 102; 680–688.
31. Wells MD, Luce EA. Reconstruction of midfacial defects after surgical resection of malignancies. *Clin Plast Surg.* 1995; 22(1):79–89.
32. Clauser L, Curioni C, Spanio S. The use of the temporalis muscle flap in facial and craniofacial reconstructive surgery. A review of 182 cases. *J Craniomaxillofac Surg.* 1995; 23:203–214.
33. Pinto FR, de Magalhães RP, Capelli F de A, Brandão L G, Kanda J L. Pedicled temporoparietal galeal flap for reconstruction of intraoral defects. *Ann Otol Rhinol Laryngol.* 2008; 117:581–586.
34. Urken M L, Biller H F. Pectoralis major. In: In: Urken ML, Cheney ML, Sullivan MJ, Biller HF, editor. *Atlas of Regional and Free Flaps for Head and Neck Reconstruction.* New York, NY: Raven Press; 1995: 3–28.
35. Milenović A, Virag M, Uglesić V, Aljinović-Ratković N. The pectoralis major flap in head and neck reconstruction: first 500 patients. *J Craniomaxillofac Surg.* 2006; 34:340–343.
36. Vartanian J G, Carvalho A L, Carvalho S MT, Mizobe L, Magrin J, Kowalski L P. Pectoralis major and other myofascial/myocutaneous flaps in head and neck cancer reconstruction: experience with 437 cases at a single institution. *Head Neck.* 2004; 26:1018–1023.
37. Urken M L. Trapezius system. In: In: Urken ML, Cheney ML, Sullivan MJ, Biller HF, editor. *Atlas of Regional and Free Flaps for Head and Neck Reconstruction.* New York, NY: Raven Press; 1995. pp. 29–48.
38. Haas F, Weiglein A, Schwarzl F, Scharnagl E. The lower trapezius musculocutaneous flap from pedicled to free flap: anatomical basis and clinical applications based on the dorsal scapular artery. *Plast Reconstr Surg.* 2004; 113:1580–1590.
39. Chen WL, Li JS, Yang ZH, Huang ZQ, Wang JQ. Extended vertical lower trapezius island myocutaneous flap for repairing extensive oropharyngeal defects. *J Oral Maxillofac Surg.* 2009; 67:1349–1353.
40. Baker SR. Local cutaneous flaps. *Otolaryngologic clinics of North America,* 1994; 27(1): 139–159.
41. Cutting C. Critical closing and perfusion pressures in flap survival. *Annals of plastic surgery.* 1982; 9 (6): 524.
42. Murakami CS & Nishioka GJ. Essential concepts in the design of local skin flaps. *Facial Plastic Surgery Clinics of North America.* 1996; 4: 455–468.
43. Karonidis A. & Yao SF. Chimeric anterolateral thigh free flap for head and neck reconstruction. *J. Plast. Reconstr. Aesthet. Surg.* 2009; 62: e85–e86.
44. Wallace CG, Tsao C & Wei F. Role of multiple free flaps in head and neck reconstruction. *Curr. Opin. Otolaryngol. Head. Neck Surg.* 2014; 22: 140–146.
45. Calhoun KH, Seikaly H, & Quinn FB. Teaching paradigm for decision making in facial skin defect reconstructions. *Archives of Otolaryngology–Head & Neck Surgery.* 1998; 124(1): 60–66.
46. Millard R. *Principles of plastic surgery.* Boston: Little, Brown; 1986:250–350.

47. Beasley NJ, Gilbert RW, Gullane PJ, et al. Scalp and forehead reconstruction using free revascularized tissue transfer. *Arch Facial Plast Surg.* 2004; 6:16-20.
48. Orticochea M. Four flap scalp reconstruction technique. *Br J Plast Surg.* 1967; 20:159-171.
49. Wong, C. & Wei, F. Anterolateral thigh flap. *Head. Neck .* 2010; 32: 529–540.
50. Cutler NL, Beard CA. Method for partial and total upper lid reconstruction. *Am J Ophthalmol.* 1955; 39:1.
51. Ariyan S. The pectoralis major myocutaneous flap. A versatile flap for reconstruction in the head and neck. *Plast Reconstr Surg.* 1979; 63:73-81.
52. Hughes WL. *Reconstructive surgery of eyelids.* St Louis: Mosby, 1943.
53. Dean A, Alamillos F, García-López A, Sánchez J, Peñalba M. The buccal fat pad flap in oral reconstruction. *Head Neck.* 2001; 23:383–388.
54. McGregor IA. The temporal flap in intra-oral cancer: its use in repairing the post-excisional defect. *Br J Plast Surg.* 1963; 16:318.
55. Spinelli HM, Jelks GW. Periocular reconstruction: a systematic approach. *Plast Reconstr Surg.* 1993; 91(6):1017-1024.
56. Mustarde JC. *Repair and reconstruction of orbital region.* 2nd ed. Edinburg: Churchill Livingstone, 1980:150-160.
57. Herbert DC, Harrison RG. Nasolabial subcutaneous pedicled flap. *Rr J Plast Surg.* 1975; 28; 85.
58. Burget G, Menick F. *Aesthetic reconstruction of the nose.* St Louis, MO: Mosby; 1993:30-57.
59. Zitelli JA. The bilobed flap for nasal reconstruction. *Arch Dermatol.* 1989; 125:957.
60. Hagerty RF, Smith W. The nasolabial cheek flap. *Am Surg.* 1958; 24; 506.
61. Millard DR Jr. Reconstructive rhinoplasty for the lower half of nose. *Plast Reconstr Surg.* 1974; 53:133.
62. Pribaz J, Weiss D, Mulliken J, et al. Prelaminated free flap reconstruction of complex central facial defects. *Plast Reconstr Surg.* 1999; 104:357-365.
63. Jackson IT. *Local flaps in head and neck reconstruction,* 2nd ed. St Louis: Quality Medical; 2007:134-140.
64. Limberg AA. Design of local flaps. In Gibson T, editor. *Modern trends of plastic surgery (Vol. 2).* London: Butterworth; 1966; 38-61.
65. Kroll S, Reece G, Robb G, et al. Deep-plane cervicofacial rotation advancement flap for reconstruction of large cheek defects. *Plast Reconstr Surg.* 1994; 94:88.
66. Yang GF, Chen BJ, Gao YZ. The free forearm flap. *Chin Med J.* 1981; 61:4.
67. Fujimori R. Gate flap for the total reconstruction of the lower lip. *Br J Plast Surg.* 1980; 33(3):340-345.
68. Bakamjian VY, Poole M. Maxillofacial and palatal reconstruction with deltopectoral flap. *Br J Plast Surg.* 1977; 30:17.
69. Chow TL, Chan TT, Chow TK, et al. Reconstruction with submental flap for aggressive orofacial cancer. *Plast Reconstr Surg* 2007; 120:431-436.
70. Wilson JSP, Breach NM. Forehead skin flaps, Ch105. In Grabb's *Encyclopedia of flaps,* 3rd ed volume 1, Philadelphia, Lippincott Williams & Wilkins. 2009:294-305.
71. Soutar DS, McGregor IA. The radial forearm flap in intraoral reconstruction: the experience of 60 consecutive cases. *Plast Reconstr Surg.* 1986; 78:1-8.
72. Song YG, Chen GZ, Song YL. The free thigh flap: a new free flap concept based on the septocutaneous artery. *Br J Plast Surg.* 1984; 37:149-1598.
73. Bitter K. Bone transfer from iliac crest to maxillofacial defect by microsurgical technique. *J Maxillofac Surg.* 1980; 8:210.
74. Chen W L, Li J S, Yang Z H, Huang Z Q, Wang J U, Zhang B. Two submental island flaps for reconstructing oral and maxillofacial defects following cancer ablation. *J Oral Maxillofac Surg.* 2008; 66:1145–1156.
75. Szudek J, Taylor S M. Systematic review of the platysma myocutaneous flap for head and neck reconstruction. *Arch Otolaryngol Head Neck Surg.* 2007; 133:655–661.
76. Martin D, Pascal J F, Baudet J, et al. The submental island flap: a new donor site. Anatomy and clinical applications as a free or pedicled flap. *Plast Reconstr Surg.* 1993; 92:867–873.
77. Webster J. Crescentic peri-alar cheek excision for upper lip flap advancement with a short history of upper lip repair. *Plast Reconstr Surg.* 1955; 16:434-464.
78. Engel H, Huang JJ, Lin CY, et al. A strategic approach for tongue reconstruction to achieve predictable and improved functional and aesthetic outcomes. *Plast Reconstr Surg.* 2010; 126; 1967-1977.
79. Bakamjian VY, Souther SG. Use of temporal muscle flap for reconstruction after orbitomaxillary resections for cancer. *Plast Reconstr Surg.* 1975; 56:171.
80. Carroll CM, Pathak I, Irish J, et al. Reconstruction of total lower lip and chin defects using the composite radial forearm— palmaris longus tendon free flap. *Arch Facial Plast Surg.* 2000; 2(1):53-56.



81. Chang SC, Miller G, Halbert CF, et al. Limiting donor site morbidity by suprafascial dissection of the radial forearm flap. *Microsurgery*. 1996; 17:136-140.
82. Katsaros J, Schusterman M, Beppu M, et al. The lateral upper arm flap: Anatomy and clinical applications. *Ann Plast Surg*. 1984; 12:489.
83. Tessier P. *Eyelid reconstruction or blepharopoesis in plastic surgery of the orbit and eyelids*. New York: Mason; USA Inc, 1981.
84. Abbe R. A new plastic operation for the relief of deformity due to double harelip. *Plast Reconstr Surg*. 1968; 42(5):481-483.
85. Kurlakose MA, Loree TR. Sensate free radial forearm flap for tongue reconstruction; *Arch Otolaryngol Head and Neck Surg*. 2001; 127; 1463-1466.
86. Sullivan D. 'Staircase' closure of lower lip defects. *Ann Plast Surg*. 1978; 1:392-397.
87. Hidalgo DA. Fibula free flap: a new method of mandible reconstruction. *Plast Reconstr Surg*. 1989; 84:71-79.
88. Koh KS, Eom JS, Kirk I, et al. Pectoralis major musculocutaneous flap in oropharyngeal reconstruction: revisited. *Plast Reconstr Surg*. 2006; 118:1145-1149.
89. Wei FC, Seah CS, Tsai YC, et al. Fibula osteoseptocutaneous flap for reconstruction of composite mandibular defects. *Plast Reconstr Surg*. 1994; 93:294-304; discussion 305-306.
90. Larson DL. Tumours of the lips, oral cavity and oropharynx. In Mathes SJ editor. *Plastic surgery*. 2nd ed. volume 1. Philadelphia: Saunders Elsevier 2006:159-187.
91. Hsiao HT, Leu YS, Lin CC. Tongue reconstruction with free radial forearm flap after hemiglossectomy: a functional assessment. *J Reconstr Microsurg*. 2003; 19:137-142.
92. Cordeiro PG, Bacilious N, Schantz S, et al. The radial forearm osteocutaneous "sandwich" free flap for reconstruction of the bilateral subtotal maxillectomy defect. *Ann Plast Surg*. 1998; 40(4):397-402.
93. Phillips JH, Rechner B, Tompson BD. Mandibular growth following reconstruction using free fibula graft in paediatric facial skeleton. *Plast Reconstr Surg*. 2005; 116; 419-426.
94. Achebe JU, Okwesili OR, Uche EO. Pedicled Radial Forearm Flap in Reconstruction of Complex Defects in the Craniofacial Region. *J West Afr Coll Surg*. 2023; 13(4):111-115.
95. Patel RS, Higgins K.M, Enepekides DJ & Hamilton PA. Clinical utility of colour flow Doppler ultrasonography in planning anterolateral thigh flap harvest. *J. Otolaryngol. Head. Neck Surg*. 2010; 39, 566–571.
96. Nokovitch L, Davrou J, Bidault F, Devauchelle B, Dakpé S, Vacher C. Vascular anatomy of the free fibula flap including the lateral head of the soleus muscle applied to maxillo-mandibular reconstruction. *Surg Radiol Anat*. 2019; 41(4):447-454.