

# Finger Pulp Injuries Treated With Needle And Figure Of 8 Suturing

Dr. Arunagiri S<sup>1</sup>, Dr. Shyam Mohan\*<sup>2</sup>, Dr. Vinod R<sup>3</sup>, Dr. L Senthil<sup>4</sup>,  
Dr. Rahul Rajeendran<sup>5</sup>

Postgraduate<sup>1</sup>, Senior Resident\*<sup>2</sup>, Assistant Professor<sup>3</sup>, Professor & Hod<sup>4</sup>, Postgraduate<sup>5</sup> Department Of  
Orthopaedics, Acs Medical College & Hospital, Chennai

## Abstract

**Background:** injuries to the finger pulp are encountered in occupational, household work and rta. in the present study, fingertip injuries were treated by reducing the fracture fragments, repositioning the nail plate in the nail fold, and securing it with the needle vertical figure of eight tension band sutures.

**Objective:** to know the clinical outcomes of finger pulp injuries treated with 23g needle fixation and figure of 8 suturing.

**Methodology:** 15 patients were included in the study. The study was done at chennai, tamil nadu, a.c.s. Medical college and hospital on patients with finger pulp injuries in casualty as an outpatient. This interventional study was done for 12 months. All patients were followed up for 6 months.

**Results:** most of the patients were aged above 18. Most of the patients were males. The thumb finger was most commonly involved. The right side is more commonly affected. All patients were given antibiotics orally for 2 weeks. Fracture healing happened in 6 weeks for most of the patients. Union was achieved in 8 to 9 weeks for most of the patients.

**Conclusion:** using an 23g needle instead of k-wire fixation for treating associated fractures of the distal phalanx has enhanced versatility and yielded good outcomes. This approach also circumvents the formal repair of the nail bed, promoting smooth healing of the injury.

**Keywords:** fingertip injuries, eight tension band suture, distal phalanx fracture, reposition, needle fixation

Date of Submission: 07-09-2024

Date of Acceptance: 17-09-2024

## I. Introduction

Injuries to dorsal elements of fingertip are seen in around 15-24 percent of fingertip injuries.<sup>1</sup> Among all accidents reported to the emergency, around 10% involve the hand. Associated fractures of the phalanx are seen in around 50% of such injuries.

<sup>2</sup> Given the vital role of the finger in daily activities, the effect of an amputation can be devastating.<sup>3,4</sup> Volar surface is rich in Pacinian cells, Meissner's corpuscles and Merkel cells that can provide touch and feel sensations. The dorsal surface is made of nail fold, nail bed and nail plate that protects the pulp. Blunt trauma is the common cause of finger-tip injuries.<sup>5</sup> But in occupational setup, handling of sharp instruments and power tools increased the incidence of lacerating injuries to the fingertip. These include household and work-related injuries. Lacerations to fingers constitute for around nearly half of non-work-related injuries.<sup>6</sup>

Suggested treatment of dorsal disruptions of fingertip is subungual hematoma evacuation, proper repair of nail bed, reduction and stabilization of fractures and approximation of volar pulp with repositioning of nail. Primary repair of nail bed lacerations is not usually required as there is a firm natural bond between nail plate, matrix and periosteum of the distal phalanx. If nail plate is partially avulsed but still attached to the matrix, exploring nail bed is challenging and can lead to poor results.<sup>8-9</sup> Bindra initially described the tension band suturing technique which yielded good results. Patankar modified the technique using a k-wire to fix the associated fractures.<sup>10,11</sup>

In the present study, fingertip injuries were treated by reducing the fracture fragments, repositioning the nail plate in the nail fold, and secured it with the vertical figure of eight tension band sutures.

## Objective:

To know the outcomes of finger pulp injuries treated with 23G needle and figure of 8 suturing.

## II. Materials And Methods

**Study site:** Department of Orthopedics, A.C.S Medical College and Hospital, Chennai, Tamilnadu, India

**Study duration:** 12 months: Jan 2023 to Jan 2024

**Sample size:** 15

**Type of study:** Interventional study- All patients with finger pulp injuries underwent treatment.

**Inclusion criteria:**

- Male and female subjects with occupational and non-occupational injuries admitted in casualty.
- Patients aged above 18 years.
- Partial amputation of distal phalanx
- Patients with Fingertip Injuries
- Patients presenting within 24 hours- fresh injury.

**Exclusion criteria:**

- Patients with poor refilling time
- Patients with complete amputation

**Methodology:**

Wound was thoroughly examined, and X-ray was taken for hand. After examination, the procedure was done in Emergency Procedure Room. A thorough wash was given with normal water with soap solution to remove any contamination. Distal phalanx stabilization was done using 23 G needle. Only one attempt was made to prevent soft tissue and neurovascular injury. 23 G needle was inserted at the tip of distal phalanx. Nail was repaired using figure of 8 suturing technique. All patients were treated as day care procedure on outpatient basis. All patients were advised with oral antibiotics after the procedure. Suture and needle were removed after 3 weeks.

**Statistical analysis:** Data were analyzed using SPSS 23.3 software. Mean, SD, percentages, and frequencies were used.

**Ethical considerations:** Informed consent was taken from every patient participated in the study.

**III. Results**

**Age distribution:**

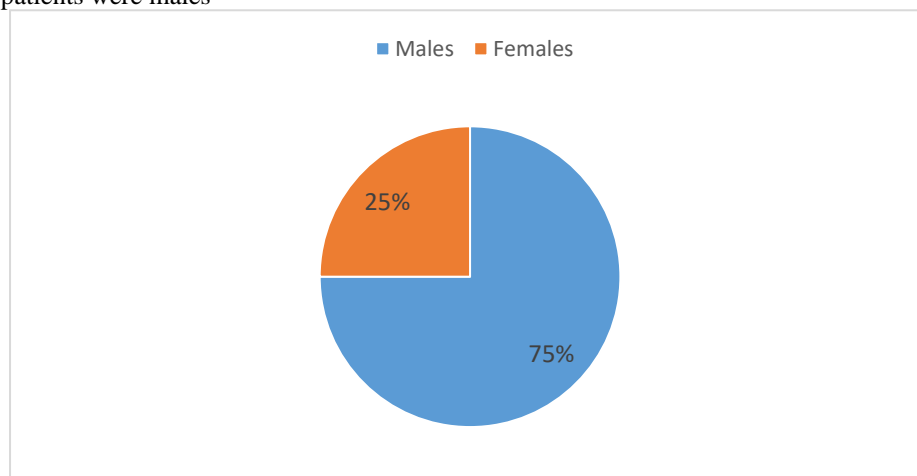
Most of the patients were aged 21 to 30 years.

Age group	No of patients	Percent of patients
21 to 30 years	6	40%
31 to 40 years	3	20%
41 to 50 years	4	26.67%
Above 50 years	2	13.33%

**Table 1: Age distribution of patients**

**Gender:**

Most of the patients were males



**Graph 1: Gender distribution of patients**

**Finger involved:**

Thumb finger was most commonly involved.

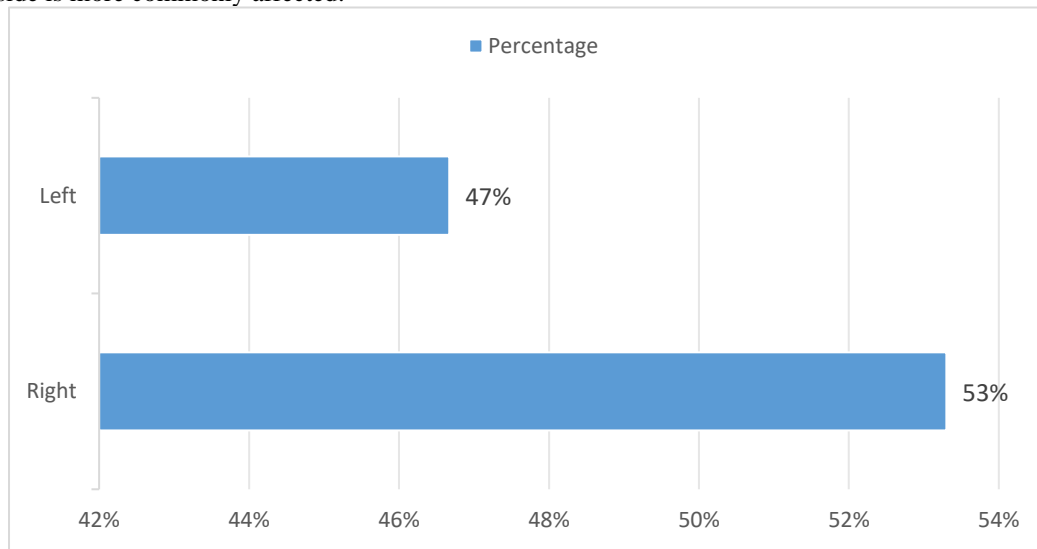
Finger	No of patients	Percent of patients
Thumb	6	40%
Ring	2	13.3%
Index	1	6.67%
Little	4	26.6%
Middle	2	13.3%

**Table 2: Finger involved.**

None of the patients underwent previous surgery on the finger.

**Laterality:**

Right side is more commonly affected.



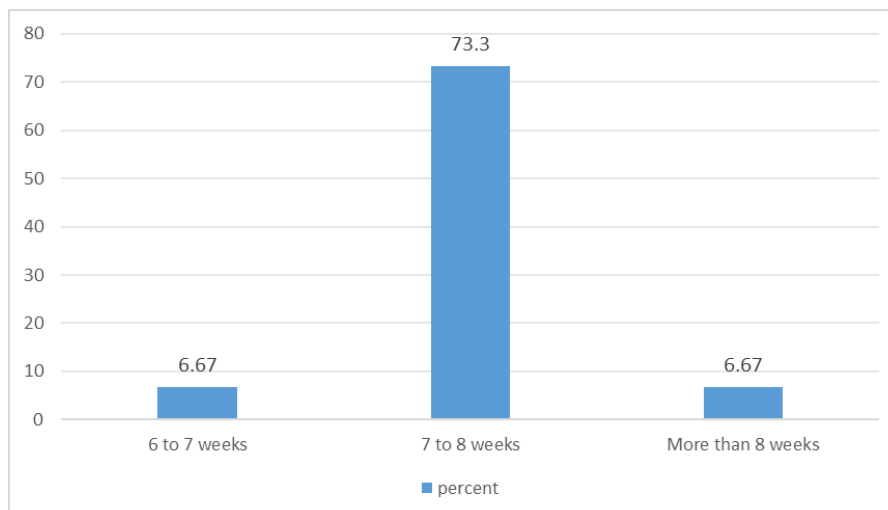
**Graph 2: Laterality of finger involved.**

No needle breakage occurred during the procedure in any patient. All procedures were done by a single surgeon under digital block. Follow up was done for 6 months. All patients were given antibiotics orally for 3 days.

**Infection:** It was not seen in any patient.

**Time for fracture consolidation:**

Fracture consolidation happened in 6 to 8 weeks for most of the patients.



**Graph 3: Time for consolidation**

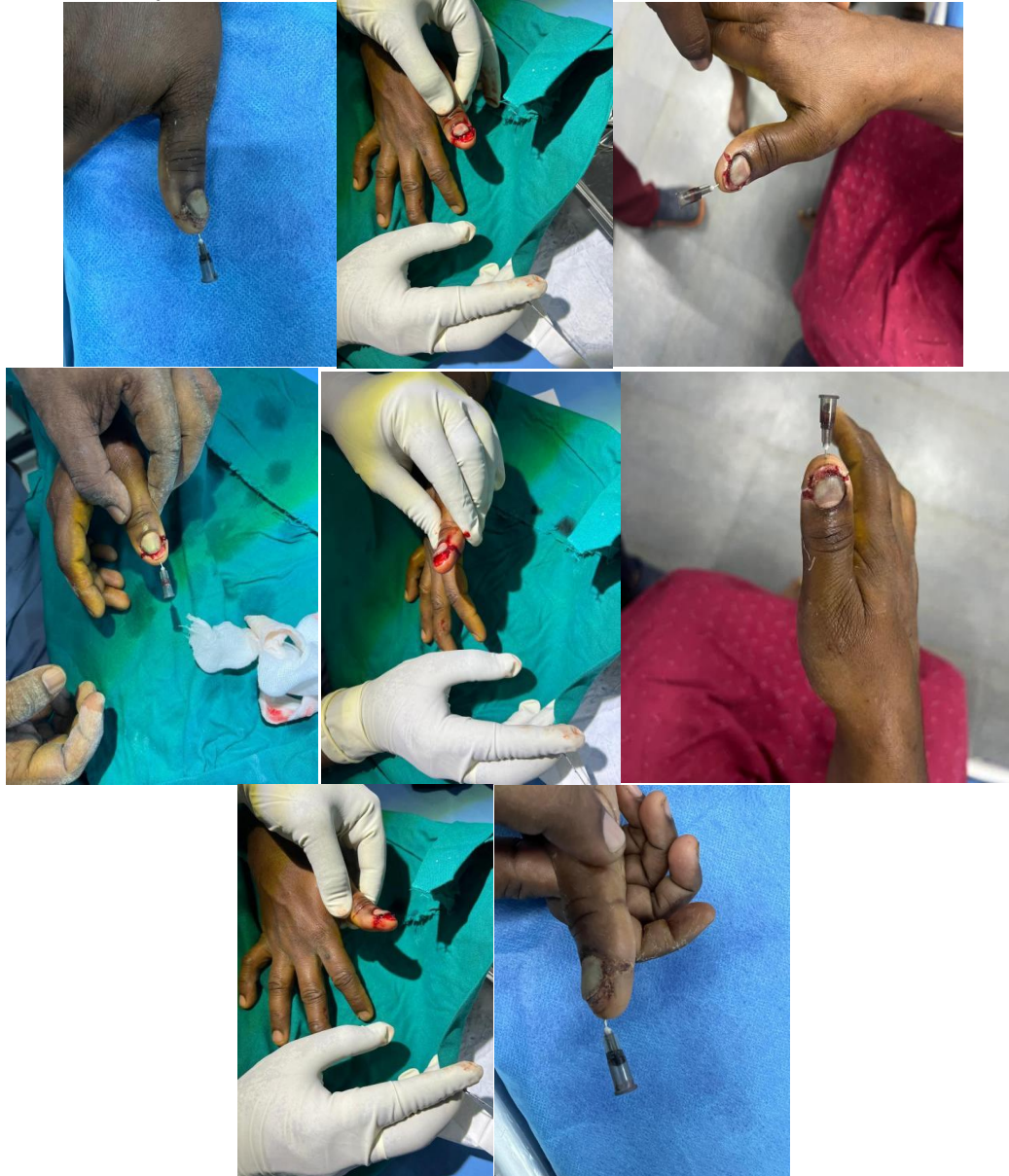**Union:**

Union was achieved in 8 to 9 weeks for most of the patients.

Union time	No of patients	Percent of patients
7 to 8 weeks	2	13.33%
8 to 9 weeks	12	75%
Above 9 weeks	1	6.67%
No union	Nil	0%

**Table 3: Time for fracture union**

**Images Of Our Study**



**IV. Discussion**

The present study was done on 15 patients with finger pulp injuries. The study was done to know the clinical outcomes of finger pulp injuries treated with 23G needle and figure of 8 suturing.

All patients were discharged in stable condition. Most of the patients were aged above 18 years. Most of the patients were males. Thumb finger was most commonly involved. Right side is more commonly affected. All patients were given antibiotics orally for 2 weeks. Fracture healing happened in 6 weeks for most of the patients. Union was achieved in 8 to 9 weeks for most of the patients.

In the study done by **Takamoto et al**-8 patients were included. They underwent Needle-in-needle Pinning Technique with the help of Disposable Hypodermic Needles.<sup>12</sup>

They were having Fractures of Distal Phalanx. Mean age was 45 years. Thumb was most commonly involved finger, similar to the present study. Needle breakage happened in one patient, unlike in the present study, where there is no needle breakage. Uneventful union was seen in 7 cases. Mean time to radiographic fracture consolidation with bridging callus was 7 and in the present study, it was 7 to 8 weeks for most of the patients. All patients showed fully pain-free digits during follow-up, and no patient needed further intervention, similar to the present study.

**Reid et al.** showed that in patients aged more than 15 years and males were about 4 to 8 times more commonly affected compared to females.<sup>13</sup>

**Royen et al** did a retrospective study. 24 distal phalanx fractures were treated with k-wire fixation and fluoroscopic control. 25 distal phalanx fractures were treated with hypodermic needle fixation with no fluoroscopic control. Results showed no significant difference in healing time, or union between groups. Loosening was significantly more commonly seen in hypodermic needle group, without affecting clinical or radiographic outcome.<sup>14</sup> Loosening was not seen in the present study. No infections were seen in both groups. In the present study also, infection was not seen in any patient.

The authors concluded that treatment of displaced distal phalanx fractures with hypodermic needle fixation provides good results. It was a safe procedure and might reduce operative time, and radiation exposure for both surgeon and patients.

**LeBlanc et al.** found a superficial infection rate of around 0.4% in carpal tunnel surgery Similar results were seen for k-wire fixation performed in the emergency room and in the treatment room.<sup>15-17</sup>

## V. Conclusion

The tension band suturing technique provides simplicity, effectiveness, and a short learning curve. Using an 23G needle instead of k-wire fixation for treating associated fractures of the distal phalanx has enhanced versatility and yielded good outcomes. This approach also circumvents the formal repair of the nail bed, promoting smooth healing of the injury.

Conducting this procedure in a treatment room is deemed safe and could reduce operative time, institutional costs, and radiation exposure for both surgeons and patients. More research into both conservative and surgical treatments is warranted.

Sponsor: Nil

Conflicts of interest: Nil

## References

- [1] Chang J, Vernadakis Aj, McClellan Wt. Fingertip Injuries. *Clin Occup Environ Med.* 2006; 5(2):413-22,
- [2] Zook Eg, Brown Re. The Perionychium. In: Green Dp Ed. *Operative Hand Surgery.* 3rd Ed. New York: Churchill Livingstone, 1993, 1283-1287.
- [3] Boyle D, Parker D, Larson C, Pessoa-Brandão L. Nature, Incidence, And Cause Of Work-Related Amputations In Minnesota. *American Journal Of Industrial Medicine.* 2000; 37(5):542-50.
- [4] Sears Ed, Shin R, Prosser La, Chung Kc. Economic Analysis Of Revision Amputation And Replantation Treatment Of Finger Amputation Injuries. *Plast Reconstr Surg.* 2014; 133(4):827-40.
- [5] Reid Dbc, Shah Kn, Eltorai Aem, Got Cc, Daniels Ah. Epidemiology Of Finger Amputations In The United States From 1997 To 2016. *Journal Of Hand Surgery Global Online.* 2019; 1(2):45-51.
- [6] Ramirez Eg, Hoyt Ks. Management Of Hand Injuries: Part Ii. *Adv Emerg Nurs J.* 2016; 38(4):266-78.
- [7] Satku M, Puhaindran Me, Chong Aks. Characteristics Of Fingertip Injuries In Children In Singapore. *Hand Surg.* 2015; 20(3):410-4.
- [8] Roser Se, Gellman H. Comparison Of Nail Bed Repair Versus Nail Trephination For Subungual Hematomas In Children. *J Hand Surg Am.* 1999; 24(6):1166-70.
- [9] Dacruz Dj, Slade Rj, Malone W. Fractures Of The Distal Phalanges. *J Hand Surg Br.* 1988; 13(3):350-2.
- [10] Bindra Rr. Management Of Nail-Bed Fracture-Lacerations Using A Tension-Band Suture. *J Hand Surg Am.* 1996; 21(6):1111-3.
- [11] Patankar Hs. Use Of Modified Tension Band Sutures For Fingernail Disruptions. *J Hand Surg Eur Vol.* 2007; 32(6):668-74.
- [12] Takamoto K, Takano S, Takano K. Needle-In-Needle Pinning Technique Using Disposable Hypodermic Needles For Fractures Of Distal Phalanx With Dorsal Disruption. *Tech Hand Up Extrem Surg.* 2021 May 12;26(1):42-46. Doi: 10.1097/Bth.000000000000355. Pmid: 33973945; Pmcid: Pmc8876423.
- [13] Reid Dbc, Shah Kn, Eltorai Aem, Got Cc, Daniels Ah. Epidemiology Of Finger Amputations In The United States From 1997 To 2016. *Journal Of Hand Surgery Global Online.* 2019; 1(2):45-51
- [14] Van Royen K, Ozyurekoglul T, Lozano-Garza Ca, Graham D. Hypodermic Needle Fixation Without Fluoroscopy Versus K-Wire Fixation With Fluoroscopy For Distal Phalangeal Fractures: A Comparative Study. *Eur J Orthop Surg Traumatol [Internet].* 2021;31(4):705-10.
- [15] Leblanc Mr, Lalonde Dh, Thoma A, Bell M, Wells N, Allen M, Chang P, Mckee D, Lalonde J. Is Main Operating Room Sterility Really Necessary In Carpal Tunnel Surgery? A Multicenter Prospective Study Of Minor Procedure Room Field Sterility Surgery. *Hand.* 2011; 6:60-63
- [16] Garon Mt, Massey P, Chen A, Carroll T, Nelson Bg, Hollister Am. Cost And Complications Of Percutaneous Fixation Of Hand Fractures In A Procedure Room Versus The Operating Room. *Hand.* 2018;13:428-434 11.
- [17] Starker I, Eaton Rg. Kirschner Wire Placement In The Emergency Room. Is There A Risk? *J Hand Surg Br.* 1995; 20:535-8