

Gartner Duct Cyst In A Pregnant Woman: A Case Report

Snigdhamayee Panda, Santosh Kumar Behera, Ipsita Mohanty

Hitech Medical College And Hospital, Bhubaneswar

Abstract

Gartner's duct cyst is an unusual vaginal cyst that develops from the Gartner's duct, the residual embryonic structure of the caudal end of the mesonephric duct in females. Often discovered incidentally during routine pelvic exams on the anterior or lateral vaginal wall, these cysts typically exhibit no symptoms. Although the occurrence of Gartner's duct cysts during pregnancy or at birth is exceedingly rare and has been scarcely documented in the literature, we encountered a pregnant patient who was referred to our hospital due to a protruding vaginal mass causing obstruction in the birth canal. Diagnosis was established through typical clinical examination and radiological findings, and after draining the Gartner's duct cyst, a normal vaginal delivery was successfully performed.

Date of Submission: 05-02-2025

Date of Acceptance: 15-02-2025

I. Introduction

The Gartner's duct, a vestige of the Wolffian duct, develop cystic dilatation due to persistent glandular epithelial secretions, leading to the formation of Gartner's duct cysts (GDC). Typically found along the anterolateral wall of the proximal third of the vagina (1). GDC may also coincide with abnormalities of the metanephric development. Notably, reports indicate that ectopic ureters, apart from establishing direct connections with the vagina and introitus, can communicate with GDC, resulting in urinary incontinence (2). In the classification of female congenital malformations of the genitourinary tract, the latest system by the European Society for Human Reproduction and Embryology / European Society for Gynaecological Endoscopy (ESHRE/ ESGE) categorizes Müllerian anomalies based on their anatomical status, with uterine, cervical, and vaginal anomalies being independently classified. An isolated GDC is classified as UO (Normal uterus) / CO (Normal Cervix) / V2 (Longitudinal non-obstructing vaginal septum) according to the ESHRE/ESGE system. Additionally, a GDC may be part of a complex distal mesonephric anomaly, such as unilateral renal agenesis and ipsilateral blind hemivagina syndrome, which would be classified as U3a (partial bicorporeal uterus) / C3 (unilateral cervical aplasia) / V2 (longitudinal obstructing vaginal septum) along with associated non-Müllerian anomalies (ectopic ureter) (3,4). While the majority of patients remain asymptomatic, those who do exhibit symptoms commonly experience dyspareunia, pelvic pain, a bulging pelvic mass, and urinary incontinence. The 2015 Thessaloniki consensus on the diagnosis of female genital anomalies, presented by ESHRE/ESGE, advocates the use of gynecological examination and 2D ultrasound as primary diagnostic tools for asymptomatic cases, widely acknowledged as suitable for most scenarios. In instances involving symptomatic complex anomalies, the consensus recommends 3D ultrasound imaging. Despite magnetic resonance imaging (MRI) offering superior diagnostic potential, its application is discouraged due to cost implications. However, it is proposed for investigating urinary anomalies during patient follow-up and for strategic planning in complex elective surgeries (5,6).

II. Case Report

A 30-year-old woman, primigravida, was brought to our Emergency Department at 39 weeks of gestation with a primary diagnosis of a substantial vaginal mass obstructing the birth canal, rendering vaginal delivery impossible. Notably, she had no history of prior vaginal trauma, surgery, or any abnormal findings during past medical history or antenatal screening tests. Upon fetal ultrasound examination, a singleton live fetus was observed in cephalic presentation, with an estimated fetal weight of 3870 grams. During digital vaginal examination, a dilated cervix of 7 centimeters with 70% effacement and intact membranes was noted. A speculum examination revealed a solitary, tense cyst measuring approximately 5 centimeters in diameter along the lateral vaginal wall (**Fig. 1**). Transvaginal ultrasound displayed an anechoic cyst measuring 45 × 23 × 40 millimeters within the left vaginal wall, consistent with Gartner's duct cyst (**Fig. 2-3**). Subsequent to admission to the labor and delivery ward, the patient underwent spontaneous labor with her informed consent. Once the cervix was fully dilated and effaced, the patient was positioned in lithotomy, and a 10 French drainage catheter was inserted into the cyst under local anesthesia. Following successful drainage of

the cyst, a normal vaginal delivery was performed without any complications (**Fig. 4**). Informed consent was obtained from the patient for the publication of the case report.

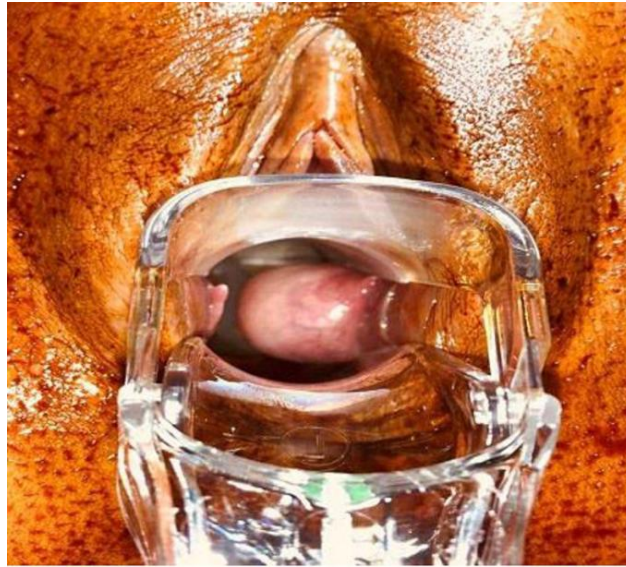

Fig. 1 Cyst in the lateral vaginal wall

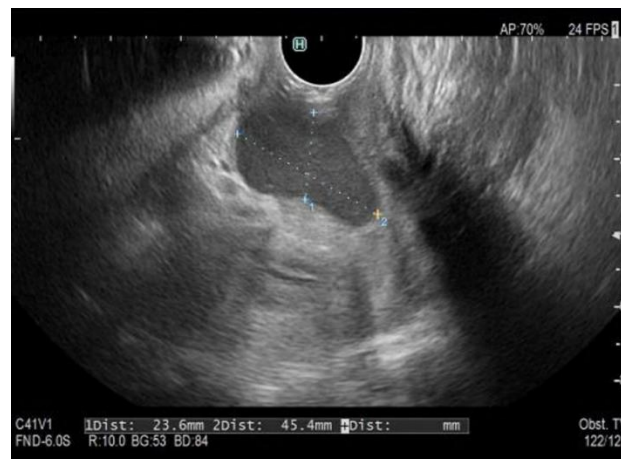


Fig. 2 Transvaginal Ultrasound images

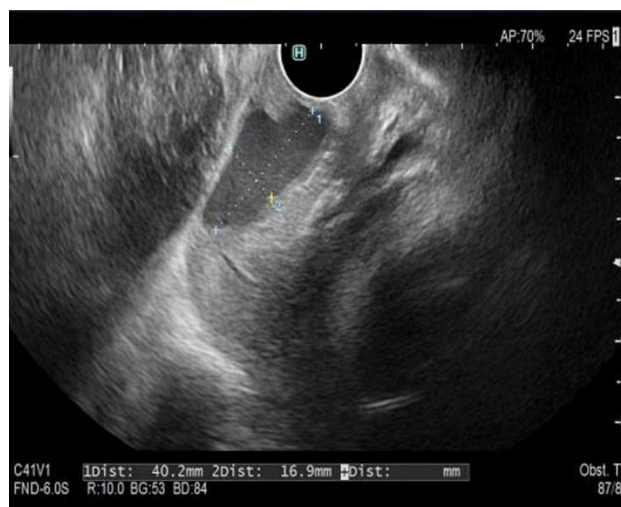

Fig. 3 Transvaginal Ultrasound images

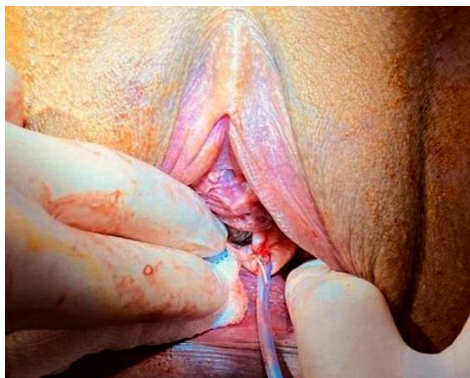

Fig. 4 Drainage catheter placing into the cyst

III. Discussion

During the intricate and evolving embryologic development of the female genital tract, the identification of a female genital malformation can be either an isolated Müllerian anomaly or part of a broader spectrum of anomalies (7). Therefore, an initial evaluation of Gartner's duct cysts (GDC) should encompass a comprehensive patient history and physical examination. Imaging modalities such as MRI, computed tomography (CT), and ultrasonography (US) are valuable tools for further characterizing the lesion.

For definitive treatment of GDC, complete cyst excision is recommended, with the diagnosis confirmed through pathological examination. However, the current literature lacks a consensus regarding the most optimal surgical approach or conservative treatment and follow-up strategies. There exist successful case reports and series illustrating both surgical management and conservative treatment with follow-up (5,8).

In our specific case, with the primary objective of facilitating the birth of a woman with a vaginal mass, our approach was guided by physical examination findings, the cyst's typical anatomical location, and ultrasound assessment. The strategy involved draining the cyst by inserting a simple catheter to enable a safe vaginal birth for both the mother and the newborn. The cytological examination of clear cyst fluid, revealing degenerated red blood cells, a few lymphocytes and polymorphonuclear leukocytes, with squamous cells, strongly supporting our initial diagnosis. A contrast-enhanced abdominal MRI performed six months postpartum indicated no uterine, cervical, or renal abnormalities. Furthermore, the GDC was not associated with any urinary tract abnormalities, such as an ectopic ureter. After thorough discussion with the patient and obtaining her consent, a long-term follow-up plan was selected.

IV. Conclusions

To summarize, the differential diagnosis for a cystic lesion detected in the lateral wall of the vagina should include GDC. Our study highlights that conservative treatment can be a safe option for pregnant patients, emphasizing that GDC is not a contraindication for normal vaginal delivery, provided there is appropriate long-term follow-up.

Literature

- [1] Hoogendam Jp, Smink M. Gartner'S Duct Cyst. *N Engl J Med.* 2017 Apr 6;376(14):E27, Doi: 10.1056/Nejmimc1609983; Pmid: 28379795
- [2] Kier R. Nonovarian Gynecologic Cysts: Mr Imaging Findings. *Ajr Am J Roentgenol.* 1992 Jun;158(6):1265-9, Doi: 10.2214/Ajr.158.6.1590120; Pmid: 1590120
- [3] Theodoridis Td, Pappas Pd, Grimbizis Gf. Surgical Management Of Congenital Uterine Anomalies (In- Cluding Indications And Surgical Techniques). *Best Pract Res Clin Obstet Gynaecol.* 2019 Aug;59:66- 76, Doi: 10.1016/J.Bpobgyn.2019.02.006; Pmid: 30910446
- [4] Gadbois Wf, Duckett Jw Jr. Gartner'S Duct Cyst And Ipsilateral Renal Agenesis. *Urology.* 1974 Dec;4(6):720-1, Doi: 10.1016/0090-4295(74)90255- 6; Pmid: 4454113
- [5] Cope Ag, Laughlin-Tommaso Sk, Famuyide Ao, Gebhart Jb, Hopkins Mr, Breitkopf Dm. Clini- Cal Manifestations And Outcomes In Surgically Managed Gartner Duct Cysts. *J Minim Inva- Sive Gynecol.* 2017 Mar-Apr;24(3):473-477, Doi: 10.1016/J.Jmig.2017.01.003; Pmid: 28089812
- [6] Grimbizis Gf, Spiezio Sardo A, Saravelos Sh, Gordts S, Exacoustos C, Van Schoubroeck D. Et Al. The Thessaloniki Eshre/Esge Consensus On Diagnosis Of Female Genital Anomalies. *Gynecol Surg.* 2016;13:1-16, Doi: 10.1007/S10397-015- 0909-1; Pmid: 26918000; Pmcid: Pmc4753246
- [7] Ación, P, Ación M, Sánchez-Ferrer M. Complex Malformations Of The Female Genital Tract. New Types And Revision Of Classification. *Human Re- Production.* 2004;19(10):2377-2384, Doi: 10.1093/ Humrep/Deh423; Pmid: 15333604
- [8] Rios Ss, Pereira Lcr, Santos Cb, Chen Acr, Chen Jr, Vogt Mdfb. Conservative Treatment And Follow-Up Of Vaginal Gartner'S Duct Cysts: A Case Series. *J Med Case Rep.* 2016 Jun 2;10:147, Doi: 10.1186/S13256-016-0936-1; Pmid: 27256294; Pmcid: Pmc4890494