

# A Case Series of Hydatid Cyst in Different Locations in The Thorax and Surgical Management- Ten Case Reports

Dr. Priyanka Sarkar<sup>1</sup>, Dr. Mrinmoy Talukdar<sup>2</sup>

<sup>1</sup>(Senior Resident, Department of Cardiothoracic and Vascular Surgery, Gauhati Medical College, SSUHS University, Guwahati, Assam, India)

<sup>2</sup>(Assistant Professor, Department of Cardiothoracic and Vascular Surgery, Gauhati Medical College, SSUHS University, Guwahati, Assam, India)

---

## Abstract:

**Background:** Hydatid disease, primarily caused by *Echinococcus granulosus*, commonly affects the liver and lungs but can present in unusual sites such as mediastinum, heart which presents diagnostic and therapeutic challenges.

**Case Presentations:** Presentation of Ten cases of hydatid cyst who underwent surgery in our unit from December 2023 to March 2025 are done. Investigations such as chest xray, cect thorax, routine blood, HPE done.

**Discussion:** The patients were admitted after 6-7 months of development of symptoms. 9 cases were referred for surgical management after 3 months of albendazole treatment. 1 case was diagnosed intraoperatively. 10 cases had cough, 3 cases dyspnea, 3 cases haemoptysis. 1 case presented in rupture. 5 cases were males, 5 cases were females. Age group between 8 to 40 years (mean age 28 yrs). Right side lung was involved in 5 cases, left lung in 2 cases, one case bilateral lungs, one case in superior mediastinum, one case was involving pericardium and right atrial and left ventricular wall. Lower lobe involved in 5 cases, upper lobe in 2 cases, middle lobe in 1 case. Posterolateral thoracotomy, Cystectomy, capitonnage done in 9 cases, Sternotomy in 1 case. Decortication done in 2 cases, Lobectomy in 1 case, Segmentectomy in 1 case. Post-operatively, most patients with chest tubes removed on day 4 (range 3-10 days). Most were discharged by day 6 (range 4-10 days). 10 cases HPE done and albendazole given postoperatively.

**Conclusion:** Surgical management of hydatidosis involves a combination of careful planning, precise surgical techniques, and postoperative care, thus preventing recurrence. The primary objective is to remove the cyst effectively while minimizing the risk of complications. Antiparasitic therapy plays a vital role in preoperative and postoperative management.

**Key Word:** Hydatid disease, *Echinococcus granulosus*, Thoracotomy, Cystectomy

---

Date of Submission: 06-06-2025

Date of Acceptance: 16-06-2025

---

## I. Introduction

Hydatid disease, also known as echinococcosis, is a parasitic infection caused by tapeworms of the genus *Echinococcus*. The life cycle of *Echinococcus* involves canines as definitive hosts and herbivores or omnivores (including humans) as intermediate hosts. The most common species responsible for human infection are *Echinococcus granulosus* and *Echinococcus multilocularis*. ***Echinococcus granulosus***, which causes cystic echinococcosis, is typically transmitted to humans through the ingestion of eggs from contaminated food or water. [5] In humans, the larvae develop into hydatid cysts, most commonly in the liver (60-70%) and lungs (20-30%). These cysts can grow slowly over years and cause a variety of symptoms depending on their location, size, and associated complications. While liver and pulmonary involvement is most common, hydatid cysts can occasionally form in unusual sites, including the brain, bones, spleen, thymic tissue, mediastinum<sup>[1]</sup>, heart<sup>[10]</sup>.

## Case Presentation

### ❖ Case Presentation 1:

A 31-year-old male presented with dry cough on and off since 1 year, difficulty in breathing since 6 months which increased during the last 3 months and aggravated during sleep, difficulty in swallowing solids since 3 months, hoarseness of voice since 3 months. Patient also had 1-2 episodes of haemoptysis during the hospital stay. He had no history of weight loss, loss of appetite. No past history of medical comorbidities and operation.

Personal and family history were unremarkable. General examination was normal . Systemic examination was normal. Local examination, there was no palpable mass in the superior mediastinum. No regional lymph node enlargement.

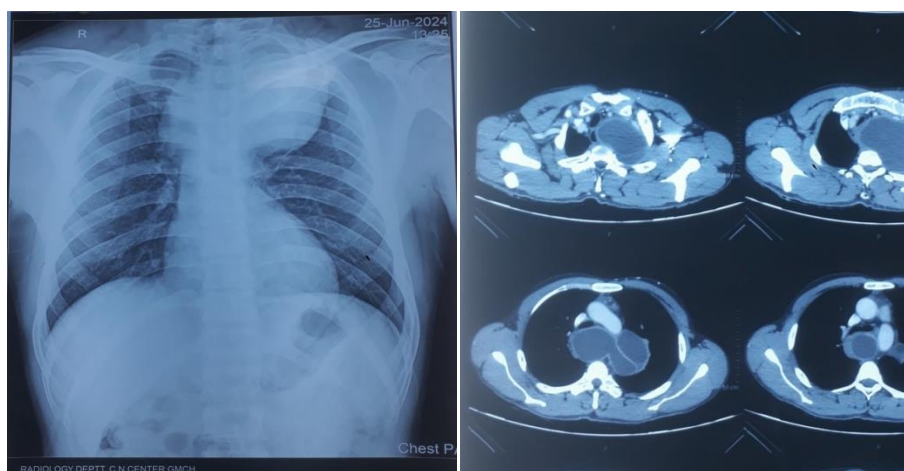


Fig 1: Chest Xray and Cect Thorax showing mass in superior mediastinum

- **Chest X-ray:** The imaging revealed a well-defined, rounded mass in the superior mediastinum
- **Computed Tomography (CT) Scan:** CT scan of the thorax showed a large cystic mass in the superior mediastinum. The mass exhibited a characteristic double-contour sign and peripheral enhancement. The cystic lesion was measuring 97 \*89\*100mm in dimension, causing mass effect over the trachea and esophagus displacing it towards right causing mild luminal narrowing of the same. Anteriorly it was closely abutting the left brachiocephalic artery with maintained fat plane. Inferiorly it was abutting arch of aorta with maintained fat plane. Superiorly it was extending upto the left lower paratracheal space, posteriorly it was causing mass effect over the pre-paravertebral muscles with compressed fat plane. The lesion was also causing mass effect over the left upper lobe. Prominent to enlarged ( few calcified ) lymph nodes were noted in precarinal, subcarinal, aortopulmonary window and prevascular stations measuring upto 12mm. No lung and liver cyst noted .D/D esophageal duplication cyst, thymic cyst, lymphangioma
- **Posterolateral Thoracotomy:** The thorax was entered through 4 th intercostal space, lung retracted . Careful dissection was done to identify and intraoperatively diagnose it as hydatid cyst, isolate the cyst from surrounding tissues. The goal was to avoid rupturing the cyst to prevent the spread of *Echinococcus* larvae. Aspiration of cyst was done, which was filled with clear fluid. The cavity was opened, scolices of cyst were present. Excision of cyst done. Betadine wash given. Pressure ulcer over the esophagus was repaired with prolene 2-0. Haemostasis achieved, drain of 32G placed, thorax closed in layers. Specimen sent for HPE.

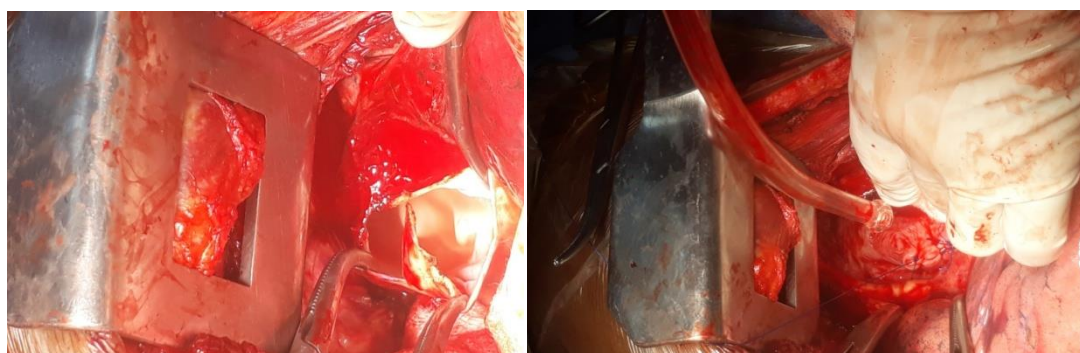


Fig 2 : Intraoperatively Cyst opened and second figure showing repair of esophagus .

- **HPE:** Suggestive of hydatid cyst. **Postoperatively** albendazole was given and planned to be continued for 4-6 weeks to eliminate any remaining larvae and prevent recurrence. Discharged by 10 th day.

#### ❖ **Case Presentation 2:**

A 16-year-old male presented with cough with sputum on and off since 3 years, had an episode of syncope 6 months back .No history of breathlessness. No past history of medical comorbidities and operation . Personal and family history were unremarkable. General examination was normal . Systemic and local examination was normal.



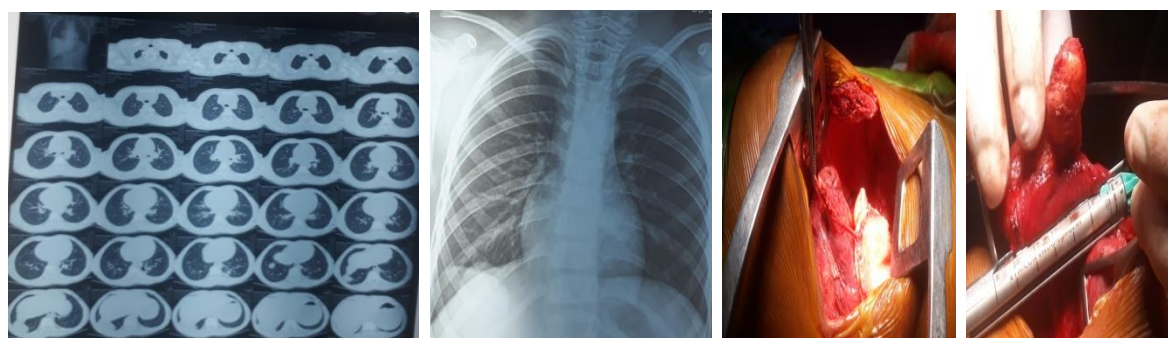
Fig 3: Chest Xray and CEMRI and intraoperative picture of cardiac hydatid cyst

- **Chest X-ray:** The imaging revealed a well-defined, rounded mass in the anterior mediastinum
- **MRI Scan:** Multiple well-defined multiloculated peripherally enhancing cystic lesion in myocardium of right atrium, pericardium of left atrium, myocardium and pericardium of left ventricle and in right perihilar region .
- **Sternotomy :** Median sternotomy done, thymus dissected , pericardium opened, adhesiolysis done . Hydatid cysts were found attached to myocardium of right atrium and pericardium around left atrium and left ventricle. Careful dissection was done to identify and isolate the cyst from surrounding tissues and excised. 3% saline wash given. Bilateral pleura left open. Haemostasis achieved, drain placed in bilateral pleural cavity. Sternum closed with steel wires. Sternal wound closed in layers. Specimen sent for HPE.
- **HPE:** Suggestive of hydatid cyst. **Postoperatively** albendazole was given and planned to be continued for 4-6 weeks to eliminate any remaining larvae and prevent recurrence

#### ❖ **Case Presentation 3:**

A 8-year-old boy presented with dry cough on and off since 2 years. He had no history of weight loss, loss of appetite. No past history of medical comorbidities and operation . Personal and family history were unremarkable. General examination was normal. Systemic and Local examination was normal. No regional lymph node enlargement.

- He was diagnosed with bilateral hydatid cysts(right and left lower lobe) on diagnostic evaluation for which he was operated by posterolateral thoracotomy ,cystectomy, capitonnage initially for the left lung. The right lung was operated two months later by posterolateral thoracotomy and segmentectomy. He had adequate lung expansion and no further complications. He was given antiparasitic therapy postoperatively after initial operation and also for 3 months after the second operation.



#### ❖ **Case Presentation 4:**

A 37 year old male presented with history of cough on and off since 6 months, had sudden onset of breathlessness since 7 days, which aggravated since 2 days. No significant past history. Patient was diagnosed after chest x ray and cect thorax suggestive of left lung ruptured hydatid cyst. Patient was taken for emergency thoracotomy and necessary decortication done. 3 % saline wash given. Intercoastal drain placed . Intercoastal flap myoplasty was done. HPE revealed hydatid cyst. Postoperatively albendazole given for 3 months.

❖ **Case Presentation 5:**

A 13 year old girl presented with cough on and off since 1 year. She was diagnosed to have right lower lobe hydatid cyst in cect thorax. She was operated- right posterolateral thoracotomy, cystectomy, capitonage done. Postoperatively lung expansion was not adequate and there was evidence of air leak in the intercoastal drain . Serial chest x rays were done and patient was taken for reoperation after 10 days. Intraoperatively bronchial leak was present which was repaired with prolene suture and decortication done for thickened parietal pleura .Intercoastal drain was removed after 8 th day of reoperation with adequate lung expansion. She was on antiparasitic therapy for 3 months postoperatively and had no recurrence.

❖ **Case Presentation 6:**

A 40 year old male presented with cough on and off since 9 months, haemoptysis on and off since 4 months. He was initially suspected of Pulmonary tuberculosis. He was ultimately diagnosed of right lower lobe hydatid cyst which was occupying almost the entire lower lobe. He underwent right posterolateral thoracotomy and right lower lobectomy. Post operatively he had adequate lung expansion.HPE was suggestive of hydatid cyst. He was on antiparasitic therapy post operatively.

❖ **Case Presentation 7:**

A 23 year old female presented with cough on and off since 2 years. She was diagnosed of right middle lobe hydatid cyst in cect thorax for which she underwent right posterolateral thoractomy , cystectomy, capitonage, had no complications postoperatively, was discharged by 10<sup>th</sup> day and was on albendazole for 3 months.

❖ **Case Presentation 8:**

A 29 year old female presented with complaints of haemoptysis on and off since 6 months, was diagnosed of left upper lobe hydatid cyst,she underwent left posterolateral thoracotomy , cystectomy. HPE was suggestive of hydatid cyst. She was on antiparasitic therapy for 3 months , had no recurrence on follow up.

❖ **Case Presentation 9:**

A 36 year female presented with cough since 8months, dyspnea on and off since 3 months, haemoptysis on and off since 1 month. No past history of any comorbidities.Necessary investigations were done. Diagnosed of hydatid cyst involving right upper lobe and interfissural area with the middle lobe on cect thorax. She was operated , underwent right posterolateral thoracotomy, adhesiolysis was done between the upper and middle lobe, cyst carefully dissected, cystectomy done. 3% saline wash given, intercoastal drain placed, thorax closed in layers. Postoperatively drain removed by 4 th day and patient discharged by 10 th day. She was on albendazole postoperatively.No recurrence on follow up.

❖ **Case Presentation 10:**

A 34 year old female presented with complaints of cough on and off since 7 months. Cect thorax revealed right lower lobe hydatid cyst. She underwent right posterolateral thoracotomy and cystectomy. She had completed her course of albendazole therapy and had no recurrence on follow up

## **II. Discussion**

Hydatid cyst disease induced by *Echinococcus granulosus* is a parasitic disease known since ancient times. Today, it continues to be seen in many countries and creates serious problems. The lung is the second most frequently affected organ by hydatid cysts after the liver. As per **Aydin Yet al** .<sup>[11]</sup> hydatid cysts are mostly seen in the right lower lobe of the lung which is also seen in our study, common symptoms are cough, shortness of breath also seen in our study, surgery is accepted as primary treatment of lung hydatid cysts in both the studies. The surgical approach is related to several factors such as the size of the cyst, whether it is intact or complicated, unilateral or bilateral, solitary or multiple, and the presence of destruction of the lung parenchyma. As per **Esfandiar SHOJAEI et al** .<sup>[10]</sup> hydatid cyst can involve cardiac structures as seen in our study, the presenting symptom of cardiac hydatid cyst in their study was dyspnea but in our study was cough. Surgical management was done in both the studies. As per **Usharani et al** .<sup>[5]</sup> HPE confirmed diagnosis and postoperatively patient was given antiparasitic therapy similar to our study.

## **III. Conclusion**

Surgical management of hydatidosis involves a combination of careful planning, precise surgical techniques, and postoperative care, thus preventing recurrence. The primary objective is to remove the cyst effectively while minimizing the risk of complications. Antiparasitic therapy plays a vital role in preoperative and postoperative management.

**Clinical significance** crucial for clinicians, especially in endemic areas or in patients with a history of exposure to *Echinococcus*. Early diagnosis and appropriate treatment especially uncommon location presentations can significantly impact patient outcomes, reducing the risk of complications and improving overall prognosis.

### References

- [1]. Yassine Msougar, Oussama Afandi . Mediastinal hydatid cyst: a case report. J Med Case Rep. 2013;7:236
- [2]. Msaad S, Fouzi S, Ketata W. An anterior mediastinal mass of rare etiology. Rev Mal Respir. 2009; 7:324-328.
- [3]. Purohit M. Primary hydatid cysts of the mediastinum .European Journal CardioThoracic Surgery. 2003;7:257-258.
- [4]. Zidi A, Zannad – Hantous S. Hydatid cyst of the mediastinum: 14 case reports. J Radiol. 2006;7:1869-1874.
- [5]. A. Usharani et al. Case reports of hydatid disease. Journal of Epidemiology and Global Health 2013;3:63-66 .
- [6]. Burgos et al. Experience in the surgical treatment of 331 patients with pulmonary hydatidosis. J Thoracic Cardiovascular Surg 1991;102:427-30
- [7]. Aribas et al. Pleural complications of hydatid disease. The Journal of Thoracic and Cardiovascular Surgery 2002 Mar;123(3):497
- [8]. Halezeroglu et al. Giant hydatid cysts of the lung. The Journal of Thoracic and Cardiovascular Surgery 1997;113(4):712-7
- [9]. Topcu et al. Surgical Treatment of Pulmonary Hydatid cysts in children. The Journal of Thoracic and Cardiovascular Surgery 2000 :120:1097-101
- [10]. Esfandiar SHOJAEI et al . Cardiac Hydatid cyst: A Case Report. Iran J Public Health. 2016 Nov;45(11):1507-1510.
- [11]. Aydin Y, Ulas AB, Ahmed AG, Eroglu A. Pulmonary Hydatid Cyst in Children and Adults: Diagnosis and Management. Eurasian J Med. 2022 Dec; 54(Suppl1):133-140