

Hepatomedly – A Spectrum Of Liver Lesions In A Tertiary Care Centre – A Retrospective Study

Dr. A. Surendhar

Government Stanley Medical College, Chennai

Abstract:

Aim: To study the age group, gender and histomorphological spectrum of HEPATIC LESIONS in a tertiary care centre.

Materials And Methods: A total of 110 biopsies, Excision specimens were received in the Department of Pathology in Govt. Stanley Medical college over a period of two years were studied using routine histopathological stains and Immunohistochemistry was done as and when required. Age, gender, site and histological entities were noted and analysed.

Results: In our study, 110 cases were studied. 53 were biopsies and 57 were Liver resected specimens. Out of 53 biopsies, 17 were Non neoplastic lesions, 36 were Malignant lesions. There was a male preponderance with in incidence of liver lesions in our study. Out of 53 biopsies, 42 were male and 11 were female. Out of 57 Liver Resected specimen, 39 were male and 18 were female.

Conclusion: This study reveals the distribution of various hepatic lesions in our institute.

Keywords: Hepatic lesions, Histomorphology, neoplastic, non neoplastic

Date of Submission: 13-04-2026

Date of Acceptance: 23-04-2026

I. Introduction:

Liver is a primary organ for various metabolic activities of the body.

It is exposed to various metabolic, toxic, infectious and neoplastic insults. Thus, a spectrum of various primary as well as secondary diseases can affect liver. The common primary liver diseases are hepatitis, non-alcoholic fatty liver disease (NAFLD), alcoholic liver disease (ALD) and hepatocellular carcinoma (HCC).

Secondary hepatic involvement can be due to alcoholism, extrahepatic infections or metastatic spread of various primary malignancies.

Liver diseases are a major cause of morbidity and mortality globally, although the burden and underlying causes differ across locations and demographic groups

Liver biopsy contributes greatly to the understanding of liver diseases & is considered gold standard for evaluating liver disorders, providing information regarding diagnosis, disease progression and response to therapy.

II. Materials And Methods:

This is a cross sectional and prospective analysis of Hepatic lesions received in our Department of Pathology over a period of two years. All biopsies and excision specimens were included in the study. The biopsies were formalin fixed and paraffin embedded and the sections taken. Routine Haematoxylin and Eosin staining was done and Immunohistochemistry was done as and when required for the diagnosis.

III. Results:

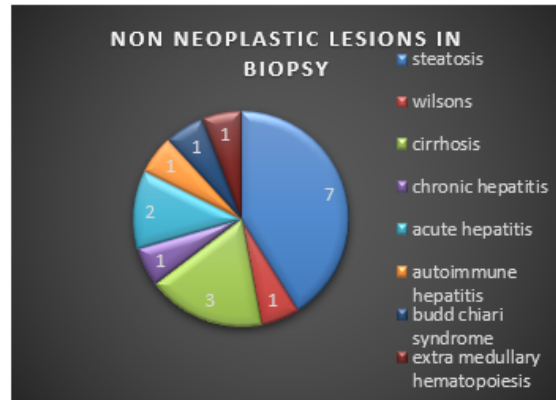
In our study, 110 cases were studied. 53 were biopsies and 57 were Liver resected specimens. Out of 53 biopsies, 17 were Non neoplastic lesions, 36 were Malignant lesions. Out of 57 resected specimen, 18 were Non neoplastic lesions, 29 were Malignant lesions and 10 were Benign neoplasms

There was a male preponderance with in incidence of liver lesions in our study. Out of 53 biopsies, 42 were male and 11 were female. Out of 57 Liver Resected specimen, 39 were male and 18 were female.

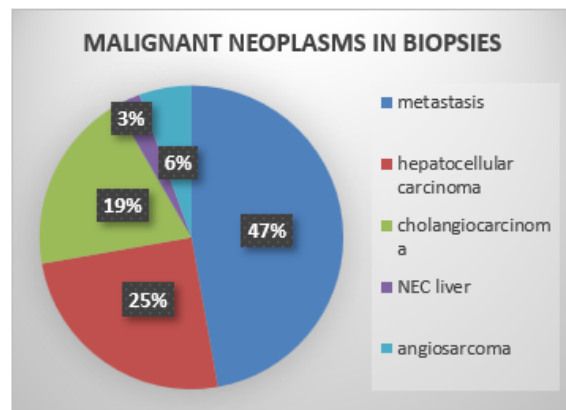
In Biopsies, 17 were non neoplastic lesions and 36 were malignant lesions. (table 1). In Resection specimens, 18 were non neoplastic lesions, 29 were malignant and 10 were benign lesions. (table 2).

In biopsies, among non neoplastic lesions, steatosis was the commonest presentation (7), followed by cirrhosis of liver (3). Among malignant lesions, Metastatic deposits (17) was the commonest presentation, followed by Hepatocellular carcinoma (9).

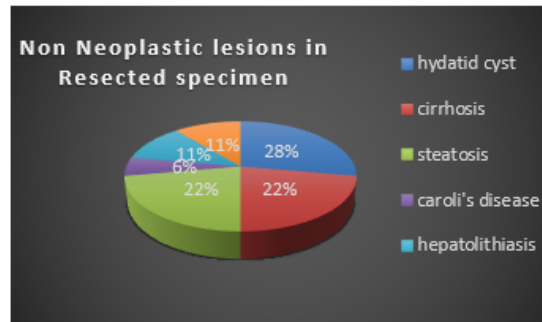
BIOPSY – NON NEOPLASTIC	
STEATOSIS	7
WILSONS	1
CIRRHOSIS	3
CHRONIC HEPATITIS	1
ACUTE HEPATITIS	2
AUTOIMMUNE HEPATITIS	1
BUDD CHIARI SYNDROME	1
EXTRA MEDULLARY HEMATOPOIESIS	1



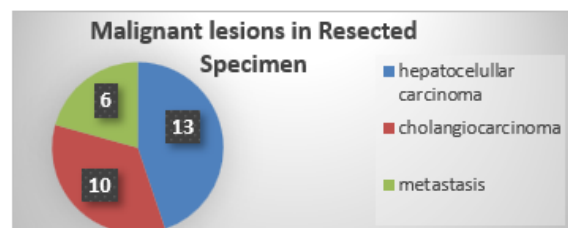
MALIGNANT LESIONS IN BIOPSY	
METASTASIS	17
HEPATOCELLULAR CARCINOMA	9
CHOLANGIOCARCINOMA	7
NEC LIVER	1
ANGIOSARCOMA	2



RESECTION - NON NEOPLASTIC LESIONS	
HYDATID CYST	5
CIRRHOSIS	4
STEATOSIS	4
CAROLI'S DISEASE	1
HEPATOLITHIASIS	2
CHRONIC HEPATITIS	2



RESECTION – MALIGNANT NEOPLASMS	
HEPATOCELLULAR CARCINOMA	13
CHOLANGIOCARCINOMA	10
METASTASIS	6



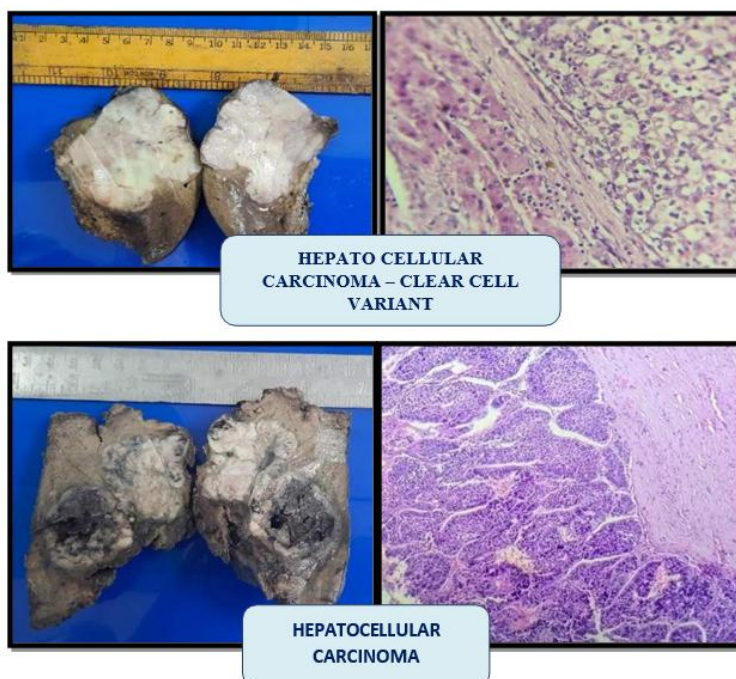
Biopsy	Non- Neoplastic	Malignant	Benign	Total
Male	11	31	0	42
Female	6	5	0	11
Total	17	36	0	53

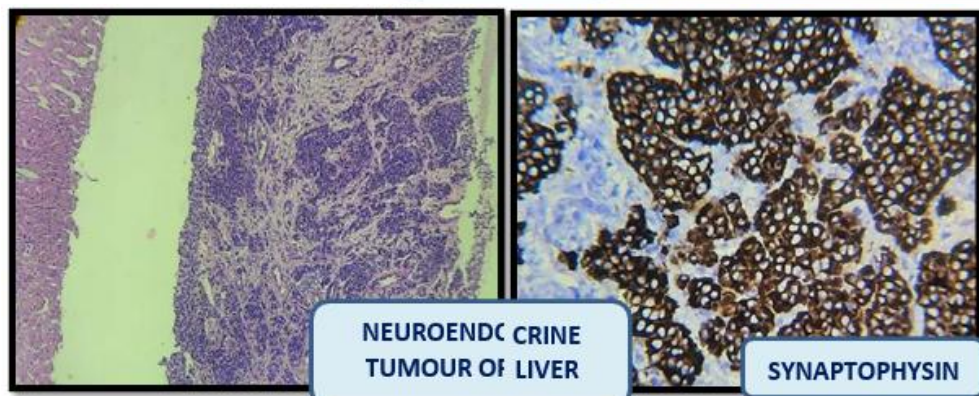
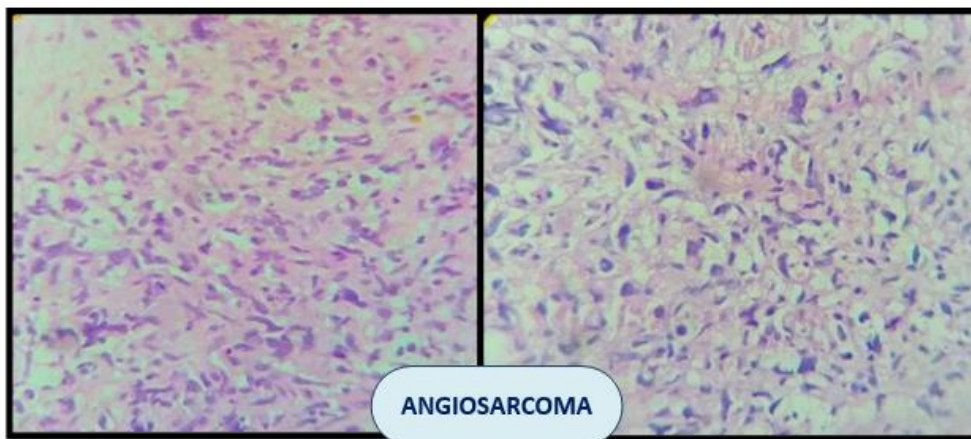
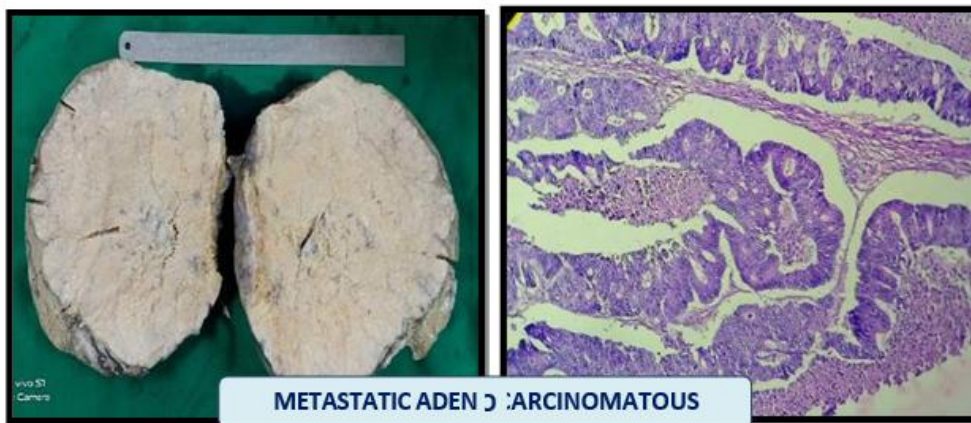
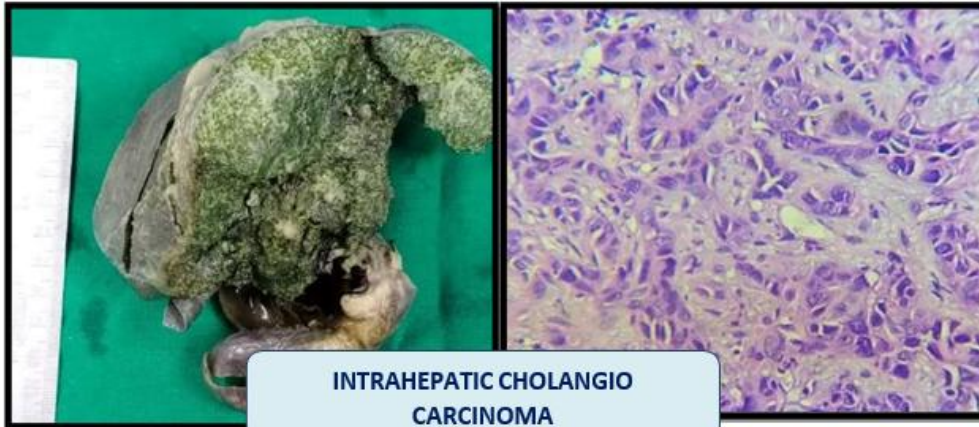
Resection	Non- Neoplastic	Malignant	Benign	Total
Male	12	24	3	39
Female	6	5	7	18
Total	18	29	10	57

Metastasis	GIT	Pancreas	Others	Total
Biopsy	9	4	4	17
Resection	5	1	0	6
Total	14	5	4	23

In Resected specimens, Among Non Neoplastic lesions, Hydatid cyst was the common presentation (5), followed by Cirrhosis (4) and steatosis (4). Among Malignant lesions, Hepatocellular Carcinoma (13) was the common presentation followed by Intrahepatic Cholangiocarcinoma (10).

Among Metastatic lesions, GIT was the common primary malignancy to metastasize to Liver in both Biopsies and Resected specimens followed by pancreas. (table 3) Single Rare cases such as Angiosarcoma and Neuroendocrine Tumour of liver had been reported.





IV. Discussion:

Microscopic examination of the liver lesions is an important diagnostic tool for accurate diagnosis and management of liver diseases. In the present study on liver lesions 110 cases were analysed. Majority of the hepatic lesions were found in the males (n=42 in biopsy and 39 in resected specimens). Our results were also consistent with the studies.^{1,2}

In our study of, the most common age group affected was middle aged males between 40 to 60 years, with steatosis being the common non neoplastic lesion followed by cirrhosis that may be due to higher incidence of alcohol usage by males. This correlates with the studies conducted by Murgod et al.²

One of the most common infectious hepatic lesion reported in our study was hydatid cyst. The liver is the most common site for hydatid disease (75% of cases), followed by lungs (15%). According to the Indian literature the majority of cases have been recorded from southern and western India viz. Andhra Pradesh, and Tamil Nadu with a prevalence of around 10-15%.³

Apart from these cases like Wilson's disease (1 case), Caroli's disease (1 case) autoimmune hepatitis (1 case), acute hepatitis (2 cases) also been reported.

In our study, the most commonly encountered hepatic lesions were hepatic tumours and these results were in concordance with the other Indian study.^{1,4}

In the hepatic tumours most common malignant lesion detected by biopsy was metastatic deposit followed by Hepatocellular carcinoma. This is in concordance with the study conducted by Neekita et al.⁵. This is in contrast to the study conducted by Murgod et al, Chawla et al showed a predominance of HCC.

Whereas in our institutional study among the resected specimens most common malignant lesions, was Hepatocellular Carcinoma followed by Intrahepatic Cholangiocarcinoma.

Hepatocellular carcinoma is the most common primary liver malignancy with variable risk factors and geographical distribution. Microscopically, various histological patterns have been observed such as trabecular, solid, tubular, acinar pattern which has no therapeutic implications.

On the other hand there is an increasing trend in biliary tract cancers particularly intrahepatic cholangiocarcinoma (IHCCA) that might be due to increased exposure to environmental toxins, and persistent inflammatory stimuli. Even in our study we have reported 34% cholangiocarcinoma in resected specimens in par with HCC (45%). The incidence of intrahepatic cholangiocarcinoma is highest in Asia, where *Clonorchis sinensis* is endemic.

Despite advances in diagnosis and therapies, patient prognosis has not improved substantially in the past decade, with 5-year survival (7–20%) and tumour recurrence rates after resection high. Therefore, a detailed study of these types of cancers is needed.⁶

We have reported a case of primary neuroendocrine tumour of liver in a 23-year-old male. These are very rare hepatic tumours with < 200 cases reported in the literature. It accounts for 0.3% of all NET cases. As imaging studies fail to detect primary lesions elsewhere in the body we conclude this as primary neuroendocrine tumour of liver.⁷ These tumours are slow growing in nature with low malignancy potential.

We reported 2 cases of angiosarcoma of liver in a 30-year-old female. Hepatic angiosarcoma, although rare, is the third most common primary liver malignancy. Occupational exposures to vinyl chloride monomer and arsenic are well known to induce angiosarcoma. Even though there are certain imaging characteristics to diagnose these lesions, it is difficult to distinguish it from other hepatic tumours, hence requires a pathological diagnosis.⁸

The liver is one of the most common sites of metastasis. Secondary liver cancers are most commonly carcinomas, followed by melanoma, sarcoma, and lymphoma. The major primary cancers that metastasize to the liver are colorectal carcinoma, breast carcinoma, neuroendocrine tumours, lung carcinoma, and gastric carcinoma. In our study also most common primary site was GIT. We found a significant number of pancreatic cancer metastasis to the liver in our analysis. In general, immunohistochemical studies and histomorphologic examinations are very useful for the pathologic differential diagnosis of metastatic tumours.⁹

V. Conclusion:

Microscopic examination of liver biopsy yields a diverse range of pathological findings and helps to uncover diseases for which specific management is indicated. From our study we found that hepatic lesions of neoplastic etiology are at an increasing trend compared to the other lesions which insist on the need for risk factor assessment in high risk individuals. Information regarding epidemiology of particular disease in a geographical area also helps to take preventive measures.

References:

- [1]. Chawla N And Sunila S. Spectrum Of Histopathological Findings In Liver Biopsy. Indian Med Gaz. 2013; 363-67.
- [2]. Spectrum Of Hepatic Lesions-A Histopathological Study Of Liver Biopsies. Murgod, Doshi And Dombale. IP Journal Of Diagnostic Pathology And Oncology 4 (2019) 200–203
- [3]. Akther J, Khanam N, Rao S: Clinico Epidemiological Profile Of Hydatid Diseases In Central India, A Retrospective And

- Prospective Study. *Int J Biol Med Res.* 2011, 2:603-6.
- [4]. Agrawal NS, Iqbal M.B, Patil AA, Karia KM, Kumar H. Study To Evaluate The Spectrum Of Hepatic Lesions In Liver Biopsies In A Tertiary Care Hospital. *Annals Of Pathology And Laboratory Medicine.* 2018; 5(3): 228-33
- [5]. Study To Evaluate The Histopathological Spectrum Of Hepatic Lesions In Liver Biopsies In A Tertiary Care Hospital. Neekita Shriram Agrawal, M. Banyameen Iqbal Et Al. *Annals Of Pathology And Laboratory Medicine*, Vol. 5, Issue 3, March, 2018
- [6]. Cholangiocarcinoma - Evolving Concepts And Therapeutic Strategies. Rizvi, S., Khan, S. A., Hallemeier, C. L., Kelley, R. K. & Gores, G. J. *Nat. Rev. Clin. Oncol.* 15, 95–111 (2018).
- [7]. Primary Hepatic Neuroendocrine Tumor: A Case Report And Literature Review. Adriano C. Costa, Fernando Santa-Cruz ET AL. *Int J Surg Case Rep.* 2020; 72: 1–4
- [8]. Hepatic Angiosarcoma: A Case Presentation. Noor M, Leyva A, Patacsil S J, Et Al. (February 02, 2020) *Cureus* 12(2): E6848. Doi:10.7759/Cureus.6848
- [9]. Jeong Hwan Park And Jung Ho Kim. *Clin Mol Hepatol.* 2019 Mar; 25(1): 12–20. Pathologic differential diagnosis of metastatic carcinoma in the liver