

A case of adenomatoid odontogenic tumor with psammoma like calcifications

Dr. Sanjeev Tyagi* Dr. Parimala Tyagi ** Dr.Vartul Dwivedi ***

Dr. Saurabh Dhanraj Yadav ****

*Professor & HOD, Department of Conservative Dentistry & Endodontics

**Professor & HOD, Department of Pediatric Dentistry

*** Senior Lecturer, Department of Conservative Dentistry & Endodontics

****P.G. student, Department of Pediatric Dentistry

People's Dental Academy, Bhopal (MP)

Abstract: Adenomatoid odontogenic tumor(AOT)shows presence many calcifications like tumor droplets, enameloid, dentinoid and tubular dentin. But this is first case reporting presence of psammoma bodies, which are extracellular calcifications seen in meningeal, ovarian and thyroid tumors. They are believed to be formed because of many different mechanisms. This is report of a case where 15 year old girl presented with swelling on maxilla. Clinically and radiographically it was presented as globulomaxillary cyst. Histopathologically it was proved to be AOT with numerous calcifications. These calcifications were extracellular containing many concentric lines resembling psammoma bodies.

I. Introduction:

Adenomatoid odontogenic tumor (AOT) is an uncommon tumor of odontogenic origin. It was first reported by Steenland¹ in 1905. The name AOT was proposed by Philipsen and Birn². It is characterized histologically by formation of duct like structures with amyloid-like deposits. AOT referred to as 2/3rd tumor because 2/3 rd occur in the maxilla, 2/3 rd occur in young females, 2/3 rd associated with an unerupted tooth, 2/3 rd of those teeth are canines³.

AOT presents itself clinically in many varied forms. Usually it mimics other tumors or cysts. We present a case of AOT diagnosed as a globulomaxillary cyst clinically and radiographically that histopathologically contained many psammoma like calcifications.

II. Case Report:

A 15 years old female patient, presented with a slowly increasing intraoral swelling in the right upper jaw since 6 months. There was no history of trauma, pain, discharge or any other swelling in the body. Facial symmetry was maintained. On examination, a single 1cmX1cm swelling was seen on labial aspect of maxillary alveolus in relation to teeth 12 to 14 (Fig 1). The nodular swelling had well defined margins with normal overlying mucosa. On palpation, swelling was bony hard and non-tender.

Radiographic examination showed (IOPA and OCCLUSAL) "Inverted pear" shaped radiolucency with undefined borders between 12 and 13 displacement of root of 13(Fig 2 and 3). Based on clinical and radiological examination diagnosis of globulomaxillary cyst was given. Excision of the tumor under conscious sedation was done. Tissue was submitted for the histopathological examination. Histological examination revealed cystic lining containing multinodular proliferation of epithelial cells with presence of duct like and rosette like patterns. This duct like structures lined by tall columnar cells which showed palisading and reverse polarity at the centre with eosinophilic material. Rosette pattern contained spindle shaped cells. The area between rosette and duct like pattern is filled with spindle shaped and polygonal cells(Figure 4). Lamellar calcifications similar to psammoma bodies (PB) were seen in-between the epithelial nodules. These calcifications were seen extracellularly, clustered in one area, in between rosette and duct like patterns (Figure 5). At the periphery of tumor basaloid cells arranged in plexiform pattern were seen. Connective tissue capsule showed collagen fibers, few endothelial lined blood vessels containing RBCs which suggested AOT.

III. Discussion:

AOT is a rare tumor that comprises only 2.2 to 7.1% of all odontogenic tumors⁴. It is an uncommon cause of jaw swelling in teenagers. There are three clinic-pathologic variants of AOT, intraosseous follicular, intraosseous extrafollicular and peripheral variants, all with identical histopathology. The follicular type is a central tumor associated with an impacted tooth, while extrafollicular intraosseous AOT has no relation with an unerupted tooth, which is found in our case.

AOT's are more commonly found in the maxilla than in the mandible (2.1:1 ratio). More than two thirds are diagnosed in the second decade, mostly in the 13-19 year age group, the female: male ratio is 1.9:14 which correlates with our case. Even higher ratios are found in Asian populations, the highest incidence being observed in Srilanka (3.2:1)⁵ and Japan (3:1)⁶.

Various types of extracellular material have been observed in AOT. These include presence of eosinophilic material, hyaline material⁷, dentinoid^{8,9}, frank tubular dentin^{4,10}, osteodentin, and abortive enamel¹¹. But probably this is first reported case which has recorded presence of psammoma like calcifications. They had concentric lines. Central part was denser than the outer area which was less calcified. These calcifications were clustered and present in extracellular matrix.

Psammoma bodies (psammoma-sand, Gk) are small basophilic concentrically laminated structures found in a great variety of neoplastic and non-neoplastic conditions. They are more commonly found in tumors of meningeal¹², thyroid¹³ and ovarian origin^{14, 15}. Few tumors of GI tract also occasionally show presence of psammoma bodies¹⁶. Presence of psammoma bodies is thought to be ominous sign in cervicovaginal smears¹⁵. Occurrence of psammoma bodies is very rare in oral tumors. They have been reported in some of the tumors of salivary gland (acinic cell carcinoma, PLGA, salivary duct carcinoma, cystadenoma)¹⁷ and oral and extra oral juvenile ossifying fibroma¹⁸. Genesis of psammoma bodies is not clear. Several hypotheses pertaining to their origin and development have been proposed including epithelial degeneration associated with cell death, mineralization of secretions of epithelial tumor cells and a reflection of tumor-host reaction¹⁹.

It has been observed that these bodies are more commonly found in tumors with degenerating cells. Such cells contain many autophagic and heterophagic vesicles. These vesicles act as matrix vesicles favoring mineralization. But the reason for occurrence in only few tumors is unknown. In more than 20% cases of thyroid tumors psammoma bodies are found in normal tissue adjacent to tumor where degeneration is not seen¹⁹. Many epithelial tumors such as thyroid tumors secrete extracellular material. This material may undergo calcification to form psammoma bodies¹⁹. Same hypothesis may be extended for psammoma bodies seen in salivary gland tumors. In juvenile ossifying fibroma, which is thought to originate from periodontal ligament, tumor cells can form either osteoid or cementoid. Osteoid in such lesions may appear like psammoma bodies if it shows concentric rings¹⁸.

The role of nanobacteria mediated biomineralization is also suspected to be responsible for formation of psammoma bodies, especially in ovarian tumors. Their role in various odontogenic calcifications and non odontogenic pathological calcification has to be evaluated²⁰.

IV. Conclusion:

This is probably the first case, which has recorded psammoma bodies in AOT. These were small round to ovoid masses and almost same size, present in extracellular matrix. Most of the bodies showed dense, basophilic inner core surrounded by eosinophilic area. These probably represent calcified eosinophilic material or hyaline material, which is commonly found in these tumors. The significance of these calcifications cannot be ascertained at this juncture as this is first case. Presence of these bodies in other odontogenic tumors should be recorded to find out the significance.

References:

- [1] Unal T, Centingul E, Gunbay T, Peripheral Adenomatoid odontogenic tumor: Birth of a term J Clin Pediatr Dent 1995;19:139-142
- [2] Philipsen HP, Birn H. The adenomatoid odontogenic tumor. Ameloblastic adenomatoid tumor or adeno-ameloblastoma. Acta Pathol Microbiol Scand 1969; 75:375-398.
- [3] Marx and Stern. Odontogenic and nonodontogenic cysts. In: Marx and Stern (eds) Oral maxillofacial pathology A rationale for diagnosis and treatment Chicago: Quintessence 2004:609-612.
- [4] Philipsen and Reichart. Adenomatoid odontogenic tumor. In: Philipsen and Reichart Odontogenic tumors and allied lesions. London: Quintessence 2004:105-120
- [5] Mendis BRRN, MacDonald DG. Adenomatoid odontogenic tumor: A survey of 21 cases from Srilanka Int J Oral Maxillofac Surg 1990;19:141-143
- [6] Toida M, Hyodo I, Okuda T, Tatematsu N. Adenomatoid odontogenic tumor: report of two cases and survey of 126 cases in Japan. J oral Maxillofac Surg 1990; 75:375-398.
- [7] Moro I, Okamura N, Okuda S, Komiyama K, Umemura S. The eosinophilic and amyloid-like materials in adenomatoid odontogenic tumor. J Oral Path Med 2006 ; 11(2):138 - 150
- [8] Matsumoto Y, Mizoue K, Seto K Atypical plexiform ameloblastoma with dentinoid: adenoid ameloblastoma with dentinoid J Oral Path Med 2001; 30(4):251-254
- [9] Evans B, Carr R, Phillippe L. Adenoid ameloblastoma with dentinoid: A case report Oral Surg Oral Med Oral Pathol Oral Radiol Endod. 2004;98 (5):583- 588.
- [10] Takeda Y, Shimono M Adenomatoid odontogenic tumor with extensive formation of tubular dentin. Bull Tokyo Dent Coll. 1996 Nov;37(4):189-93. 11. Takeda Y. Induction of osteodentin and abortive enamel in adenomatoid odontogenic tumor. Ann Dent. 1995;54(1-2):61-3.
- [11] Rizzoli HV, Randall JD, Smith D R. Psammoma bodies in meningiom. Appearance by scanning electron microscope. Virchows Archiv Volume 1978; 380,(4): 317-325 D. Randall, and Donald R. Smith
- [12] Klisck and Winship psammoma bodies and thyroid cancer Cancer. 1959 Jul- Aug;12(4):656-62.

- [13] Hameed and Donald A. Papillary adenocarcinoma of endometrium with psammoma bodies. Histology and fine structure. Cancer 2006 ; 29(5):1326 – 1335
- [14] Pusiol T, Parolari AM, Piscioli I, Morelli L, Nonno FD, Licci S. Prevalence and significance of psammoma bodies in cervicovaginal smears in a cervical cancer screening program with emphasis on a case of primary bilateral ovarian psammocarcinoma CytoJournal 2008, 5:7
- [15] Park SY, Ko GH, Kim WH, Kim Y. papillary adenocarcinoma of the stomach with psammoma bodies: report of two cases. J Korean Med Sci 1999;14:213- 216.
- [16] Barnes L, Eveson JW, Reichart P, Sidransky D. Pathology and Genetics of Head and Neck Tumours Lyon: IARC Press 2005.
- [17] El-Mofty S. Psammomatoid and trabecular juvenile ossifying fibroma of the craniofacial skeleton: Two distinct clinicopathologic entities Oral Surg Oral Med Oral Pathol Oral Radiol Endod 2002;93:296-304.
- [18] Ferenczy A, Talens M, Zhogby M, Hussain S. Ultrastructural studies on the morphogenesis of psammoma bodies in ovarian serous neoplasia. Cancer 1977;39:2451-2459.
- [19] Hudelist G, Singer C F, Kubista E, Manavi M, Mueller R, Pischinger K Czerwenka K. Presence of nanobacteria in psammoma bodies of ovarian cancer: evidence for pathogenetic role in intratumoral biomineralization Histopathology

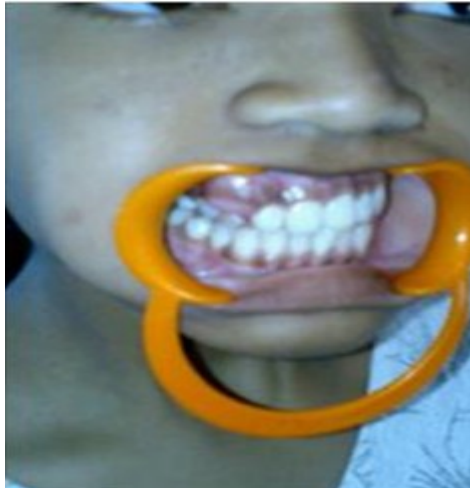

Figure-1 : Swelling on labial aspect of maxillary alveolus relation to 12 to 14

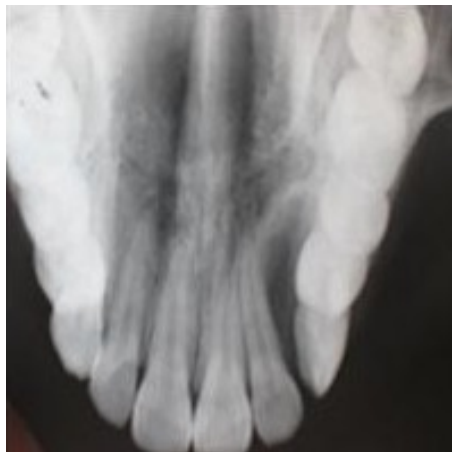

Figure-2 : Inverted pear shaped radiolucency with undefined borders

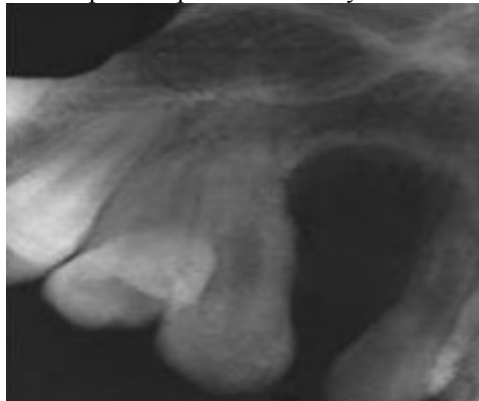


Figure-3 : Inverted pear shaped radiolucency between 12 and 13 with displacement root of 13

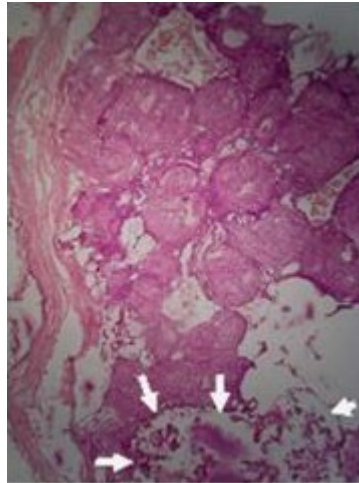


Figure-4 : Rosette and duct like pattern filled with spindle and polygonal cells

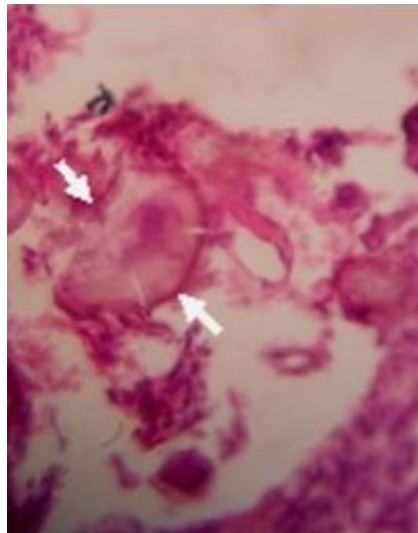


Figure-5 : Laminar calcification similar to psammoma bodies