

Prospective Study on ND: YAG Capsulotomy & Complications

Dr.P.Sambasiva Reddy

Corresponding Author: Dr.P.Sambasiva Reddy

Abstract: The aim of study to determine the complications that can arise with Nd:YAG laser posterior capsulotomy. **MATERIALS & METHODS:** Total of 100 patients, who attended at out-patient department were subjected for this study. March 2018 to August 2018, and followed up over a period of 6 months. **RESULTS;** post yag laser B.C.V.A. 90% of cases were 6/6. **CONCLUSION:** Nd: YAG laser capsulotomy is a safe and effective method of restoring vision in patient with posterior capsular opacification.;

Keywords: E.C.C.E., B.C.V.A, Capsular opacification, Laser capsulotomy, complications, followup and results.

Date of Submission: 06-02-2019

Date of acceptance: 21-02-2019

I. Introduction

Posterior capsular opacification is the commonest long term complication following modern cataract surgery. Posterior capsular opacification (PCO) is known to range from as high as 50% to as low as <5% in eyes undergoing E.C.C.E. surgery for uncomplicated senile cataract. PCO leads to the same symptoms of cataract, like blurring of vision, decrease in contrast sensitivity, and glare. At present the most widely accepted procedure for the management of symptomatic posterior capsular opacification is Nd:YAG laser capsulotomy. This procedure is not always free of complications and several complications have been reported 5-6.

The main purpose of the study is to evaluate the immediate and late complications following laser capsulotomy.

This study is being carried out at Sarojini Devi Eye Hospital, Hyderabad during the period of March 2018 to August 2018. Patients treated were followed up over a period of 6 months

AIMS AND OBJECTIVES

AIM: to determine the complications that can arise with Nd:YAG laser posterior capsulotomy

OBJECTIVES: 1) To study the intra operative and post-operative complications of Nd:YAG laser capsulotomy with a follow up period of 6 months. 2) To study the visual outcome following Nd:YAG laser posterior capsulotomy for posterior capsular opacification

II. Review Of Literature

A study by Prajna NV⁷, et al found that in India, 13.5% of eyes that have undergone ECCE and lens implant surgery reported vision loss after 2-3 years owing to PCO.

In a study by Hasan KS⁸, et al the time interval between cataract surgery and Nd: YAG laser posterior capsulotomy was 2.49 years.

POSTERIOR CAPSULAR OPACIFICATION (PCO).

PCO results from the growth and abnormal proliferation of lens epithelial cells (LECs) on the capsule at the time of cataract surgery. These cells migrate to the posterior capsule, where they approach the central visual axis and cause visual-axis obscuration, resulting in dimness of vision. 1) The PCO has two forms: 1) fibrous form. 2) pearl form. The development of PCO is a very dynamic process and involves three basic phenomena: proliferation⁸, migration⁸ and differentiation⁸ of residual LECs.

MANAGEMENT. 1) Nd:YAG laser capsulotomy

PROCEDURE OF LASER CAPSULOTOMY:

I) Preoperative assessment- it is essential for all the patients who undergo for the capsulotomy procedure 1) Complete ophthalmic and medical history. 2) Best corrected visual acuity by means of retinoscopy, AR and subjective refraction. 3) Intraocular pressure recording. 4) Slit lamp evaluation of anterior segment. 5) Fundus examination by direct and indirect ophthalmoscopy.

II) Preparation of the patient: Capsulotomy is done in an undilated pupil. The procedure should be explained to the patient and informed consent should be taken. No anesthesia is required unless a contact lens is used where topical anesthetic is applied to the cornea. Adjustment of stool, table chin rest and foot rest for patient optimal comfort. Head strap is applied, darkening of room is option.

III. Material And Methods

TYPE OF STUDY: It is a short term prospective study carried out at sarojinidevi eye hospital, Hyderabad.

SAMPLE SIZE: Total of 100 patients, who attended at out- patient department were subject for this study.

DURATION OF STUDY: March 2018 to August 2018, and followed up over a period of 6 months.

INCLUSION CRITERIA: 1) PCO with significant visual loss of less than 6/24 were included in the study. 2) Age group (10-80 yrs); both male and female patients. 3) Should have completed atleast a period of 3 months after cataract surgery.

EXCLUSION CRITERIA: 1) Patients with VA better than 6/24. 2) Patients with h/o of pre-existing intra ocular pathologies such as retinal detachment, diabetic retinopathy, hypertensive retinopathy, glaucoma etc. 3) Patients with PCO in less than 3 months post cataract surgery. 4) Patients with active intra ocular inflammation.

METHODS:

Recording of complete history regarding symptoms, duration of cataract surgery, type of surgery, and previous systemic and ocular diseases. Each case underwent a detailed evaluation to confirm that the visual loss was only due to PCO. A complete evaluation was done prior to capsulotomy. All the laser capsulotomy procedures were done by a single surgeon.

PROCEDURE OF LASER CAPSULOTOMY:

After complete evaluation of the patient, an informed consent is obtained. An Abraham lens of +66 diopters was used in apprehensive patients. No topical anaesthesia was used.

The patient is seated comfortably in front of slit lamp and he is told that he will feel a slight stinging sensation, see a bright flash with each shot and hear a clicking sound. Capsulotomy was done in undilated pupil to facilitate capsulotomy in the center of pupillary area. The size and shape of the opening was largely variable depending on the fibrosis of the PCO which required greater power and more number of shots. Laser settings were recorded. Immediate complications were noted. IOP was recorded at the intervals of 1st, 4th hour and 24th hour. Cases were intended to follow up for 6 months period as follows.

First visit: after one week

Second visit: after 1 month

Third visit: between 3 months-6 months. For each visit: patients were thoroughly evaluated for recording of complications.

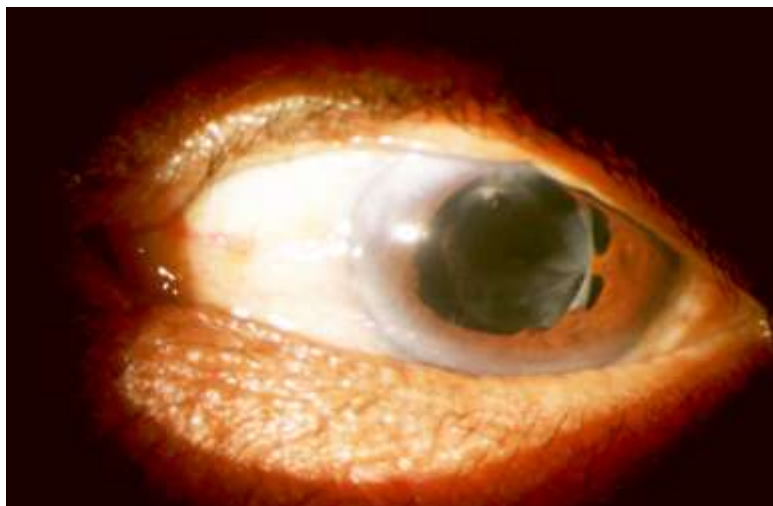
For immediate follow up of 24 hours, the cases were divided into 2 groups.

Group I: consisted of 60 patients who were given the post laser topical medication with timololmaleate (0.5%) eye drops BD and topical steroid (prednisolone acetate 1% eye drops for 4 times a day)

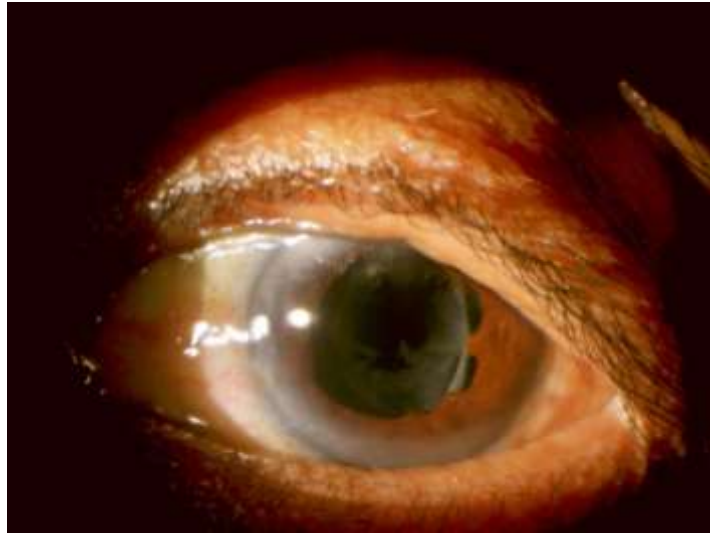
Group II: consisted of 40 cases who were not given topical medication for 24 hours. The main purpose of dividing cases into 2 groups was to observe the rise of IOP with and without treatment.

This division into two groups was not standardized because patients were explained of complications which occur without therapy and cases who were willing for comparative study were included in group-II. The main aim of dividing cases into two groups was to look for rise in intraocular pressure following Nd:YAG laser capsulotomy without topical medication within first 24 hours. Those patients, who developed raised IOP in group-II, were immediately given treatment for control of pressure

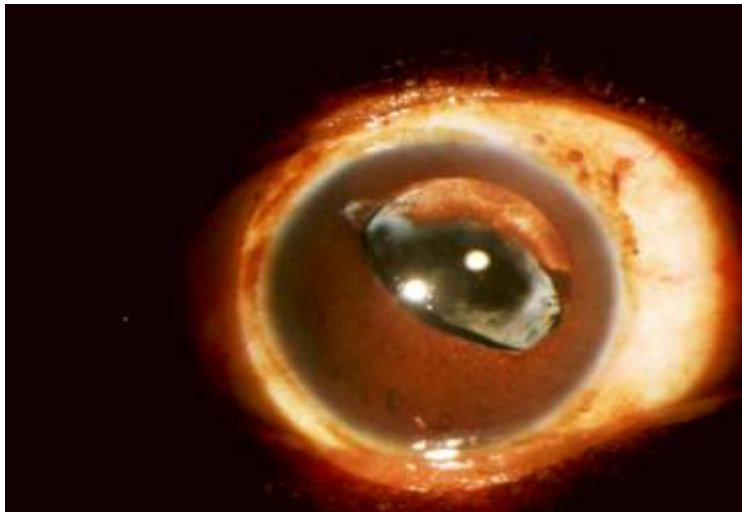
X - PRE LASER



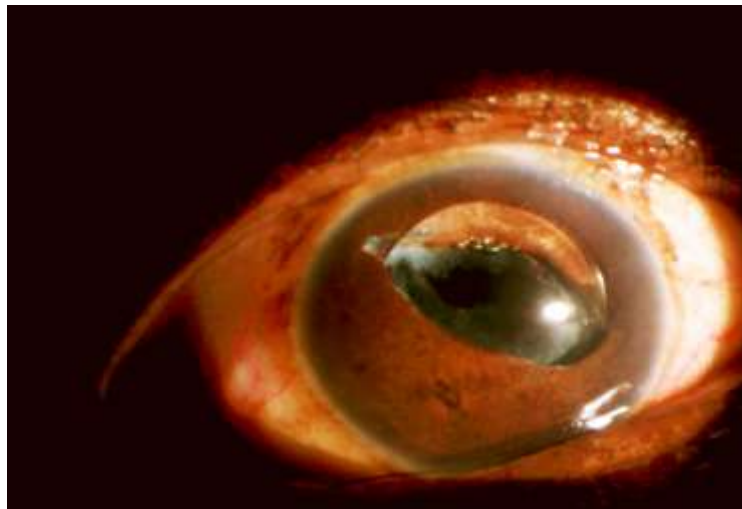
POST LASER



XI - PRE LASER



POST LASER



IV. Observations And Results

After a short term study of 6months the following results were observed. The total number of cases recruited for this study are 100. Cases were divided according to base line characteristics like age, sex, VA, duration from the date of cataract surgery and total amount of energy used for capsulotomy.

TABLE 1 - AGE WISE DISTRIBUTION

AGE	NO.OF CASES	PERCENTAGE
10-20 yrs	04	4%
21-40 yrs	16	16%
41-60 yrs	45	45%
60 and above	35	35%
total	100	100%

In our study 80% of the patients were above the age group of 40 years and above.

GRAPH1-AGE WISE DISTRIBUTION

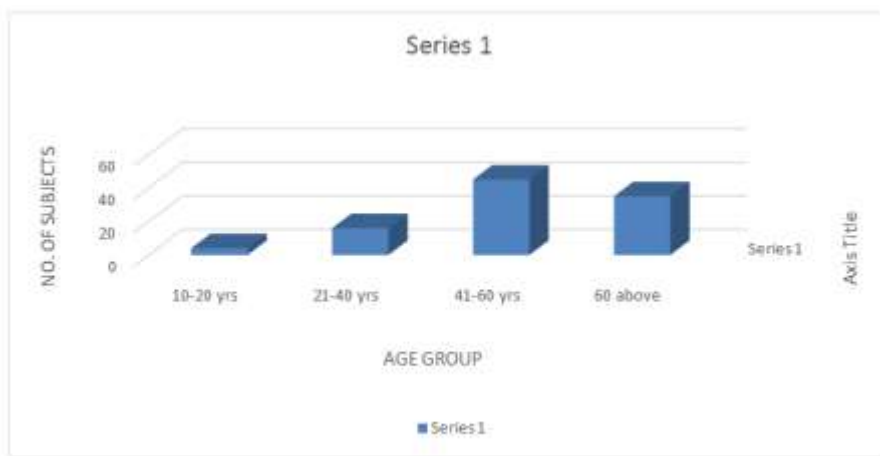


TABLE 2- GENDER WISE DISTRIBUTION

GENDER	NO.OF CASES
Male	54
Female	46
Total	100

In our study the male incidence was (54%); and female incidence(46%)

GRAPH 2- GENDER WISE DISTRIBUTION:

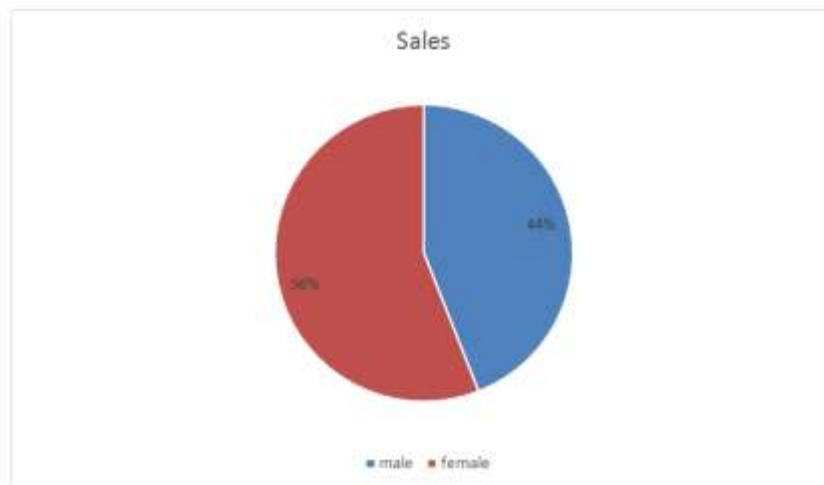
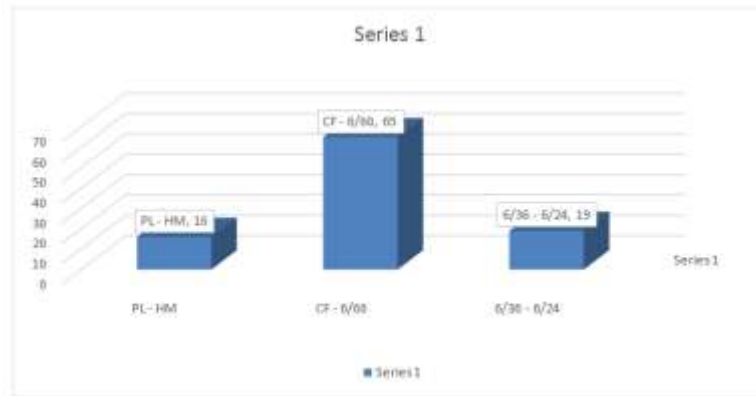


TABLE 3 - VISUAL ACUITY BEFORE CAPSULOTOMY

SL.NO	VISUAL ACUITY	NO.OF PATIENTS	PERCENTAGE
1	PL-HM	16	16%
2	CF-6/60	65	65%
3	6/36-6/24	19	19%
TOTAL		100	100%

In our study, the majority of patients are in CF-6/60 visual acuity range(65%).

GRAPH 3- VISUAL ACUITY BEFORE CAPSULOTOMY



Cases with visual acuity of less than 6/24 also insisted for laser capsulotomy, because they were not satisfied with their vision to carry out their professional work.

TABLE 4 - DURATION BETWEEN CATARACT SURGERY AND LASER CAPSULOTOMY

SL.NO	DURATION	NO.OF CASES	PERCENTAGE
1	3-6 months	10	10%
2	6-12 months	18	18%
3	12-24 months	21	21%
4	24-36 months	43	43%
5	>36 months	08	8%

Most of the cases reported for decreased vision due to PCO fall within the period of 2.2 yrs following cataract surgery

GRAPH4- DURATION B/W CATARACT SURGERY AND LASER CAPSULOTOMY

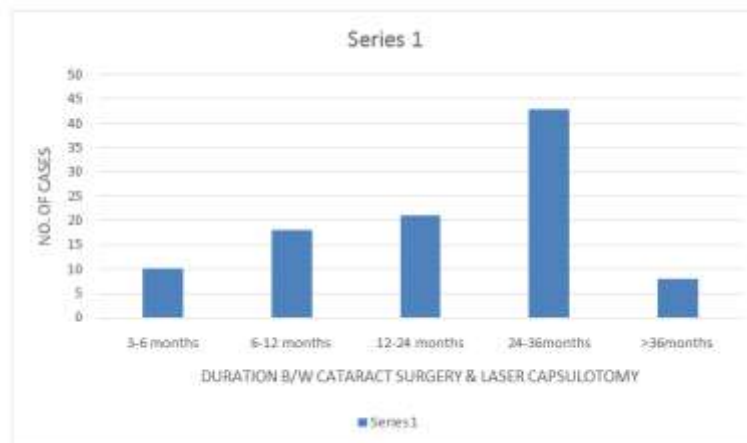


TABLE 5 - GRADING OF PCO

Posterior capsular opacification has been graded as mild, moderate and severe depending upon the visibility of fundus by direct and indirect ophthalmoscopy as follows:

GRADING OF PCO	VISIBILITY OF FUNDUS	NO.OF CASES
Mild	By direct ophthalmoscopy	19
Moderate	By indirect ophthalmoscopy	66
Severe	No fundus view	15

B-scan was done in cases where the media is not permissible for fundus examination

GRAPH 5- GRADING OF PCO:

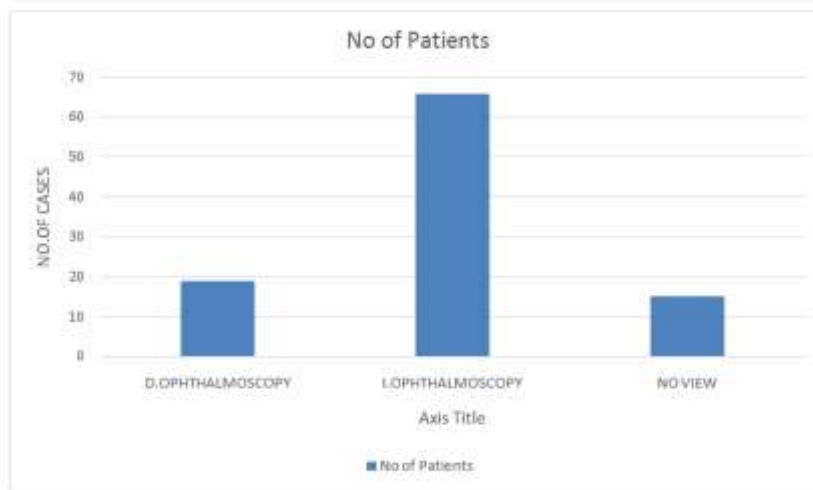


TABLE: 6 - AMOUNT OF ENERGY USED FOR CAPSULOTOMY

Sl.NO	TOTAL ENERGY	NO.OF CASES	PERCENTAGE
1	<50mj	19	19%
2	51-100mj	38	38%
3	101-150mj	23	23%
4	151-200mj	14	14%
5	201-250mj	6	6%
TOTAL		100	100%

Mean energy used per shot was 2.0-3.0mj. In most of the cases energy used was ranging from 50-200mj according to the density of PCO.

GRAPH 6- AMOUNT OF ENERGY USED FOR CAPSULOTOMY

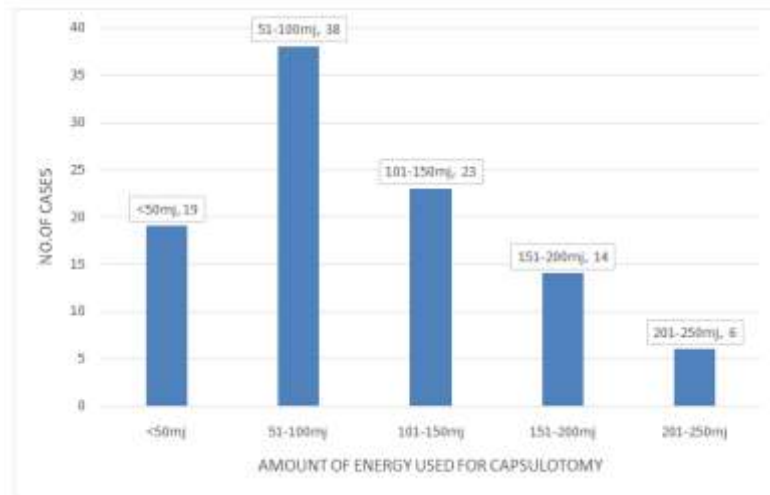


TABLE:7 - IMMEDIATE POST LASER COMPLICATIONS:

Sl.NO	COMPLICATIONS	NO.OF CASES	PERCENTAGE
1	Iris bleeds	2	2%
2	Pitting of IOL	11	11%
3	Rupture of anterior hyaloid face	1	1%

The immediate post laser complications are mainly due to inaccurate focusing of laser beam and usage of higher amount of energy

GRAPH 7- IMMEDIATE POST LASER COMPLICATIONS:

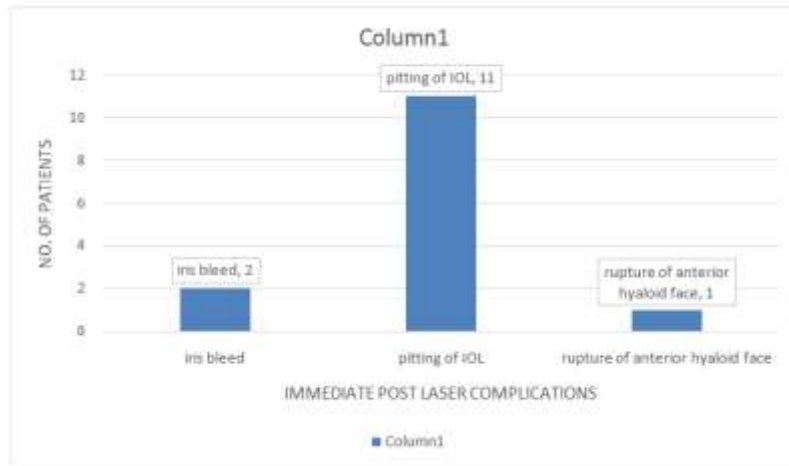


TABLE: 8 IOP WITHIN 24 HRS FOLLOWING CAPSULOTOMY

SI.NO	DURATION	10-21mm Hg	22-25mm Hg	26-30mm Hg
1	1sthr	80	20	Nil
2	4thhr	76	24	Nil
3	24thhr	90	8	02

In most of the cases IOP came down to normal range at the end of 24 hrs

GRAPH 8- IOP WITHIN 24 HRS FOLLOWING CAPSULOTOMY

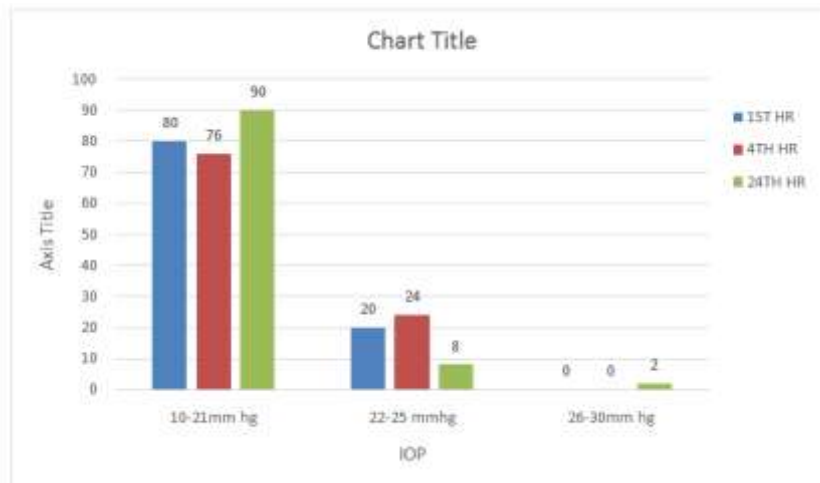
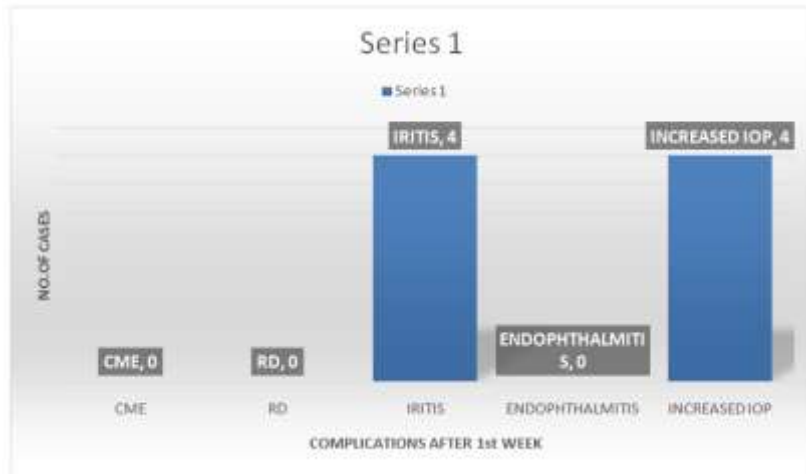


TABLE:9 - NO.OF CASES WITH COMPLICATIONS AT THE END OF 1st WEEK-(81) .

SI.NO	COMPLICATION	NO.OF CASES	PERCENTAGE
1	CME	NIL	NIL
2	RD	NIL	NIL
3	IRITIS	04	5%
4	ENDOPHTHALMITIS	NIL	NIL
5	INCREASED IOP	04	5%

At the end of 1st week, nearly 81 cases came for follow up, out of which 4 cases(5%) ofiritis and 4 cases(5%) of increased IOP were noted.

GRAPH 9- COMPLICATIONS NOTED AT THE END OF 1st week:



NO.OF CASES WITH COMPLICATIONS AT THE END OF 1ST MONTH: 66

TABLE: 10

Sl.NO	COMPLICATION	NO.OF CASES	PERCENTAGE
1	CME	01	1.51%
2	RD	NIL	NIL
3	IRITIS	01	1.51%
4	ENDOPHTHALMITIS	NIL	NIL
5	INCREASED IOP	02	3.02%

At the end of 1st month, 66 cases came for follow up, out of which 1 case (1.51%) of iritis and 1 case of CME (1.51%) have been recorded and 2 cases (3.02%) have reported an increased IOP.

GRAPH 10- COMPLICATIONS NOTED AT THE END OF 1 MONTH:

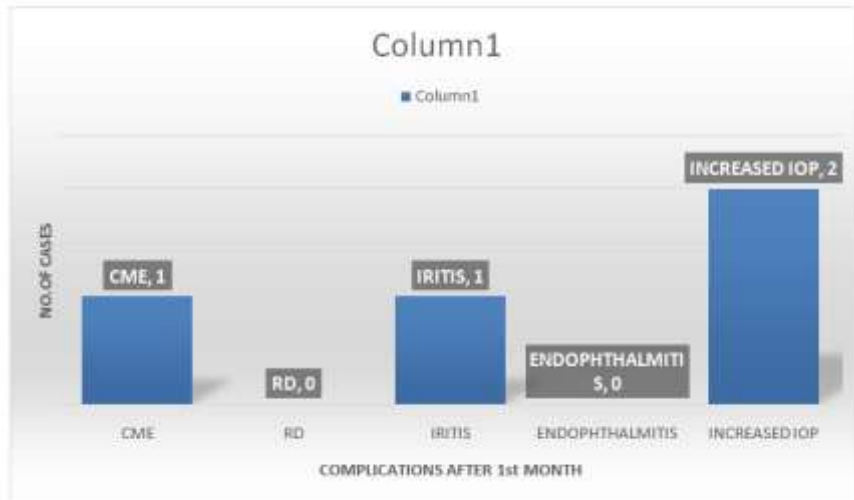
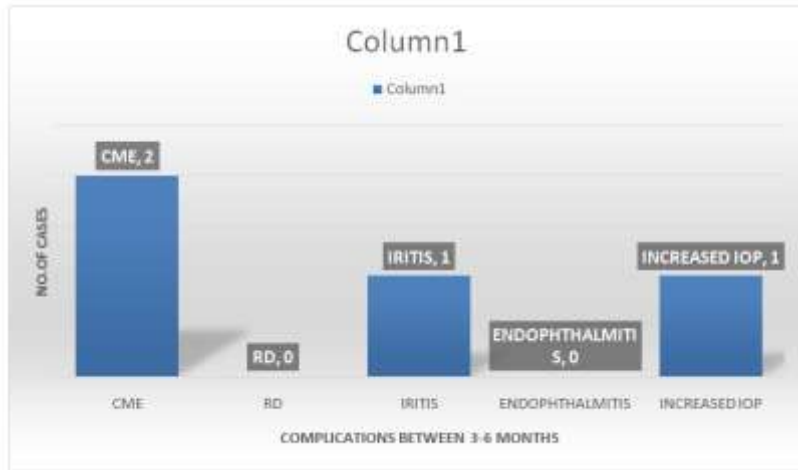


Table-11: NO.OF CASES WITH COMPLICATIONS BETWEEN 3-6 MONTHS : (52)

Sl.NO	COMPLICATION	NO.OF CASES	PERCENTAGE
1	CME	02	3.84%
2	RD	NIL	NIL
3	IRITIS	01	1.92%
4	ENDOPHTHALMITIS	NIL	NIL
5	INCREASED IOP	01	1.92%

Between the period of 3-6 months 52 cases came for follow up, out of which 2 (3.84%) cases have been noticed with CME, 1 (1.9%) case each of iritis and increased IOP have been noticed

GRAPH 11- COMPLICATIONS NOTED BETWEEN PERIOD OF 3-6 MONTHS

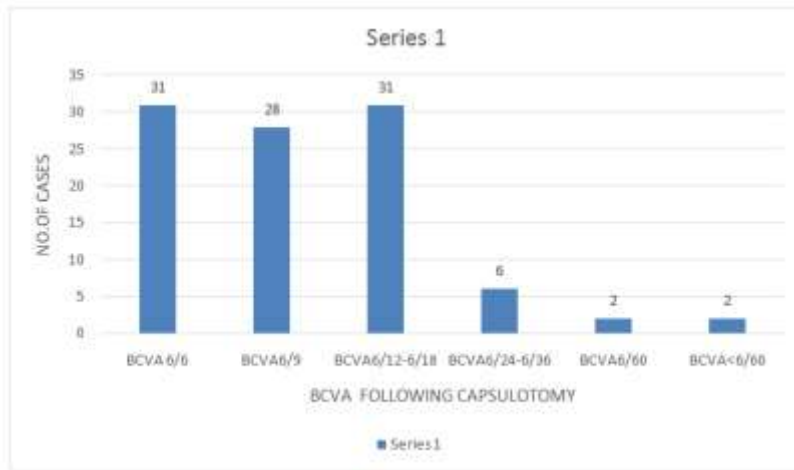


VISUAL OUTCOME FOLLOWING CAPSULOTOMY: Table 12

SLNO	BCVA	NO.OF CASES	PERCENTAGE
1	6/6	31	31%
2	6/9	28	28%
3	6/12-6/18	31	31%
4	6/24-6/36	6	6%
5	6/60	2	2%
6	< 6/60	2	2%
TOTAL		100	100%

Most of the cases with poor visual outcome (6/60 and less) are mainly due to pre-existing ocular pathologies. 90% of the cases had a visual outcome between 6/18-6/6.

GTAPH 12- VISUAL OUTCOME FOLLOWING CAPSULOTOMY :



ENERGY VS COMPLICATIONS: TABLE 13

SLNO	TOTAL ENERGY	NO.OF CASES	RAISED IOP at 4thhr	IRITIS AT END OF 1st WEEK	CME
1	<50mj	19	01	nil	Nil
2	51-100mj	38	07	nil	Nil
3	101-150mj	23	08	01	Nil
4	151-200mj	14	05	02	01
5	201-250mj	6	03	01	01

Cases reported with complications received higher amount of energy

GRAPH 13-ENERGY Vs COMPLICATIONS

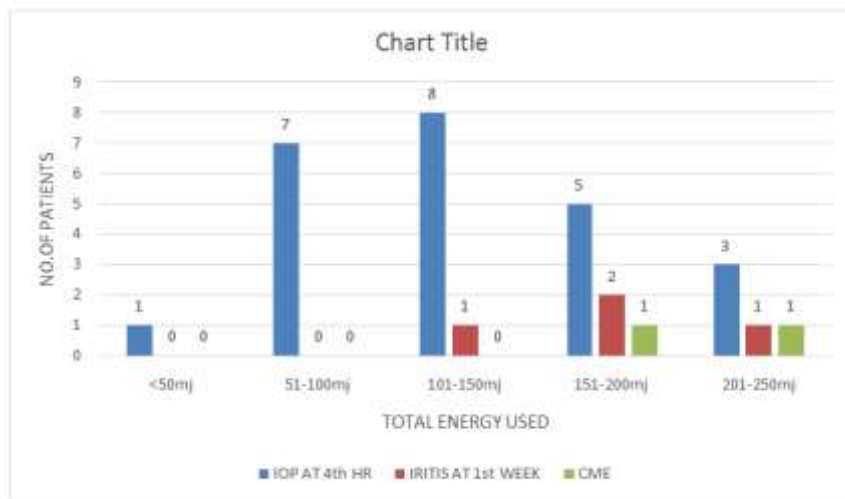
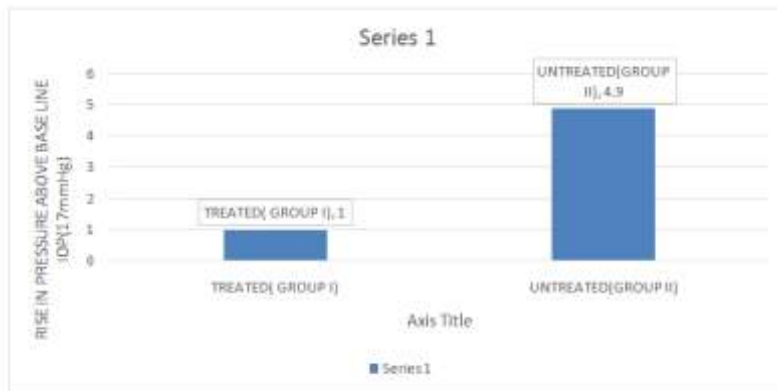


TABLE 14: MEAN IOP IN PATIENTS RECEIVED POST LASER MEDICATION vs. NOT RECEIVED

GROUP	NO.OF CASES	MEAN IOP AT 24 HRS	RISE IN PRESSURE ABOVE BASELINE IOP(17mmHg)
Untreated(GROUP II)	40	21.9mm	4.9mm
Treated(GROUP I)	60	18mm	1mm
total	100		

Mean IOP pre-laser (100 patients) 17mmHg
 Mean IOP at 24 hrs in treated patients(60 patients) GROUP I- 18mmHg
 Mean IOP at 24hrs in untreated patients(40 patients) GROUP II- 21.9mmHg.
 Rise above baseline IOP in: GROUP I - 1mmHg
 GROUP II - 4.9mmHg resp.



V. Discussion

Nd:YAG laser posterior capsulotomy is a frequently performed procedure after cataract surgery, because PCO is the most common complication of cataract surgery. PCO is more frequently seen in children and young adults, in spite of using the latest technique of cataract surgery. The practice of Nd:YAG laser has definitely simplified the management of PCO as it being a non-invasive procedure.

This is a short term prospective study of 100 cases, with aims to evaluate the visual outcome and post laser complications (both immediate and late) following Nd :YAG laser posterior capsulotomy.

On the review of available literature the outcome of this study can be discussed as follows:

In our study of 100 cases, the time interval between the cataract surgery and Nd:YAG laser posterior capsulotomy was 1 year. This is in accordance with the Hasan KS et al study⁸ and Kundi NK et al study where the mean duration was 2.49 yrs and 2 yrs respectively.

IMMEDIATE POST LASER COMPLICATIONS:1)Iris bleeding:

Haris WS¹³ et al in his study of 342 eyes found iris bleeding in 4 cases (1.16%) during laser capsulotomy.

In our study of 100 cases, iris bleeding has been noticed in 2 cases, which accounts for 2%. This complication is mainly due to inaccurate focusing of laser beam and usage of high amount of energy in cases of dense PCO.

Pitting of IOL:

Bilal Khan et al study: conducted a prospective study from May 2012 – May 2013 at Khyber eye foundation. In his study of 406 patients, intraocular lens pitting was the most common complication seen in 56 eyes which accounts for (12.81%). Haris WS13 et al study showed 11.7% patients with IOL pitting in total of 342 eyes. Incidence of IOL pitting seen in various other studies is:

- Shah et al study showed- 14%
- Burq MA et al study showed- 19.2%
- Khan MY et al study showed- 22.4%
- Jawed EA et al study showed- 13.33%
- Richter et al study- 25%

study	bilal9khan et al	haris13ws	shah6et al	1	Burq4 et al	khan5 my et al	present study
pittingiol(%)	12.81%	11.7%	14%		19.2%	22.4%	11%

Rupture of Anterior Hyaloid Face:

Haris WS13 et al has mentioned vitreous in anterior chamber in 15(4.4%) cases in a study of 342 eyes. In our study we have noticed only one case (1%) of ruptured anterior hyaloid face with vitreous in anterior chamber..

COMPLICATIONS SEEN IN FOLLOW UP:

Increased intraocular pressure

In our study, incidence of transient elevation of IOP between 22-25mmHg was noticed in 24 cases within 4hrs after capsulotomy. In most of the cases IOP came down to normal range at the end of 24hrs.

In our study, out of 100 cases, 60 cases were given immediate post laser topical medication and the remaining 40 cases were not given any treatment for the first 24 hrs. The main aim of dividing cases in to 2 groups was to look for any rise in IOP following capsulotomy without post laser topical medication.

In the GROUP I in whom post laser treatment was given, mean rise in IOP was only 1mm hg above the pre laser base line IOP of 17mmhg at the end of 24hrs. In GROUP II patients mean rise above the pre laser base line IOP was 4.9 mm Hg. This showed a significant rise in IOP in GROUP II patients when compared to GROUP I patients

RISE IN MEAN IOP ABOVE PRE LASER BASE LINE IOP:

DURATION	MARIANN M study	PRESENT STUDY
1st hour	8.7mm	7.1mm
4th hour	7.4mm	5.8mm
24th hour	5.5mm	4.9mm

Keates8 et al study has found persistent iritis in (0.4%) after 6months of follow up. Chambless et al study has found persistent iritis in (1.4%) after a follow up of 7 months. Gore et al reported that 33.5% of patients had iritis after laser capsulotomy manifested with flare and cells in anterior chamber on slit lamp examination.

STUDY	Keates8 et al	Chambless et al	Present study
Persistent iritis in %	0.4%	1.4%	1%

In our study of 100 cases, 4 cases have been reported with iritis at end of 1st week, these were given topical steroid and cycloplegics. Out of these 4 cases only 1 case showed persistent iritis (1%).

Retinal detachment:

Bilal Khan et al study 2012 : in his prospective study of 406 eyes from May 2012-13 showed retinal detachment in 2 eyes(0.45%).

Burq et al study 2008: in his study of 104 eyes, incidence of retinal detachment was found to be 1.9%

Shah et al study 1986: showed incidence of 0.17% retinal detachment after laser capsulotomy

In the present study there was no case of retinal detachment reported, because this is a short term study, all cases were not reported for follow up and high risk groups were not included in this study.

Cystoid macular edema:

Incidence of CME in other studies is as follows:

- Steinert6 et al study 1991 : 0.68-1.23%

Albert et al study : showed 5.4%
Winslow and Taylor⁷ et al study: showed <1%

STUDY	Bilal ⁹ Khan et al	Gore ⁶ VS et al	Khanzada ⁷ et al	Raza ⁸ et al	Winslow & Taylor ⁷³	Albert et al	Present study
CME in %	3.87%	4%	3.87%	3%	<1%	5.4%	3.84%

In our study 2 cases of CME have been noticed at 3-6 months follow up (52 patients), following laser capsulotomy, which accounts for (3.84%). Our study is in comparison with Bilal Khan et al (3.89%); Mahtab Alam (3.87%); Gore VS study (4%) and Ali Raza study (3%). These patients have been treated with topical anti-inflammatory drugs for 3 weeks. VA improved slightly but failed to improve more than 6/18.

Visual outcome after capsulotomy:

VS study¹¹ in his study he found out of 200 patients after laser capsulotomy, 183 cases (91.5%) had a visual acuity of 6/18-6/6, 17 cases (8.5%) had a visual acuity of 6/24 or less.

Keates^{rh8} study: in this study of 6800 subjects, 82.9% patients achieved a visual acuity of 20/40 or better. 10% patients had visual acuity 6/24 or less. Our study is in correlation with the Gore VS study.

STUDY	GORE ⁶⁵ VS et al STUDY	PRESENT STUDY
POST LASER BCVA(6/18-6/6)	91.5%	90%

Poor visual outcome: 1) Visual acuity of 6/60 and less has been noticed in 4 cases (4%). This is mainly due to: 1) Pre-existing ocular lesions like optic atrophy, ARMD. 2) Pitting of IOL in the visual axis (1 case) 3) CME following laser capsulotomy.

Limitations of the study: 1) It is a short term study. 2) Some of the cases subjected for the study have not reported for complete follow up.

VI. Summary And Conclusions

A thorough clinical assessment of patients prior to the capsulotomy is preferable.

Post laser topical medication should be given to minimize the complications.

Performing capsulotomy with possible minimal energy avoids the complications.

Post laser capsulotomy complications are mild and transient. Regular follow up of patient is needed to identify the complication and their management. Improvement in visual acuity with ND: YAG laser capsulotomy is rewarding. The results of laser capsulotomy in this study were comparable with other available studies.

ND: YAG laser capsulotomy is a safe and effective method of restoring vision in patients with posterior capsular opacification.

References

- [1]. Schmidbauer JM, Vargas LG, Apple DJ et al. Evaluation of neodymium:yttrium-aluminum-garnet capsulotomies in eyes implanted with AcrySof intraocular lenses. *Ophthalmology* 109(8), 1421-1426 (2002).
- [2]. Dholakia SA, Vasavada AR. Intraoperative performance and longterm outcome of phacoemulsification in age-related cataract. *Indian J. Ophthalmol.* 52(4), 311-317 (2004).
- [3]. Thompson AM, Sachdev N, Wong T, Riley AF, Grupcheva CN, McGhee CN. The Auckland Cataract Study: 2 year postoperative assessment of aspects of clinical, visual, corneal topographic and satisfaction outcomes. *Br. J. Ophthalmol.* 88(8), 1042-1048 (2004).
- [4]. Schaumberg DA, Dana MR, Christen WG, Glynn RJ. A systematic overview of the incidence of posterior capsule opacification. *Ophthalmology* 105(7), 1213-1221 (1998).
- [5]. complications of Nd :YAG laser complications NJ Curtis; J.C. Javitt current opinion in ophthalmology-(1994)
- [6]. MacEwen CJ, Dutton GN. Nd YAG laser in the management of posterior capsular opacification- complications and current trends. *Trans Ophthalmol Soc U.K* 1986; 105:307-44
- [7]. Prajna NV, Ellwein LB, Selvaraj S, Manjula K, Kupfer C. The Madurai intraocular lens study IV: posterior capsule opacification. *Am J Ophthalmol* 2000; 130: 304-309.
- [8]. Hasan KS, Adhi MI, Aziz M, et al. Nd: YAG laser Posterior Capsulotomy. *Pak J Ophthalmol* 1996; 12: 3-7.
- [9]. Gore V.S., The study of complications of Nd: YAG laser capsulotomy. *International Journal of Bioinformatics Research.* 2012; 4(2): 265-268.
- [10]. Hussain MM. Complications after Nd: YAG laser capsulotomy. *Pak J Ophthalmol* 1996; 12: 13-5
- [11]. Ejaz Ahmad Javed, Muhammad Sultan, et al. Nd: YAG laser capsulotomy and complications. *Professional Med J Dec* 2007; 14(4): 616-619
- [12]. Ficker LA, Steele AD. Complications of Nd: YAG laser posterior capsulotomy. *Trans Ophthalmol Soc UK.* 1989; 104:529-32
- [13]. Harris WS, Herman WK, Fagadu WR. Management of the posterior capsule before and after the YAG laser. *Trans Ophthalmol Soc UK.* 1985; 104:533-5
- [14]. Fastenberg DM, Schwartz PL, and Lin HZ. Retinal detachment following neodymium - YAG laser capsulotomy. *Am J Ophthalmol* 1984; 97:288

Dr.P.Sambasiva Reddy, "Prospective Study on ND: YAG Capsulotomy & Complications." *IOSR Journal of Environmental Science, Toxicology and Food Technology (IOSR-JESTFT)* 13.2 (2019): 01-12.