

## A case study on Extra Corporeal Membrane Oxygenation for Airlifted case with Covid-19 Pneumonia

Gorremuchu Kezia rani

(senior nursing educator, Apollo hospital jubilee hills)

Dini C Davis

(assistant nursing superintendent, apollo hospital jubilee hills)

Gayathri.I.V

(diabetic educator, Apollo hospital jubilee hills)

Sunita mitchel domingo

(Regional nursing director apollo Telangana region)

Mini jose

(Nursing Superintendent,)

Maryline Flinsi

(Principal Apollo school of nursing Delhi)

---

### Abstract

Extracorporeal Membrane Oxygenation (ECMO) is a life-support technique used in patients with severe cardiac or respiratory failure when conventional therapies, including cardiopulmonary resuscitation (CPR), are unsuccessful. ECMO functions by diverting blood from the body through a circuit where it is oxygenated and returned, allowing the heart and lungs to rest and recover. The system typically includes two cannulas: a drainage cannula that removes deoxygenated blood and a return cannula that delivers oxygenated blood back into circulation. There are two main types of ECMO. Veno-venous (VV) ECMO, primarily used for severe respiratory failure. Veno-arterial (VA) ECMO, used for cardiac or cardiorespiratory failure. During ECMO support, anticoagulation monitoring is critical to maintain a delicate balance between thrombosis and bleeding risks. Continuous heparin administration is commonly used, necessitating close monitoring due to potential complications such as Heparin-induced thrombocytopenia (HIT) Neurological complications, including ischemic or haemorrhagic stroke Infections and sepsis, which can worsen outcomes and complicate management. Outcomes with ECMO have improved in recent years, especially in conditions such as cardiac arrest, cardiogenic shock, and acute respiratory distress syndrome (ARDS), including cases caused by COVID-19. Careful patient selection and expert multidisciplinary management are essential for optimizing survival and minimizing complication

**Key words:-** ECMO – Extra corporeal Membrane Oxygenation, ARDS-Acute Respiratory Distress Syndrome, VV ECMO- Veno-venous Extra corporeal Membrane, VA ECMO-Veno arterial Extra corporeal membrane

---

Date of Submission: 11-06-2025

Date of Acceptance: 23-06-2025

---

### I. Introduction

Extracorporeal membrane oxygenation (ECMO) provides both respiratory and cardiac support and is utilized as a rescue therapy in cases of severe respiratory or cardiac failure. Severe acute respiratory syndrome coronavirus 2 (SARS-CoV-2), the virus responsible for coronavirus disease 2019 (COVID-19), first emerged in Wuhan, China in December 2019. As of April 2020, the global COVID-19 pandemic had resulted in an estimated case-fatality rate of approximately 6.8% [1]. According to data from the Johns Hopkins Center for Systems Science and Engineering (CSSE), by mid-October 2020, there were over 39 million reported cases worldwide, with more than 1 million deaths [2]. While the majority of COVID-19 infections are asymptomatic or mild, around one-third of patients require admission to the intensive care unit (ICU), and nearly 30% develop acute respiratory distress syndrome (ARDS) [1,3]. ECMO was previously demonstrated to be an effective salvage therapy during the 2009 H1N1 influenza pandemic for patients with severe pneumonia and respiratory failure [4]. However, evidence on the use of ECMO in COVID-19-associated pneumonia remains limited. In January 2020, the World Health Organization (WHO) issued interim guidance regarding the use of ECMO in COVID-19 patients [5]. Despite the limited data, the National Institutes of Health (NIH) has included ECMO as a potential therapeutic option in its treatment guidelines for COVID-19 [6].

Survival for patients with ICATT's ECMO varies between 30% and 50%, depending on the cause of the cardiac dysfunction[7]. ECMO can be considered in patients with systolic blood pressure below 85 mm Hg. If the cardiac index is below 1.2-litre min/m<sup>2</sup> despite sufficient preload, more than two inotropes are used, intra-aortic balloon counter pulsation (IABP) and signs of low systemic levels of cardiac output.[7,8]

Chief complaints, history of presenting illness, past history, family history, previous medical assessment involving any hospitalisations, investigations, diagnosis, medical management, indications for ECMO, complications during ECMO, post procedure status emphasizing on clinical status and role of nurses in improvement of clinical status at every stage leading to successful discharge from ICU, transit to ward, ward care, discharge from hospital and follow up

**Results:** The patient, initially presenting with hypoxemia and dyspnea, underwent successful veno-venous extracorporeal membrane oxygenation (VV-ECMO) support. Post-procedure, the patient's recovery was uneventful, demonstrating significant improvement in respiratory function during hospitalization. This outcome underscores the efficacy of ECMO as a life-saving intervention for severe respiratory failure.

**Conclusion:** In patients undergoing ECMO, COVID-19-associated pneumonia was associated with poorer outcomes compared to non-COVID-19 pneumonia, independent of sociodemographic characteristics and comorbidity burden.

**Key words:-** ECMO – Extra corporeal Membrane Oxygenation, ARDS-Acute Respiratory Distress Syndrome, VV ECMO- Veno-venous Extra corporeal Membrane, VA ECMO-Veno arterial Extra corporeal membrane

## II. Case Description

A 34-year-old gentleman from Patna tested positive for COVID-19 and was admitted to a local hospital, where he was initiated on non-invasive ventilatory support, along with intravenous antibiotics and corticosteroids. Due to clinical deterioration, he was transferred to another hospital, where he developed bilateral pneumothoraces, necessitating insertion of bilateral intercostal chest drains.

Despite these interventions, the patient remained hypoxic, with oxygen saturation persistently below 75%, and was subsequently intubated and placed on mechanical ventilation. As his condition failed to improve on maximal ventilatory support, veno-venous extracorporeal membrane oxygenation (VV-ECMO) was initiated via the right internal jugular vein and right common femoral vein by the Apollo ECMO team.

He was airlifted to Apollo Hospitals, Jubilee Hills, for advanced care. Upon arrival, the patient was sedated, paralyzed, and hemodynamically stable, with oxygen saturation of 98% on 7 L/min oxygen via ECMO and FiO<sub>2</sub> 0.5 on the ventilator.

On day 2 post-transfer, weaning from mechanical ventilation was initiated. Due to difficulty in weaning, a percutaneous tracheostomy was performed. Bronchoscopy revealed mild mucoid secretions. Subsequently, chylous drainage was noted from the right chest tube, for which the patient was started on a medium-chain triglyceride (MCT) diet. The chylous effusion resolved with this intervention.

On day 11, the patient developed painful bluish discoloration of the toes. Venous Doppler studies ruled out deep vein thrombosis, and arterial Doppler showed normal arterial flow. Microvascular thrombosis was suspected based on hematology consultation, and antiplatelet agents with vasodilatory properties were initiated. The toe discoloration gradually improved.

The patient experienced episodes of melena during hospitalization, for which he was started on pantoprazole infusion. He developed anemia and thrombocytopenia, with deranged liver function and coagulation parameters. *Acinetobacter* species were isolated from blood cultures, and minocycline was initiated. Multiple blood and blood product transfusions were administered as needed.

On day 17, the patient was successfully weaned off ECMO and decannulated. He remained hemodynamically stable and was alternated between T-piece and CPAP ventilation. He was gradually weaned off the ventilator, maintaining adequate oxygenation on T-piece with decreasing flow rates.

The patient's caloric intake was optimized, and he began weight-bearing exercises with physiotherapy support. He was mobilized to a chair, and the left-sided chest drain was removed. However, he developed a recurrent left-sided pneumothorax, for which a CT-guided pigtail catheter was inserted.

Tracheostomy decannulation was done approximately one month after placement. At the time of discharge, the patient was symptomatically improved, hemodynamically stable, and maintaining SpO<sub>2</sub> of 98% on 1 L/min oxygen. The patient was discharged home in stable condition.

## A case study on Extra Corporeal Membrane Oxygenation for Airlifted case with Covid-19 Pneumonia

### Progress on ECMO


Parameters	Day 2	Day 3	Day 5	Day 8	Day 11	Day 14	Day 16	Day 17
ECMO Fio2	100	100	100	100	70	60	21	21
Sweep Gas Flow	5	7	7	4	5	4	2.5	1
Pre-oxygenator pressure	144	139	135	131	98	106	90	53
Post-oxygenator pressure	128	128	98	111	69	94	71	40
Delta oxygenator pressure	16	11	37	20	29	12	19	13
Pump RMP	2880	2880	2720	2695	2400	2375	1910	1689
Heparin Dose(ml)	2	1.8	1.6	1.5	1.6	nil	1.9	2.4
ACT	128	142	194	179	210	123	206	146

### Lab reports

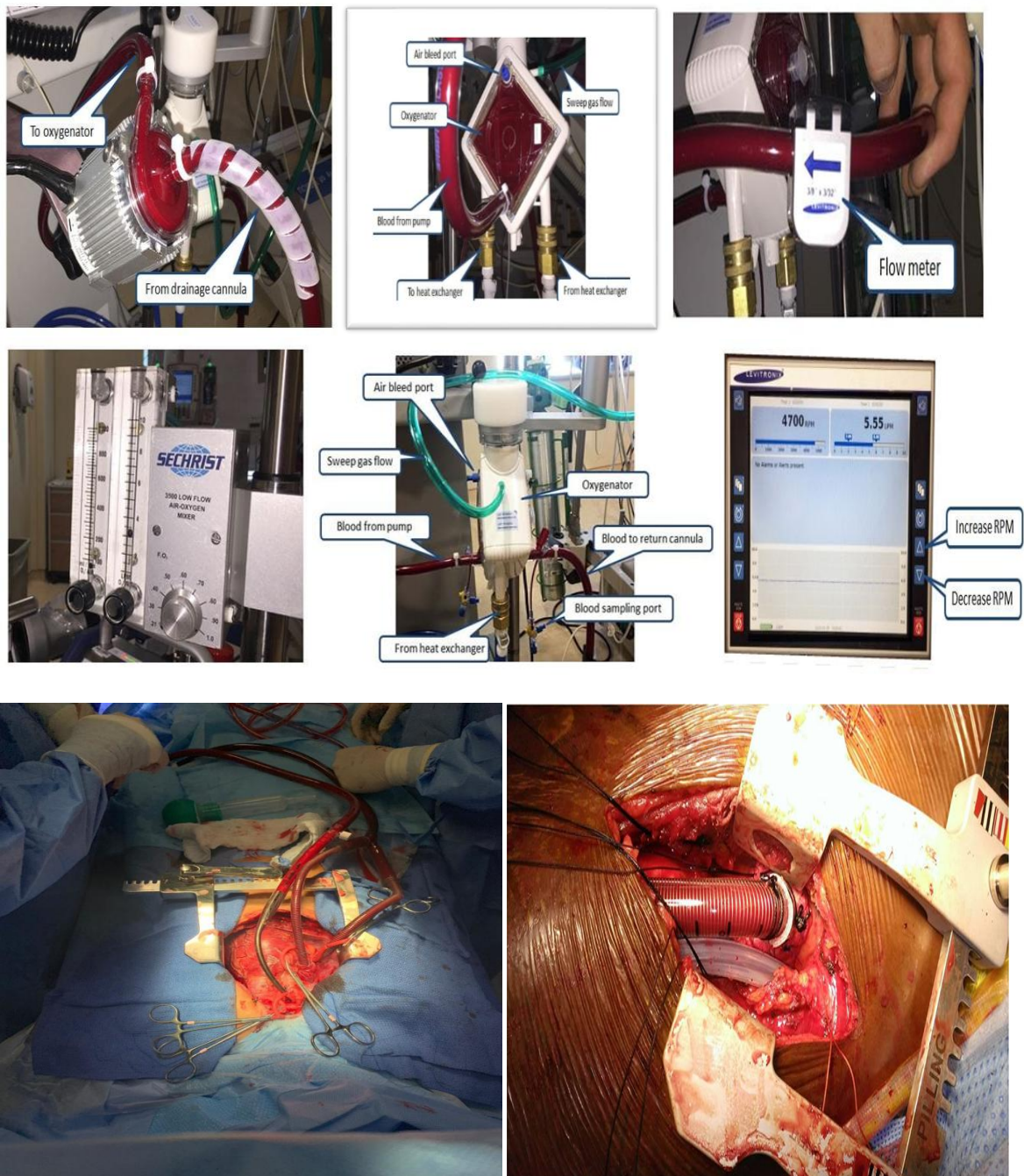
INVESTIGATIONS	Day2	Day5	Day8	Day11	DAY14	DAY17	DAY18
Hemoglobin(gm/dl)	10.4	9.2	10.4	9.1	8.6	8.7	10.6
Platelet(x1000/cumm)	1.30	1.1	2.09	1.81	1.21	52,000	79,000
INR	1.16	1.31	1.23	1.15	13	-	1.24
Fibrinogen(mg/dl)	426	317	331	-	151		
APTT(sec)	48	39.4	40.8	-	30		77.1
D-dimer(ng/ml)	776	-	1847	-	5478	8379	3085
Ferritin(microgram/L)	1334	695	-	-	-	-	
CRP(mg/dl)	80.7	38.2	65.5	-	76.5	-	49.9

### Infection Prevention:

- Hand hygiene was performed by following of six steps for 5 moments
- Aseptic precautions while handling line
- Scrub the hub and close all the ports with alcohol swab or curo caps
- Ports should be covered with sterile drape all the time
- Cleaning of equipment every shift
- Linen to be sterilized before use for the patient



## ECMO CIRCUIT IN OUR HOSPITAL



Care of Central Line:

Complete aseptic technique maintained throughout the stay

### Drugs

SL NO	DRUG NAME	DOSAGE	INDICATION	ROUTE	6AM	8AM	2PM	6PM	8PM	DURATION
1	T.ELIQUIS	2.5MG	ANTICOAGULANT	ORALLY	-	-	-	-	-	CONTINUE
2	T.MET-XL	50MG	TACHYCARDIA	ORALLY	-	-	-	-	-	CONTINUE
3	T.THYRONORM	100MCG	HYPOTHYROIDISM	ORALLY	-	-	-	-	-	CONTINUE
4	T.VIT -D3	60K	VITAMIN D	ORALLY	-	-	-	-	-	ONCE A WEEK AS PER ADVICE
5	T.A-Z	1 TAB	MULTIVITAMIN	ORALLY	-	-	-	-	-	1MONTH

## *A case study on Extra Corporeal Membrane Oxygenation for Airlifted case with Covid-19 Pneumonia*

6	T.PANCREOFLAT	1 TAB	GASTRITIS	ORALLY	-	-	-	-	2 WEEKS
7	T.RESTYL	0.25MG	SLEEP	ORALLY	-	-	-	-	IF REQUIRED FOR SLEEP
8	SYP.DUPHALAC	30ML	LAXATIVE	ORALLY	-	-	-	-	IF REQUIRED FOR CONSTIPATION
9	T.MONTEK-LC	1 TAB	ALLERGY	ORALLY	-	-	-	-	1 WEEK
10	T.PIRFINIX	400MG	FIBROSIS	ORALLY	-	-	-	-	CONTINUE AS PER PULMONOLOGIST
11	T.MEDROL	2MG	STEROID	ORALLY	-	-	-	-	AS PER PULMONOLOGIST ADVICE
12	T.ZOFER MD	8MG	NAUSEA/VOMITING	ORALLY	-	-	-	-	3 DAYS & IF REQUIRED FOR VOMITING/NAUSEA
13	T.DOLO	650MG	PAIN	ORALLY	-	-	-	-	IF REQUIRED FOR PAIN
14	T.IVABRAD	7.5MG	TACHYCARDIA	ORALLY	-	-	-	-	CONTINUE
15	OXYGEN INHALATION	1-2 LITRE	SOB	PER NASAL	-	-	-	-	TO MAINTAIN SPO2 MORE THAN 90%
16	OINT.SILODERM	-	SKIN CARE	LOCAL APPLY	-	-	-	-	TILL REVIEW
17	NEOSPORIN OINTMENT	-	NASAL BRIDGE WOUND	NASAL BRIDGE APPLY	-	-	-	-	TILL REVIEW
18	NEBZMART-G NEB	0.5ML	BRONCHOSPASM	PER NASAL	-	-	-	-	CONTINUE AS PER PULMONOLOGIST
19	FORACORT NEB	1 RESP	BRONCHOSPASM	PER NASAL	-	-	-	-	CONTINUE AS PER PULMONOLOGIST

### **Nutritional needs**

On admission: - 50 ml 2<sup>nd</sup> hourly Nasogastric feed was given i.e. 930(Kcal) and protein 47gm. As per patient tolerance feed was increased to 120ml 2<sup>nd</sup> hourly feed i.e. Energy 2223(kcal) and protein 113gm along with oral double soft diet as per patient preference.

**Patient and Family Education:** Patient and family education is a collaborative team effort that begins the moment the patient or their family engages with the ECMO team and continues throughout the entire ECMO journey. The ECMO nurse plays a pivotal role in this process. As they are consistently present at the bedside, they become the primary point of contact for the patient and their family. The ECMO nurse bears the crucial responsibility of providing ongoing education and emotional support, ensuring that families understand the purpose, process, and potential complications of ECMO therapy.

In addition to explaining the technical aspects of ECMO, nurses also play a key role in reinforcing the importance of Isolation practices and infection control policies, Strict hand hygiene, Personal hygiene and safe caregiving practices. By fostering a clear, compassionate, and continuous dialogue, the ECMO team helps reduce anxiety, build trust, and empower families to participate meaningfully in the care and recovery process.

**Follow-up care:** Provide ongoing support and education to promote long-term management and prevention of further complication

**Acknowledgments:-** We extend our sincere gratitude to the patient and their family for their unwavering cooperation and consent in sharing the details of this Extra Corporeal Membrane Oxygenation for Airlifted case with Covid-19 Pneumonia. Their willingness to contribute to medical literature is commendable and has played a pivotal role in advancing our understanding of this rare pneumonia condition.

We also express our appreciation to the healthcare team involved in the comprehensive care of the patient. The dedication and expertise of the physicians, surgeons, nurses, and supporting staff have been instrumental in the successful diagnosis, treatment, and recovery of the patient. Once again, our heartfelt appreciation goes to everyone who played a role in bringing this case study to fruition. This case study contributes valuable insights

into the clinical course and management of Extra Corporeal Membrane Oxygenation for Airlifted case with Covid-19 Pneumonia

### III. Conclusion

It was an anxiously anticipated and unforgettable moment filled with pride and joy for all health care workers when after much hard work and untiring persistent care that this young man was finally weaned and decannulated on 17<sup>th</sup> day of ECMO

### Reference

- [1]. Cao Y, Liu X, Xiong L, et al. Imaging and clinical features of patients with 2019 novel coronavirus SARS-CoV-2: a systematic review and meta-analysis. *J Med Virol.* 2020. April;92(9):1449–1459. . Epub ahead of print. [DOI] [PMC free article] [PubMed] [Google Scholar]
- [2]. COVID-19 dashboard by the centers for systems science and engineering (CSSE) at Johns Hopkins University. Available from: <https://www.arcgis.com/apps/opsdashboard/index.html#/bda7594740fd40299423467b48e9ecf6>.
- [3]. Tzotzos SJ, Fischer B, Fischer H, et al. Incidence of ARDS and outcomes in hospitalized patients with COVID-19: a global literature survey. *Crit Care.* 2020;24(1):516. [DOI] [PMC free article] [PubMed] [Google Scholar]
- [4]. Australia and New Zealand Extracorporeal Membrane Oxygenation (ANZ ECMO) Influenza Investigators . Extracorporeal membrane oxygenation for 2009 influenza A(H1N1) acute respiratory distress syndrome. *JAMA.* 2009;302(17):1888–1895. [DOI] [PubMed] [Google Scholar]
- [5]. World Health Organization: clinical management of severe acute respiratory infection when novel coronavirus (nCoV) infection is suspected. Available from: <https://www.who.int/docs/default-source/coronaviruse/clinical-management-of-novel-cov.pdf>.
- [6]. National Institutes of Health (NIH) . COVID-19 treatment guidelines panel. Coronavirus diseases 2019 (COVID-19) treatment guidelines. Available from: <https://www.covid19treatmentguidelines.nih.gov/critical-care/>. [PubMed]
- [7]. Hou X, Guo L, Zhan Q. Extracorporeal membrane oxygenation for critically ill patients with 2009 influenza A (H1N1)-related acute respiratory distress syndrome: preliminary experience from a single center. *Artif Organs.* 2012;36(09):780–786. doi: 10.1111/j.1525-1594.2012.01468.x. [DOI] [PubMed] [Google Scholar]
- [8]. Bednarczyk JM, White CW, Ducas RA, Golian M, Nepomuceno R, Hiebert B, Bueddefeld D, Manji RA, Singal RK, Hussain F, et al. Resuscitative extracorporeal membrane oxygenation for in hospital cardiac arrest: a Canadian observational experience. *Resuscitation.* 2014;85(12):1713–1719. doi: 10.1016/j.resuscitation.2014.09.026. [DOI] [PubMed] [Google Scholar]