

## Histopathological analysis of appendectomy specimens in Calabar, south –southern Nigeria

A J Omotoso<sup>1</sup>, M A Nnoli<sup>1</sup>, IE Bassey<sup>1</sup>, A O Akintomide<sup>2</sup>, O E Ngim<sup>3</sup>,  
I A Ekanem<sup>1</sup>

<sup>1</sup>Department of Pathology, University of Calabar

<sup>2</sup>Department of Radiology, University of Calabar Teaching Hospital Calabar

<sup>3</sup>Department of Surgery, University of Calabar

---

### Abstract

**Background:** Appendectomy is one of the commonest surgical intervention worldwide with a very high incidence in Nigeria. The various histologic patterns of these lesions are diverse with little information about this in this part of the country.

**Aim:** To analyse various histologic pattern of appendectomy specimens received in University of Calabar teaching Hospital.

**Materials and Methods:** This is an eleven year (1999-2009) retrospective study involving review of the histologic records of all patients with gastrointestinal lesions received in the Department of Pathology, UCTH. The patients' biodata and histologic diagnosis were retrieved. Analysis was done using simple statistical operation.

**Results:** We found that 46.2% of all the gastrointestinal lesions were appendectomy specimens: Out of these, 44.7% were acute appendicitis with or without complications while 7.8% belong with appendix specimens that either had no pathology or were autolysed and the remaining 48% show either reactive lymphoid hyperplasia or appendix with chronic inflammatory response. There was no neoplasia or carcinoid found among the lesions. Furthermore, we found a male to female incidence of 1: 1.45 for the acute appendicitis, with the mean age being 35 and 31years old for males and females. In our series, the youngest patient was 6months old while the oldest was 73.

**Conclusion:** Appendectomy specimen is the commonest gastrointestinal lesion received in Histopathology Department of UCTH, Calabar. Appendicitis remains commoner among the females than the males. Significant number of these patients had lymphoid hyperplasia.

---

### I. Introduction

Appendicitis is an inflammation of the appendix and a common cause of acute abdomen. It occurs at any age but is commonest in the younger age group. The classic history is the onset of central abdominal pain.

Often associated with vomiting which localizes to the right iliac fossa. Examination may show a distressed patient who is febrile, has a coated tongue with foetor oris and has abdominal tenderness to palpation which is maximal in the right iliac fossa. This is usually associated with guarding and rebound tenderness may be present. A full blood count may show a raised white cell count with a neutrophilia.

Appendicitis is the leading cause of surgical emergency admission in most hospital in Nigeria. It accounts for about 15-40% of all emergency surgery done in most centers in the country.<sup>1</sup> All age groups can develop the disease including the fetus in utero, but the incidence is higher in the second and third decade of life. Majority of patients in Nigeria present late with complicated disease<sup>1</sup>. Acute abdominal pain is the most common condition necessitating surgical admission to a pediatric hospital. The vast majority of cases are due to either appendicitis or acute non-specific abdominal pain.<sup>1</sup>

Surgical removal of vermiform appendix (appendectomy) is the treatment of choice for appendicitis. However, patients must be adequately resuscitated before the procedure. Prognosis is excellent. High morbidities and occasional mortalities seen are usually due to late presentation and delay in treatments. Fear of surgery and cost of treatment are the main reason for late presentation. Elechi EN showed a mortality rate of 3% in appendectomy specimens reported in Port Harcourt, complicated appendicitis in this review was largely due to pre-admission delays<sup>2</sup>

It is generally reported to be more common in males<sup>3,4,5</sup> although Mangete from Port-Harcourt and Archibong in Calabar Nigeria, found a significantly higher incidence in females.<sup>6,7</sup>

The investigation of the acute abdomen especially in children has evolved over the years, Ultrasound and Computerised Tomography (CT) scans of the abdomen have increasingly become helpful in reaching a

diagnosis, placing radiologists at the forefront of the evaluation and diagnosis of acute right lower quadrant abdominal problems.<sup>8</sup> Although some worry on the widespread use of CT in children has been expressed concerning radiation. The reported sensitivity of ultrasound varies between 87 and 95% vs 95-97% for helical CT while the specificity ranges between 85 and 98% for ultrasound and 94 and 97% for helical CT.<sup>1,8</sup>

Taurus et al<sup>9</sup> concluded that Ultrasonography is still a useful tool in the diagnosis of acute appendicitis in spite of sophisticated investigations like CT abdomen and laparoscopy; thus, reducing the cost of treatment and preventing negative laparotomies.

Ultrasound criteria for the diagnosis of acute appendicitis include the identification of tubular, non compressive, aperistaltic bowel which demonstrates a connection with caecum and blind terminal. Others include measurement of the antero-posterior diameter, mural thickness, and width of peri-appendicular fat tissue. These are highly significant ultrasound criteria in the evaluation of the appendix inflammation level.<sup>10</sup>

CT is a complementary tool<sup>1</sup> but in the developing nations like Nigeria these imaging tools may not be accessible or affordable by the patient.

## II. Methodology

Archives of the UCTH Histopathology for the Alimentary canal lesions were extracted and appendectomy lesions sieved from them; this spanned the 11-year period from 1999- 2009. The information extracted included patients' Histology/lab numbers, age, sex, and histopathologic diagnosis. The data obtained were then analyzed by simple statistical method.

EXCLUSION CRITERIA: Patients with inadequate demographic information were excluded from the study.

## III. Result

A total of 712 gastrointestinal specimens were received in the reception of the pathology department of UCTH, Calabar during the study period, 329 of the specimens were appendectomy lesion. This makes appendectomy specimen the leading surgical material received with 46.2%. An average of 30 appendectomy specimens was received annually.

**Table 1** Annual Incidence of Appendectomy and gastrointestinal specimens

S/no	Year	Total no of Appendix specimen	Total no of Alimentary tract specimen.	Percentage %
1	1999	12	30	40
2	2000	28	56	50
3	2001	23	46	50
4	2002	10	40	25
5	2003	31	54	57.41
6	2004	23	58	39.66
7	2005	15	41	36.59
8	2006	34	63	53.97
9	2007	55	105	52.38
10	2008	49	100	49
11	2009	51	119	42.86
	<b>TOTAL</b>	<b>329</b>	<b>712</b>	

There was female preponderance in the appendectomy specimens with male to female ratio of 1:1.2. Acute appendicitis with or without complication is seen more among the male folds so also are chronic inflammatory lesions.

Four cases of schistosoma appendicitis were seen during the study period and these cases were only seen in male while eight cases of eosinophilic appendicitis were seen.

There was no case of malignancy or carcinoid tumour during the study period while 21 cases showed no pathology. Reactive lymphoid hyperplasia was seen in 138 cases which is about 42% of the total appendectomy lesions.

**Table 2 Pathological Changes in Appendectomy Specimens with gender distribution**

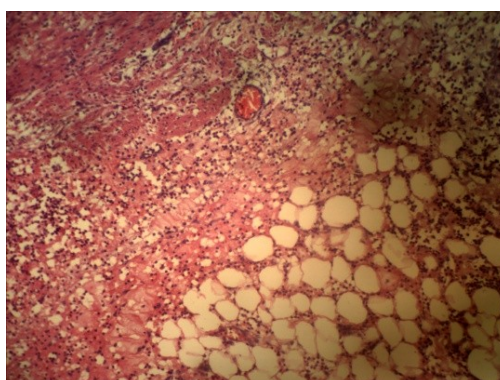
A) Inflammation	Male	Females	Total
1)Acute			
1.1 Acute appendicitis	69	46	115
1.2 Acute suppurative+peritonitis/gangrene	18	14	32
2)Chronic			
2.1 chronic non specific	5	3	8
2.2 parasitic	4	0	4
2.3Eosinophilic	3	5	8
3)Others			
3.1)Neoplasia	Nil	Nil	
3.2)Appendicial Carcinoid	Nil	Nil	
3.3)No pathological changes	4	17	21
3.4) Lymphoid Hyperplasia	45	93	138
3.5) autolysed specimen	1	2	3
<b>Total</b>	<b>149</b>	<b>180</b>	<b>329</b>

Acute appendicitis was seen more in their thirties while other lesions are seen at the lower age group. The average age of presentation for appendectomy in this study was about 28.5 years.

The 21-30 age group had the highest frequency followed by the 11-20 age group at 32.2% and 23.1% of the total number of specimens respectively. The 71-80 age group had the least frequency at 0.34%.

**Table 3: Average Age of Presentation**

Pathology	Sex	Average Age
Acute Inflammatory	Male	35
	Female	31
Chronic Inflammatory	Male	27
	Female	24
Others	Male	19
	Female	35



**Figure I:** Histologic section of acute suppurative appendicitis with peritonitis

Section shows a tissue with oedematous stroma, congested blood vessels and infiltration of acute inflammatory cells into the stroma. This is a section from ruptured appendix with infiltration of the inflammatory cells into the mesoappendix. The patient often present with fever, the organ is red, oedematous, and tender with loss of its function. Such conditions may be complicated with peritonitis and septicemia.

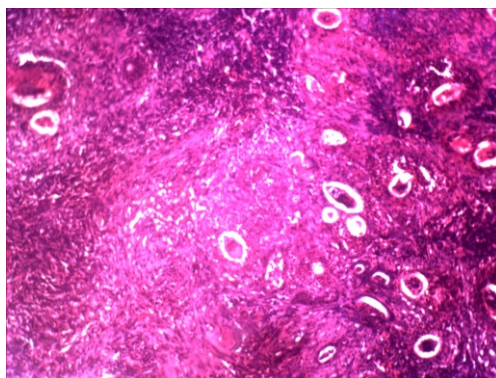


Figure II: Section of schistoma appendicitis

This is a section showing numerous ova of schistosoma haematobium with terminal spines. The ova are surrounded by chronic inflammatory cells mainly lymphocytes and eosinophils with fibrosis of the stroma.

#### IV. Discussion

Appendicitis is the commonest abdominal surgical emergency in the UK; the lifetime risk of appendicectomy in the US has been reported at 12.0% for males and 23.1% for females<sup>11</sup>. It is second most common cause of surgical emergency among pediatric patients in Calabar<sup>6</sup>. The exact aetiology is uncertain, although the most common hypothesis is of obstruction to the appendiceal lumen with secondary infection. The obstruction leads to the accumulation of mucosal secretions and multiplying resident bacteria, thus raising intra-luminal and intra-mural pressure. Eventually the pressure causes venous obstruction and thrombosis of the appendicular vasculature, resulting in ischaemia. Bacteria enter the damaged mucosa, and pus forms inside and around the appendix. Ultimately, infarction and perforation occur which can lead to peritonitis, septicemia and death. Some of the common causes of the obstruction are thought to be a faecolith, lymphoid hyperplasia and adhesions.

Appendicitis is a condition that has been seen to occur in different medical conditions such as pregnancy and has been seen to complicate ventriculoperitoneal shunt surgery for hydrocephalus due to an intracranial space occupying lesion<sup>4</sup>

In a study done among South African pupils and students aged 18-20 years, appendicectomy was very uncommon in rural Negroes (0.5%) and periurban Negroes (0.9%), slightly more common in urban Negroes (1.4%), but very common in Caucasians (16.5%); prevalences in Coloured and Indian groups were low (1.7 and 2.9%). Rural Negroes had a far larger fibre-intake, greater frequency of defecation, and much shorter transit-time; yet, in the four ethnic groups in urban areas, despite wide differences in appendicectomy-prevalence, data on these variables were similar<sup>12</sup>

A hospital based study in Kenya show male to female ratio was 1.8:1 which is in contrast to this study and the earlier study done in this centre which all have female preponderance. The median age was 29 (4-71 years). Median pre-hospital delays were one day (normal appendix), one and half days (simple appendicitis), three days (perforated appendix) and six and a half days (appendical abscess). Operative findings were 14% normal appendix, 42% simple appendicitis, 22% perforated, 21 % abscess<sup>3</sup>

In a prospective study done at Ibadan, Nigeria Ninety percent of the patients were between 11-40 years of age. Male patients accounted for 54% of the cases. Students and civil servants accounted for 68%, while artisans and traders accounted for remaining cases. Low abdominal pain was present in all cases, loss of appetite in 77.7%, and previous history of abdominal pain in 76%. Abdominal tenderness was present in all the patients, rebound tenderness in 77.7%, guarding in 81.5% and Rovsings sign in 50%. In 12 cases (22%) the diagnosis was incorrect 8 of which were female patients. In 9.3% there was perforation. Wound infection and wound dehiscence occurred in 20.4% and 7.4% of the cases respectively. It is concluded from this study that acute appendicitis is commonly encountered in private Hospital. Clinical course and postoperative outcome are not different from what obtains in government medical establishments<sup>4</sup>.

The previous study done in Calabar<sup>6</sup> had *Ascaris Lumbricoides* as the commonest cause of parasitic infection while this study revealed that *Schistosomiasis* is the commonest parasitic appendical inflammatory

lesion. Iribhogbe P et al<sup>13</sup> reported a case of diagnostic dilemma in a child with acute appendicitis secondary to *Ascaris lumbricoides* in Benin, Nigeria. He emphasized the need for high level of suspicion when dealing with patients of this age group because they may result in several complications.

The ova and cysts of certain parasites were detected and evaluated among patients with appendicitis in south-eastern part of Nigeria by Okolie BI et al<sup>14</sup>. ova of *Enterobius vermicularis*, *Trichuris trichuria*, *schistosoma heamatobium*, *s. mansoni* and *Ascaris lumbricoides* and cyst of *entamoeba histolytica* were seen with varied frequencies in the appendix.

## V. Conclusion

Appendectomy remains the commonest gastrointestinal specimen in Calabar. The procedure is commoner in female however; the incidence of acute appendicitis is commoner in male. Majority of the appendectomy specimens in female are reactive lymphoid hyperplasia while acute suppurative appendicitis with suppuration is commoner in male. This may be due to the fact that female visits the hospital more than the male; they often have a lower pain threshold and are easily convince for any surgical intervention. Chronic appendicitis secondary to parasitic infection mainly schistosomiasis is a common occurrence among the populace.

## References

- [1]. Haye's R. Abdominal pain: general imaging strategies. *European Radiology, supplement* 2004; 14: 123-137.
- [2]. Elechi EN. Acute Appendicitis: A Clinical Pattern In Port Harcourt Nigeria *East Afr Med J*. 1989; 66(5):328-32
- [3]. W S Willmore, AG. Hill, acute appendicitis in a kenyan rural hospital *The East African Medical Journal* 2001, 78 (7)
- [4]. Mwang'ombe NJM, Acute appendicitis following ventriculoperitoneal shunt surgery for hydrocephalus due to an intracranial space occupying lesion *AJNS* 1999 18,(1)
- [5]. Adesunkanmi AR, Acute appendicitis: a prospective study of 54 cases. *West Afr J Med*. 1993 Oct-Dec;12(4):197-200,
- [6]. A E Archibong, I Ekanem, P Jibrin Appendicitis in south eastern Nigerian children. *Cent Afr J Med*. 1995 Mar ;41 (3):94-7
- [7]. Hernandez JA, Swischuk LE, Angel CA et al. imaging of acute appendicitis: US as the primary imaging modality. *Pediatric Radiology* 2005; 35:392-395
- [8]. Rosendahl K, Aukland SM, Fosse K. Imaging strategies in children with suspected appendicitis. *European Radiology, Supplement* 2004; 14: 138-145.
- [9]. Tauro LF, Premanand TS, Aithala PS, George C, Suresh HB et al Ultrasonography is still a useful diagnostic tool in acute appendicitis, *Journal of Clinical and diagnostic research* 2009; 3;5: 1731-1736
- [10]. Vegar-Zubovic S, Lincender L, Dizdarevics et al. Ultrasound signs of acute appendicitis in children – clinical application. *Radiology and oncology* 2005; 39: 15-21 + 82
- [11]. Addiss DG, Shaffer N, Fowler BS, Tauxe RV. The epidemiology of appendicitis and appendicectomy in the United States. *Am J Epidem*. 1990;132:910-925
- [12]. Alexander R. P. Walker, Barbara D. Richardson, B. Faith Walker, Atholie Woolford *Postgrad Med J* 1973;49:243-249
- [13]. Iribhogbe P., Omorogiwa I. Acute Appendicitis In Young Children-A Diagnostic Challenge *JMBR: A Peer-review Journal of Biomedical Sciences* 2006; 5 (2)40-43
- [14]. B.I. Okolie, I.O. Okonko, A.A. Ogun, A.O. Adedeji, et al Incidence and Detection of Parasite Ova in Appendix from Patients with Appendicitis in South-eastern, Nigeria *World Journal of Agricultural Sciences* 2008; 4: 795-802