

Petrochanteric Femur Fractures Treated With Recon Nail – A Prospective Study of 20 Cases

Dr. Manukonda. Kishore Kumar M. S. (Ortho), Dnb (Ortho)

I. Introduction

Petrochanteric fractures are common in old age group but it is not uncommon in younger age group. These fractures unite readily with conservative line of treatment and there is no fear of complications like avascular necrosis of head and its sequel of osteoarthritis . In trochanteric fractures treated without surgical interventions malunion and coxa vara resulting in shortening of limb and limp.

The primary goal of the treatment has to be early mobilization to avoid secondary complications. Petrochanteric femur fractures may be repaired with either a sliding hip screw or a recon nail. The hip screw has been considered the device of choice because fracture union predictably occurs. A problem with sliding hip screws is collapse of the femoral neck leading to loss of hip offset and shortening of the leg. Therefore a new intramedullary device-Recon nail was designed in the early 1980s which gives an advantage of minimally invasive surgery avoiding Complications of sliding Hip Screw.

Aims & Objectives

Aim: To study and evaluate the results of Fixation of petrochantric fracture of femur with reconstruction femoral nail.

Objectives:

- To study the period of union and union rate on radiological evidence.
- To Study the range of movements at hip and knee joint.
- To Study the complications in fixation of petrochantric fracture of femur with reconstruction femoral nail.

II. Material And Methods

The material for the present study was obtained from the patients admitted in government general hospital Vijayawada. A minimum of 20 cases were taken and the patients were informed about the study in all aspects and informed consent was obtained from each patient.

Method Of Collection Of Data

- By interview.
- By follow up at intervals of 1, 2 and 4 months.
- By clinical examination.
- By analyzing case papers.
- Following inclusion and exclusion criteria were used.

Inclusion criteria:

1. Patient who has been diagnosed as having closed petrochanteric fractures.
2. Patients of 20-75 years of age.
3. Patient who are fit for surgery.

Exclusion criteria

1. Skeletally immature individuals.
2. Patients unfit for the surgery .
3. Patients with compound fractures.
4. Patients with pathological fractures.
5. Patients admitted for reoperation.
6. Patient not given written consent for surgery.

Patients admitted with petrochanteric fracture were examined and investigated with X-ray pelvis with both hips AP and Lateral view. Preoperative Profile was done for all cases.

All fractures were treated using a recon nail. All patients were assessed by using the Kyle's criteria at the follow-ups. Data collected at the end of the study was statistically compared and analyzed with the similar studies done before.

Implant Design: Main implant used in the treatment of petrochanteric fractures in this study is Recon nail (intramedullary device)

The dimensions of the recon nail are:

Diameter: Proximal :13 -15mm.

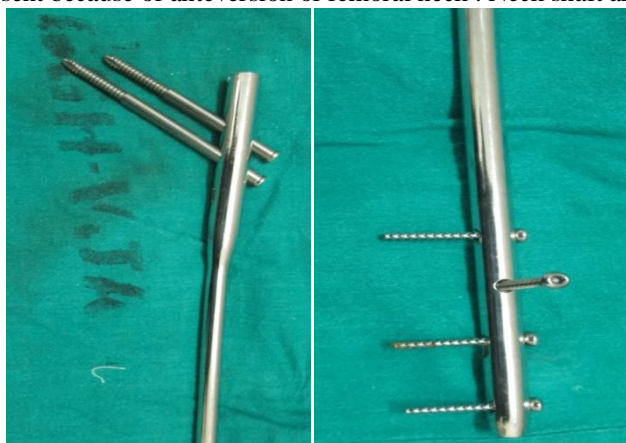
Anteversion of proximal screws : 8 degrees.

Length: 360-480 mm.

Proximal Screw diameter: 6.5mm.

Distal Screw diameter : 4.5 mm fully threaded cortical screws.

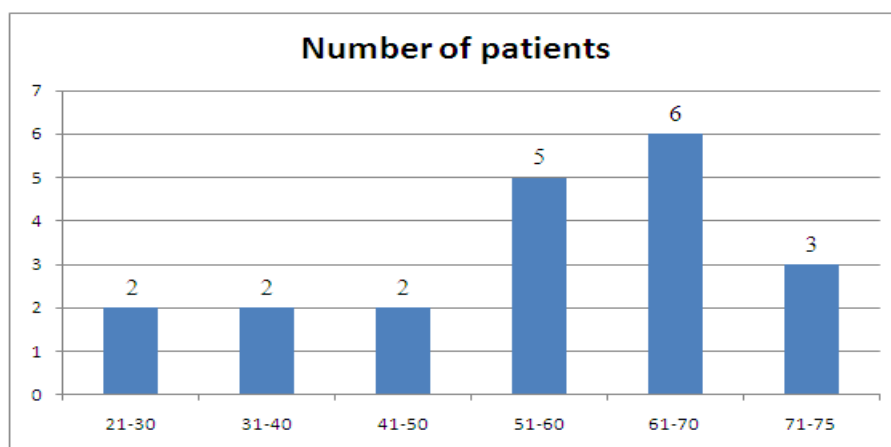
Right and left nails are present because of anteversion of femoral neck . Neck shaft angle is 130° & 135°.



III. Results And Observation

The study involved 20 confirmed cases of Petrochanteric fractures of either sex . All the cases were treated with intramedullary fixation "Recon nail". The analysis of the patient data & post operative outcome is as follows.

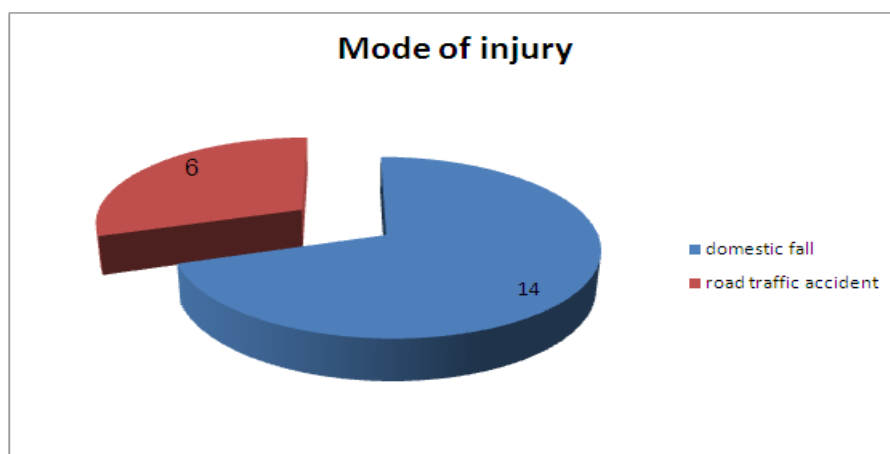
Age: The age distribution was from 20 to 75 years. The average age was 55 years. The largest group of patients being from 61-70 years.



Sex: There were 6 females and 14 males in the study.

Mode Of Injury

Domestic fall and road traffic accident were the mode of injury in all the patients. Most of the patients with domestic fall were older in age or had osteoporosis.



Fracture Patterns: All the fractures were classified as per Orthopaedic Trauma Association (OTA) classification. In which 31A1 were considered stable fractures. 31A2 and 31A3 were unstable fractures. Stable fractures were 6 and Unstable 14.

Operating Time: Average operating time was 40 min after anesthesia.

Reduction: Fracture was reduced anatomically by closed means. If that was not achieved then it was achieved by limited open reduction during surgery. Near anatomical reduction was achieved in 16 cases by closed nailing method and 4 cases through limited open reduction.

Complications

1. **Implant Failure:** There is one case of implant failure in all cases of my study.
2. **Non-Union:** There is one case of non-union in my study.
3. **Infection:** There is one case of infection seen in the study. The infection is superficial and treated with antibiotics.

Hospital Stay: The average hospital stay was 10 days from date of admission to date of discharge.

Criteria For Evaluation And Results (KYLE'S Criteria)⁵²: All the patients after fracture union were grouped and the anatomical and functional results evaluated as follows.

1. Excellent

- a. Fracture united.
- b. No pain.
- c. No infection.
- d. Full range of motion at hip.
- e. No shortening.
- f. Patient able crossed legged and squat.
- g. Independent gait.

2. Good

- a. Fracture united.
- b. Occasional pain.
- c. No infection.
- d. Terminal restriction of hip movements.
- e. Shortening by half an inch.
- f. Patient able to sit crossed and squat.
- g. Use of cane back to full normal activity.

3. Fair

- a. Fracture united.
- b. Moderate hip pain.
- c. No infection.

- b. Flexion restricted beyond eighty degrees.
- c. Noticeable limb shortening up to one inch.
- d. Patient walks with support of walker.
- e. Back to normal activities with minimal adjustments.

4. Poor.

- a. Fractures not united.
- b. Pain even with slightest movement at hip or rest.
- c. Infection.
- d. Range of movements at hip restricted, Flexion restricted beyond sixty degrees.
- c. Shortening more than one inch.
- d. Patient cannot walk without walking aid.
- e. Normal activities not resumed.

Results According To Kyle’s Criteria

Excellent 75%
 Good 10%
 Fair 5%
 Poor 10%

IV. Discussion

The successful treatment of petrochanteric fractures depends on many factors like⁴³:

- Age of the patient.
- Pts general health.
- Time from fracture to treatment.
- The adequacy of treatment.
- Concurrent medical illness.
- Stability of the fixation.

According to Bronx Hip fracture epidemiological trends, outcomes⁽⁶⁾ : In patients with hip fractures, male gender, advancing age, high number of comorbidities, conservative treatment and the surgical delay of 5 days or more were associated with higher rates of in hospital mortality.

Wickham et al⁸⁷ ⁽⁶⁾15 year follow-up study of 1688 community dwelling subjects Physical activity participation protected against hip fracture

Hoidrup et al⁹⁹⁽⁶⁾ Prospective study of leisure-time physical activity levels and changes in relation to risk of hip fracture among 1,211 men and women with first hip fractures Moderate levels of physical activity appear to protect against later hip fracture Declining physical activity over time is an important risk factor for hip fracture

Seif-asaad et al⁽²⁰⁾ reported good results in 40 patients using the recon nail for unstable per trochanteric fractures 38 patients healed with out deformity , with one case of shortening, and one case of varus collapse.

	Seif assad et al	Present study
No of Patient	40	20
Mean time of surgery	58min	40min
Post operative pain	Occasionally / no	Occasionally
External Rotational deformity (>15°)	None	None
Shortening (2cm)of limb	1	None
Non Union	None	1
Varus Collapse	1	None
Shaft fracture	None	None
Range of motion	All gained full range	All gained normal range

Krastman et al., in more complex group with both pathological and multiple trauma cases, 89% union rate with recon nail and in two cases screw penetration in to femoral head.

Ulfin Rethnam*1,3, James Cordell-Smith2, Thirumoolanathan M Kumar1 and Amit Sinha1- a study on Complex proximal femoral fractures in the elderly managed by reconstruction nailing – complications & outcomes: a retrospective analysis⁽¹³⁾

Retrospective evaluation of 42 patients aged over 60 years who were treated by reconstruction nailing for proximal femoral fractures over a 4 year period. Favourable fixation of unstable complex femoral fractures in

the elderly population can be achieved with the Russell-Taylor reconstruction nail. However, use of this device in this frail population was associated with a high implant complication and mortality rate that undoubtedly reflected the severity of the injury sustained, co-morbidity within the group and the stress of a major surgical procedure.

	Ulfin Rethnam	Present study
patients	42	20
Mean surgery time	131.6 min	40 min
Post operative complications	18	3
Wound infection	3	1
Need of surgical debridement	2	1
need of additional surgery	7	none
Implant failure	1	1

Hoover GK, Browner BD, Cole JD, Comstock CP, Cotler HB.⁽²⁾

A series of 5 patients with petrochanteric fractures underwent closed intramedullary nailing with the Russell-Taylor reconstruction (RECON) nail. This study demonstrates that second generation locking nails, such as the RECON nail, offer the added strength and design features necessary for more effective treatment of complex proximal and ipsilateral femoral neck/shaft fractures. Union was achieved in all acute fractures. Excellent hip and knee range of motion were obtained

	. Hoover GK	Present study
patients	5	20
union	Union in all cases	19
Hip and knee range of motion	excellent	excellent

The success of recon nail depended on good surgical technique, proper instrumentation and good C- arm visualization. All the patients were operated on fracture table. We found following advantages.

- Reduction with traction is easier.
- Less assistance is required.
- Manipulation of the patient is reduced to minimum.
- Trauma to patient is decreased.
- Better use of C- arm with better visibility.

Placement of the patient on the fracture table is important for better access to the greater trochanter. The upper body is abducted away 10-15⁰ . and internally rotate the limb in traction table Position of the C- arm should be such that proximal femur is seen properly in AP and lateral view.

The anatomical reduction and secure fixation of the patient on the operating table are absolutely vital for easy handling and good surgical result. If reduction was not achieved by traction and manipulation then nail reduction was done, in which nail was introduced in the proximal fragment and reduction was tried by rotational movements and compression by the nail. If still reduction was a problem, then it was achieved by limited open reduction at the fracture site.

The entry point of the recon nail was taken in trochantric fossa. The lower lag screw pins is inserted 5mm away from the subchondral bone in the lower half in the AP view and center on the neck in the lateral view. The superior lag screw pin is placed parallel to the lower pin in AP view and overlapping it in the lateral view. It should be 5mm shorter than the lower pin from the subchondral bone.

Screw will not take the weight load but only fulfill the anti-rotational function. Failure to do this leads to the “Z- effect” in which the inferior lag screw backs out and the superior lag screw pierces the joint or the vice-versa. The Z-effect phenomenon is a potential complication of two lag screw intramedullary nail designs used for fixation of petrochanteric hip fractures in which the inferior lag screw migrates laterally and the superior lag screw migrates medially during physiologic loading.

Petrochanteric Fractures: Ten Tips to Improve Results By George J. Haidukewych, MD¹⁴

- Explains ten tips for easy application of recon nail.
- **Tip 1:** Use the Tip-to-Apex Distance.
- **Tip 2:** “No Lateral Wall, No Hip Screw.
- **Tip 3:** Know the Unstable petrochanteric Fracture Patterns and Nail Then.
- **Tip 4:** Beware of the Anterior Bow of the Femoral Shaft.
- **Tip 5:** When Using a Trochanteric Entry Nail, Start in the pyriform fossa.
- **Tip 6:** Do Not Ream an Unreduced Fracture.

- **Tip 7:** Be Cautious About the Nail Insertion Trajectory, and Do Not Use a Hammer to Seat the Nail.
- **Tip 8:** Avoid Varus Angulation of the Proximal Fragment. Use the Relationship Between the Tip of the Trochanter and the Center of the Femoral Head.
- **Tip 9:** When Nailing, Lock the Nail Distally if the Fracture Is Axially or Rotationally Unstable.
- **Tip 10:** Avoid Fracture Distraction When Nailing.

V. Conclusion

Literature suggests that Dynamic hip screw is the Gold standard for treatment of stable type of per trochanteric fractures as well as unstable types.

According to our study and use of recon nail in petrochanteric fractures fixation ,it is also be a good modality of treating patients with minimal invasion ,less blood loss ,good anatomical fixation even in unstable paterens of fracture ,minimal morbidity to patients ,less chances of complications ,early weight bearing ,and great reduction in view of abstinence from work.

Recon Nail Can Be Considered The Most Judicious And Rational Method Of Treating Petrochanteric Fracturs,Especially The Stable And Unstable Type.

The reasons to support this are:

- It can be used in all configurations of proximal femoral fractures.
- It is a closed method thus preserves the fractures hematoma and yields early healing and early union.
- It can be used with equally good results in all grades of osteoporosis.
- It is a quick procedure with a small incision and with significantly less amount of blood loss.
- It gives good results even with non-anatomical reduction.
- Two proximal lag screws placement is important. They have to be parallel in AP and overlapping in lateral. And cervical screw 5mm shorter than hip screw to avoid the “Z- effect”.
- Nail entry is in the trochanteric fossa, probably may not damage hip abductors.
- Complications were minimal and comparable with other fracture systems.

But recon nailing requires a higher surgical skill, good fracture table, good instrumentation and good C- arm control. It has a steep learning curve.

Thus we can conclude that the recon nail is after proper training and technique a safe and easy implant option for treatment of complex petrochanteric fractures.

References

- [1]. Parker MJ, Handoll HH: Gamma and other cephalocondylic intramedullary nails versus extramedullary implants for extracapsular hip fractures in adults. *Cochrane Database Syst Rev* 2005, 19(4):CD000093.
- [2]. Schipper IB, Marti RK, Van der Werken C: Unstable trochanteric femoral fractures: extramedullary or intramedullary fixation. *Review of Literature. Injury* 2004, 35(2):142-151.
- [3]. Stromsoe K: Fracture fixation problems in osteoporosis. *Injury* 2004, 35(2):107-113. Gibbons CL, Gregg-Smith SJ, Carrell TWG, et al.: Use of the Russell-Taylor reconstruction nail in femoral shaft fractures. *Injury* 1995, 26(6):389-392.
- [4]. Kang S, McAndrew MP, Johnson K: The Reconstruction Locked Nail for complex fractures of the proximal femur. *J Orthop Trauma* 1995, 9(6):453-463.
- [5]. Garnavos C, Peterman A, Howard P: The treatment of difficult proximal femoral fractures with the Russell-Taylor reconstruction nail. *Injury* 1999, 30(6):407-415.
- [6]. Zuckerman JD: Hip fracture. *N Engl J Med* 1996, 6;334(23):1519-25.
- [7]. Adams CI, Robinson CM, Court-Brown CM, McQueen MM: Prospective randomized controlled trial of an intramedullary nail versus dynamic screw and plate for intertrochanteric fractures of the femur. *J Orthop Trauma* 2001, 15(6):394-400.
- [8]. Valverde JA, Alonso MG, Porro JG, Rueda D, Larrauri PM, Soler JJ: Use of the Gamma nail in the treatment of fractures of the proximal femur. *Clin Orthop Relat Res* 1998, (350):56-61.
- [9]. Fogagnolo F, Kfuri M Jr, Paccola CA: Intramedullary fixation of petrochanteric hip fractures with the short AO-ASIF proximal femoral nail. *Arch Orthop Trauma Surg* 2004, 124(1):31-7.
- [10]. Tyllianakis M, Panagopoulos A, Papadopoulos A, Papisimos S, Mousafiris K: Treatment of extracapsular hip fractures with the proximal femoral nail (PFN): long term results in 45 patients. *Acta Orthop Belg* 2004, 70(5):444-54.
- [11]. Parker MJ, Handoll HH: Intramedullary nails for extracapsular hip fractures in adults. *Cochrane Database Syst Rev* 2006, 19(3):CD004961.
- [12]. Sadowski C, Lübbecke A, Saudan M, Riand N, Stern R, Hoffmeyer P: Treatment of reverse oblique and transverse intertrochanteric fractures with use of an intramedullary nail or a 95 degrees screw-plate: a prospective, randomized study. *J Bone Joint Surg Am* 2002, 84-A(3):372-81.
- [13]. Papisimos S, Koutsojannis CM, Panagopoulos A, Megas P, Lambiris E: A randomised comparison of AMBI, TGN and PFN for treatment of unstable trochanteric fractures. *Arch Orthop Trauma Surg* 2005, 125(7):462-8.
- [14]. Boldin C, Seibert FJ, Fankhauser F, Peicha G, Grechenig W, Szyszkowitz R: The proximal femoral nail (PFN) – a minimal invasive treatment of unstable proximal femoral fractures: a prospective study of 55 patients with a follow-up of 15 months. *Acta Orthop Scand* 2003, 74(1):53-8.
- [15]. Tan HB, MacDonald DA, Mathews SJ, et al.: Incidence and causes of mortality following acute orthopaedic and trauma admissions. *Ann R Coll Surg Engl* 2004, 86(3):156-160.