

A study of clinical, ultrasonographic and intra-operative findings in acute cholecystitis

Dr. Sudershan Kapoor¹, Dr. Ashwani Kumar², Dr. Bal Jaskaran Singh³

¹ Professor and Head, Department of Surgery, Govt. Medical College, Amritsar.

² Associate Professor, Department of Surgery, Govt. Medical College, Amritsar.

³ Junior Resident, Department of Surgery, Govt. Medical College, Amritsar.

Corresponding Author: Dr. Ashwani Kumar Associate Professor, Department of Surgery, GMC Amritsar.

Abstract: 90-95% of cases of acute cholecystitis are caused due to gall stones, i.e. calculous cholecystitis. Rest of the 5-10% cases are caused without the presence of stones, i.e. acalculous cholecystitis. Diagnosis of acute cholecystitis involves clinical, laboratory, and radiographic findings. The present study was conducted in the Department of Surgery, Govt. Medical College, Amritsar. A sample size of 50 patients was taken who were diagnosed as cases of acute cholecystitis either clinically or radiologically referred to the department. The aim of the study is to evaluate the accuracy of clinical, ultrasonographic and intra-operative findings in acute cholecystitis. The mean age of presentation was 54.94 years. It was more common in females than males and more common among married females. Abdominal pain was the most common clinical feature present in 90% patients. Vomiting was another common feature present in 80% patients. On USG abdomen, 92% cases had calculous cholecystitis and 8% had acalculous cholecystitis. Intraoperatively, most common finding was adhesions. It was present in 40 patients (95.24%) and increased wall thickness was present in 37 cases (88.09%). It was concluded that the number of patients presenting with acute cholecystitis is increasing because of the increased awareness. With improved healthcare facilities and newer techniques, complications have declined substantially with reduced mortality and morbidity.

Keywords - Gall Bladder, Acute cholecystitis, Acalculous cholecystitis, USG.

Date of Submission: 25-11-2018

Date of acceptance: 07-12-2018

I. Introduction

Acute cholecystitis is the inflammation of the gall bladder, which is frequently encountered by surgeons in the emergency setting. In acute calculous cholecystitis there is blockage of bile flow and the gall bladder becomes enlarged, red and tense.¹

Acalculous cholecystitis is typically seen in hospitalised and critically ill patients, immune-compromised, patients receiving chemotherapy, TPN, patients of major trauma and burns.² Gall stones are present in 10-15% of adults in developed countries.³ According to Indian Journal of Community Medicine (2011), 24% of people suffering from gall stone disease have acute cholecystitis in India. More commonly stones are present in women than men. Obesity, diabetes, pregnancy, birth control pills, liver disease, or rapid weight loss are the major risk factors for gall stone formation.⁴ Acute cholecystitis is suspected on the basis of symptoms and signs of inflammation in patients with peritonitis localised to the right upper quadrant. In addition to history, physical examination, laboratory tests and radiological imaging is required to confirm the diagnosis of acute cholecystitis. Complete blood count, C-reactive protein (CRP) and liver function tests (bilirubin and aminotransferases), are the common blood investigations required. The advent of and subsequent improvement in various imaging modalities has aided in the evaluation and diagnosis of acute cholecystitis. Plain abdominal radiographs are not of much usefulness in calculous cholecystitis because more than 90% of gall stones are radiolucent. So, X-rays show radio-opaque gall stones in only about 10% of cases of acute cholecystitis. In emphysematous cholecystitis, gas within the gallbladder wall can be visualised on X-rays.

Ultrasonography (USG) and Computed Tomography (CT) are now commonly available and used. Hepatobiliary scintigraphy (Hepatic iminodiacetic acid-HIDA scan) and Magnetic Resonance Imaging (MRI) are also used in selected patients (where USG and CT cannot confirm the diagnosis) and may provide additional functional information of the biliary tract.

Ultrasound scanning is the investigation of choice. Sonograms typically show pericholecystic fluid (fluid around the gall bladder), distended gall bladder (long axis ≥ 8 cm, short axis ≥ 4 cm), oedematous and thickened gall bladder wall (over 3.5mm), gall stones, and dilatation of bile duct. Murphy's sign can be elicited on ultrasound examination.⁵

The treatment of choice in acute cholecystitis is surgical removal of gall bladder, i.e Cholecystectomy.⁶ It can be either Open or Laparoscopic. Early cholecystectomy is done within 7 days of onset of symptoms. Delayed cholecystectomy is done after 6 weeks of onset of symptoms. In recent years, several studies aimed to determine the optimal timing of surgery for acute cholecystitis, showing a clear benefit in performing early rather than delayed cholecystectomy.⁷

II. Aims and Objectives

To evaluate the accuracy of clinical findings, radiological findings and Intra-operative findings of Acute Cholecystitis.

III. Material and Methods

This study was done on 50 cases of Acute cholecystitis diagnosed clinically or radiologically admitted or referred to surgery department of Govt. Medical college / Guru Nanak Dev Hospital, Amritsar.

The patients were assessed clinically at presentation. A note of all the details such as age, sex, marital status, date of onset of symptoms, date of admission and date of operation were made. Detailed history and clinical examination were done. Patient was subjected to radiological investigations in the form of ultrasound abdomen and the findings were noted. All patients who underwent surgery were evaluated. All the intraoperative findings were recorded. Study of clinical, radiological and intra-operative findings suggesting acute cholecystitis was done. Early cholecystectomy was preferred over delayed cholecystectomy. Early cholecystectomy was done in 44(88%) cases and delayed cholecystectomy was done in only 6(12%) cases.

3.1 Inclusion criteria:

All cases of Acute cholecystitis who gave informed consent were considered for study irrespective of age and sex.

3.2 Exclusion criteria:

1. Cases of Acute cholecystitis along with cirrhosis and portal hypertension were not considered for the study.
2. Cases of Acute cholecystitis along with stones in the common bile duct were not considered for the study.

IV. Observations

4.1 Age wise distribution of acute cholecystitis

Age in Years	No. of Patients	Percentage
< 30	5	10
30 - 39	5	10
40 - 49	7	14
50 - 59	17	34
60 - 69	14	28
> 70	2	4
Total	50	100

TABLE No. 1 - Showing Age wise distribution of the patients

In this study of 50 cases, it was noted that the majority of the patients belonged to the age group of 50-69 years (62%), the highest incidence of acute cholecystitis in our study was found in the sixth decade (34%). 14(28%) patients presented in the age group of 60-69 years, 7(14%) patients were in the age group of 40-49, 5 (10%) patients were in age group of 30-39 years, 5 (10%) patients were less than 30 years of age, and 2 (4%) patients were above 70 years. The mean age of presentation was 54.94 years.

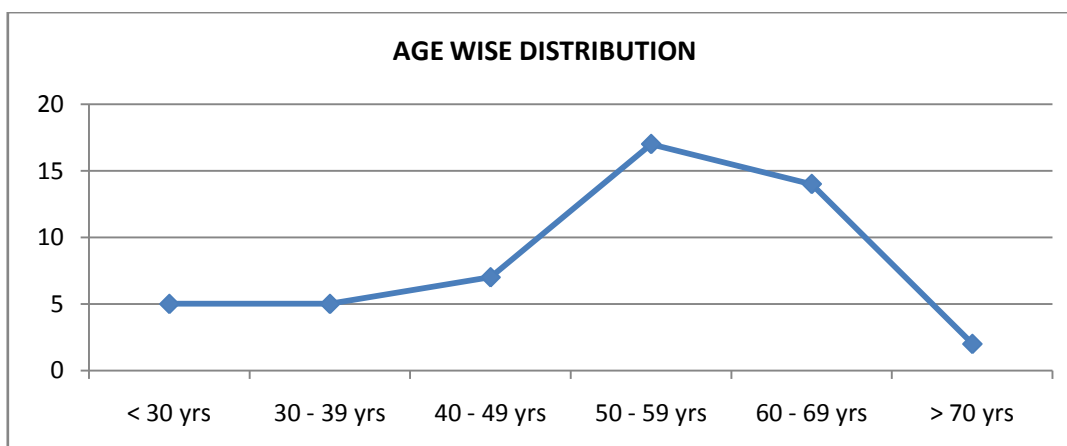


CHART No. 1 Showing Age wise incidence of Acute Cholecystitis

4.2 Sex wise Distribution of Acute Cholecystitis

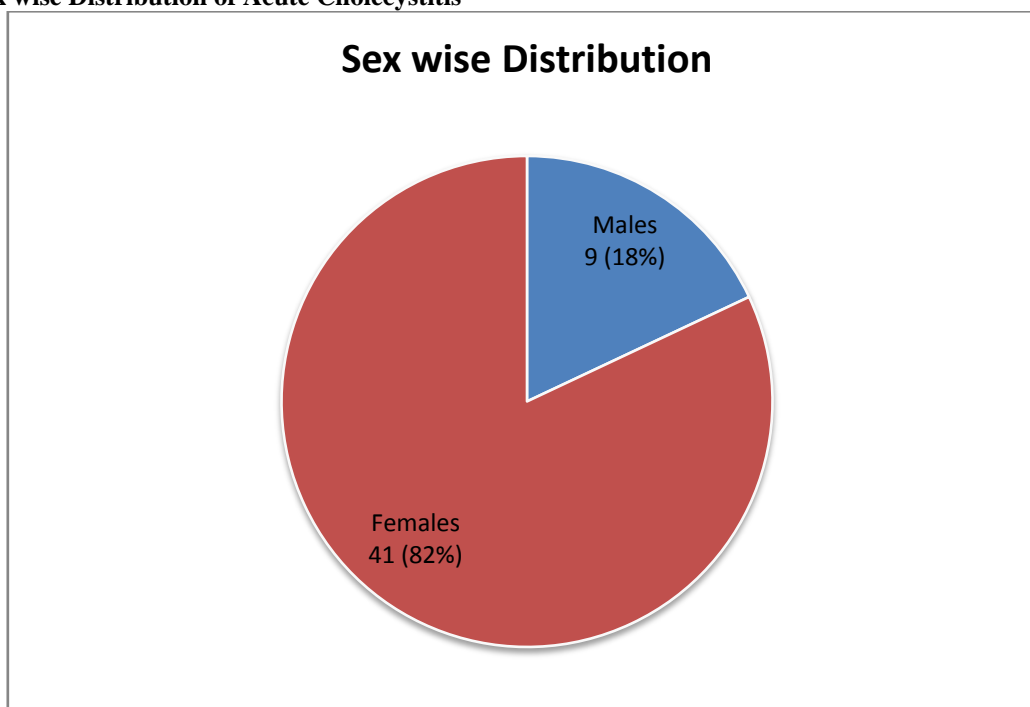


CHART No. 2 - Showing Sex wise incidence of Acute Cholecystitis

As shown in CHART No. 2 it is evident that out of 50 patients 41(82%) patients were females and 9(18%) patients were males. Female to male ratio in our study was 4.6:1 .

4.3 Marital Status of patients of Acute Cholecystitis

Marital Status of Patients	No. of Patients		
	Males	Females	Total
Married	7	39	46(92%)
Unmarried	2	2	4(8%)
	9	41	50(100%)

TABLE No. 2 - Showing Marital Status of patients suffering from Acute Cholecystitis

Upon observation of TABLE No. 2 showing marital status of patients suffering from Acute Cholecystitis it is noted that 92 % of patients suffering from acute cholecystitis were married and 8% were unmarried. Out of 46 married patients 39(85%) were females and 7 (15%) were males whereas among unmarried patients out of 4 patients 2(50%) were males and 2(50%) were females.

4.4 Clinical Features

Clinical presentation of acute cholecystitis varies from individual to individual. In our study 5 patients did not have any clinical symptoms of acute cholecystitis. They had undergone routine ultrasonography before presentation to the hospital. As shown in CHART No. 3, abdominal pain was the most common clinical feature in this study with which 90% of the patients presented. 32(64%) patients suffered from fever and in 40(80%) patients vomiting was present. Positive Murphy’s sign on palpation was present in 32(64%) patients in our study. Palpable lump on examination was found in 16(32%) patients in our study.

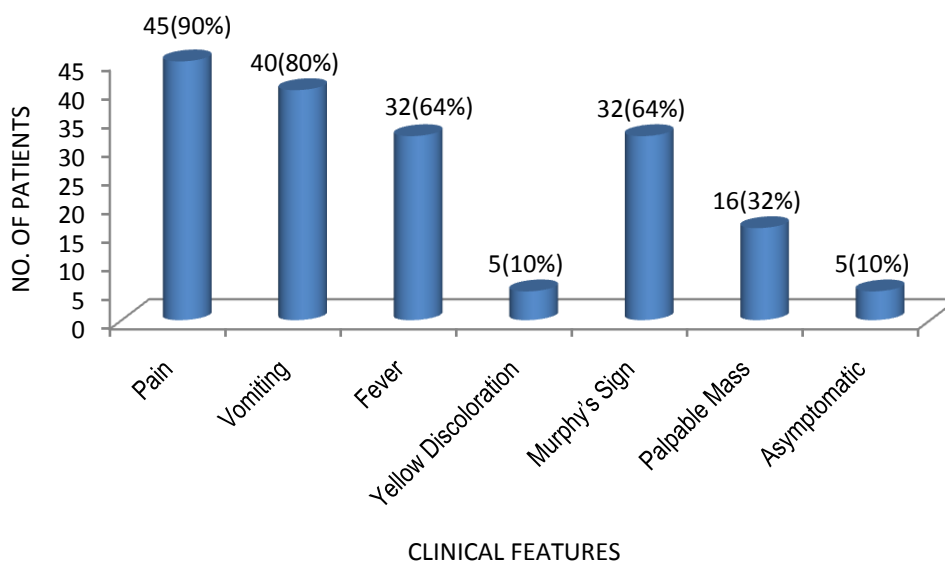


CHART No. 3 - Showing Clinical Features

4.5 Ultrasonographic Findings

As observed from CHART No. 4, all the 50 (100%) patients underwent Ultrasonography as the initial radiological investigation. In this study, on Ultrasonography, 46(92%) patients had calculous cholecystitis and 4 (8%) patients had acalculous cholecystitis. Increased gall bladder wall thickness was found in 27(54%) cases of acute cholecystitis.

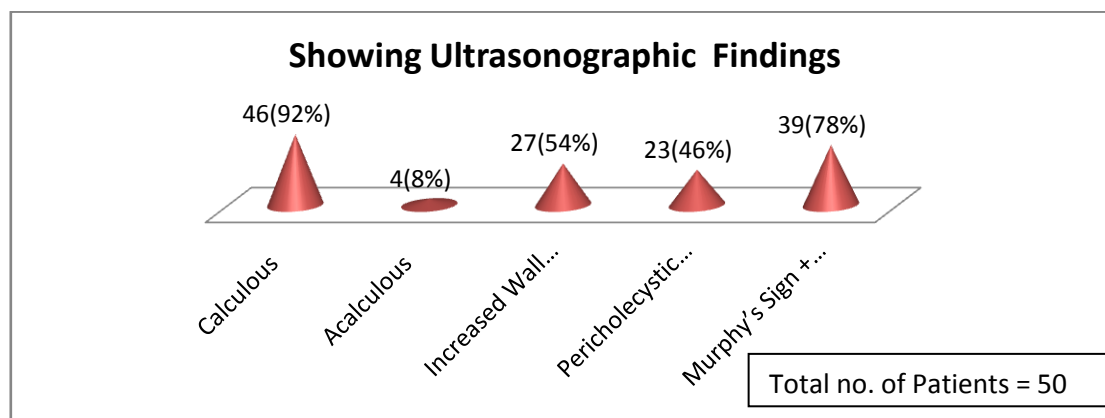


CHART No. 4 - Showing Ultrasonographic Findings

Pericholecystic fluid collection was present in 23(46%) patients. Ultrasonographic murphy's sign was positive in 39(78%) cases in the present study.

4.6 Intra-operative Findings

As shown in CHART No. 5 adhesions were the most common intra-operative finding in the present study.. Adhesions were present in 40(95.24%) cases. The gall bladder wall thickness was increased in 37(88.09%) cases. Pericholecystic fluid collection was present intra-operatively in 20(47.62%) cases of acute cholecystitis in our study.

In our study, 10(23.81%) cases of empyema of gallbladder were encountered which appeared as reddish, oedematous and moderately distended organ containing stones and pus. In 3(7.14%) cases, gangrenous cholecystitis was present in this study group as gall bladder appeared dark green-black in colour. Fistulous connection with gut (duodenum and transverse colon) was present in 2(4.76%) cases.

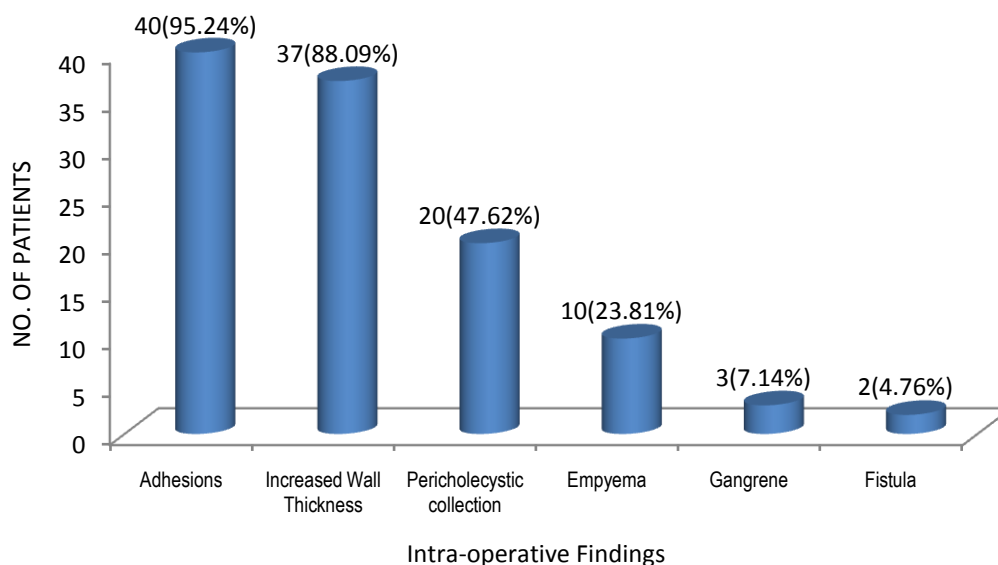


CHART No. 5 - Showing Intra-operative Findings

IV. Discussion

The majority of cases of acute cholecystitis presented in the age group of 50-59 years(34%). Our results are similar with the study done by Kimura, Yasutoshi et al (2016) which reported the frequency of acute cholecystitis is highest in people age 50–69 years old.⁸ Mean age of presentation in our study was 54.94 years (TABLE I). It is similar to the study done by Hwang H. et al in 2014 that also showed the mean age for acute cholecystitis to be 55.5 years.⁹ It was seen that acute cholecystitis was largely more common in females (82%) than in males (18%), female to male ratio being 4.6:1(TABLE No. 1). In study conducted by Rajkishore Singh et al in 2016, the female to male ratio was found to be 4.5:1.¹⁰ In the present study, 92% of the patients were married and the remaining 8% were unmarried persons (TABLE 2). A study by Rains AJH and Ritchie HD back in 1978 suggests that the high incidence among these multiparous women may be due to gall bladder relaxation and dilatation, which may progressively increase with each pregnancy, resulting in increased gall bladder volume and emptying.¹¹ In unmarried population the incidence in males and females was equal.

In this study 45(90%) patients had clinical features suggestive of acute cholecystitis, 44(88%) patients were diagnosed as acute cholecystitis radiologically (on Ultrasonography/CT scan/HIDA) and 42(84%) patients were confirmed as acute cholecystitis intraoperatively.

Abdominal pain was the most common clinical feature present in 90% patients. Mima Maychet B. Sangma and Fremington Marak (2016) in their study also had pain as the most common presenting feature. It was present in 100% .¹²

Vomiting was another common feature present in 80% patients. Friedman L.S. et al in 2015 found out in their study that 75% of the patients of acute cholecystitis suffer from vomiting of their cases.¹³

64% cases had fever and a positive Murphy's sign on palpation. Yellowish discoloration of skin was in 10% cases and in 32% cases a palpable gall bladder mass was felt. This finding is in relation to the findings in study by Alan A Bloom (2017) who stated that palpable gallbladder is present in 30-40% of cases of acute cholecystitis.¹⁴

The sensitivity and specificity of Murphy's sign was 69.05% and 62.5% respectively. Ultrasonography is the primary imaging modality for assessment of acute cholecystitis. It is an accurate, safe, relatively inexpensive, and readily accessible imaging modality. All the 50 patients underwent ultrasonography (USG) abdomen. On USG abdomen, 92% cases had calculous cholecystitis and 8% had acalculous cholecystitis. Our findings correlate with study performed by Mima Maychet B. Sangma and Fremington Marak (2016) who concluded that 94% of the cases were acute calculous cholecystitis and 6% of the case were acute acalculous cholecystitis.¹²

54% patients had increased gall bladder wall thickness, 46% had pericholecystic collection and 78% cases had positive Murphy's sign, suggestive of acute cholecystitis. Alper Bilal Özkardeş et al (2014) in their study found that 74% of the cases of acute cholecystitis had increased wall thickness.¹⁵

Our finding is comparable to the finding in study done by Alper Bilal Özkardeş et al (2014) in which pericholecystic fluid collection was present in 48% of the patients on ultrasonography.¹⁵ Our finding is in

correlation with Hwang H. et al, who in their study in 2014 found out that this sign was positive in 63.5% of their cases.⁹

Open cholecystectomy was done in 78% of the cases and Laparoscopic cholecystectomy was done in 22% cases. Conversion to open surgery was done in only 1 case (9.09%). Among 42 patients diagnosed as acute cholecystitis, most common finding was adhesions. It was present in 40 patients (95.24%). David F. et al (2012) in their study found that adhesions were most common intra-operative finding in acute cholecystitis and were present in 92.6% of the cases.¹⁶ So our results are in correlation with this study.

Increased wall thickness was present in 37 cases (88.09%). In 20 patients (47.62%) pericholecystic collection was present. Our results are in correlation with Mika Shapira-Rootman et al, who in their study (2015) also found out that during surgery pericholecystic collection was present in 47.14% cases.¹⁷

Empyema of the gall bladder was present in 10 cases (23.81%). The results are in correlation with study by Gagie N et al who concluded that 20.43% cases were empyema and 12.9% cases had gangrene.¹⁸

Gangrene was present in 3 patients (7.14%). Fistulous connection with gut was present in 2 patients (4.76%), one with the duodenum and one with transverse colon. 37 patients presented clinically as acute cholecystitis, were diagnosed as acute cholecystitis radiologically and confirmed as acute cholecystitis intraoperatively. 38 patients had clinical features of acute cholecystitis and were confirmed intraoperatively as acute cholecystitis. 41 patients had probable diagnosis of acute cholecystitis on radiological investigation and were confirmed as acute cholecystitis intraoperatively.

V. Conclusions

The number of patients presenting with acute cholecystitis is increasing because of the increased awareness, though some patients still visit local practitioners for treatment. The history and clinical examination along with radiological investigations is necessary to treat and manage the cases of acute cholecystitis. Surgery (cholecystectomy) remains the mainstay for treatment. With improved healthcare facilities and newer techniques, complications have declined substantially with reduced mortality and morbidity. Small sample size was the limitation of the present study so larger sample size is required for better analysis and results.

Bibliography

- [1]. Strasberg, SM (26 June 2008). "Clinical practice. Acute calculous cholecystitis". *The New England Journal of Medicine*. 358 (26): 2804–11.
- [2]. Sleisenger and Fordtran's *Gastrointestinal and Liver Disease: Pathophysiology, Diagnosis, Management* (10 ed.). Elsevier Health Sciences. 2015. p. 1154.
- [3]. Ansaloni, L (2016). "2016 WSES guidelines on acute calculous cholecystitis". *World Journal of Emergency Surgery : WJES*. 11: 25.
- [4]. NIDDK. November 2013. Archived from the original on 28 July 2016. Retrieved 27 July 2016.
- [5]. Greenberger N.J., Paumgartner G (2012). Chapter 311. Diseases of the Gallbladder and Bile Ducts. In Longo D.L., Fauci A.S., Kasper D.L., Hauser S.L., Jameson J, Loscalzo J (Eds), *Harrison's Principles of Internal Medicine*, 18e
- [6]. Strasberg SM (2008). "Acute Calculous Cholecystitis". *New England Journal of Medicine*. 358 (26): 2804–2811.
- [7]. Song G, Bian W, Zeng X, Zhou J, Luo Y, Tian X. Laparoscopic cholecystectomy for acute cholecystitis: early or delayed?: Evidence from a systematic review of discordant meta-analyses. *Medicine* 2016;95(23):e3835.
- [8]. Kimura, Yasutoshi; Takada, Tadahiro; Kawarada, Yoshifumi; Nimura, Yuji; Hirata, Koichi; Sekimoto, Miho; Yoshida, Masahiro; Mayumi, Toshihiko; Wada, Keita (2016-12-12). "Definitions, pathophysiology, and epidemiology of acute cholangitis and cholecystitis: Tokyo Guidelines". *Journal of Hepato-Biliary-Pancreatic Surgery*. 14 (1): 15–26.
- [9]. Hwang H, Marsh I, Doyle J. Does ultrasonography accurately diagnose acute cholecystitis? Improving diagnostic accuracy based on a review at a regional hospital. *Canadian Journal of Surgery*. 2014;2014 Jun(57(3)):162-168.
- [10]. Singh R, Jain A, Tyagi N. *Int Surg J*. 2016 Nov;3(4):2233-2238.
- [11]. Rains AJH, Ritchie HD. *The gall bladder and the bile duct, Bailey and Love's Short Practice of surgery*, HK Lewis and Co. Ltd., London, 17th Ed.; 1978:878-908
- [12]. Sangma MMB, Marak F. *Int Surg J*. 2016 May;3(2):914-920.
- [13]. Friedman L.S. (2015). *Liver, Biliary Tract, & Pancreas Disorders*. In Papadakis M.A., McPhee S.J., Rabow M.W. (Eds), *Current Medical Diagnosis & Treatment* 2015.
- [14]. Alan A B, Anand B, Julian K, Clinton S B. *Cholecystitis Clinical Presentation*. e-medicine Medscape. 2017
- [15]. Alper Bilal Ö, Mehmet T, Ersin Gürkan D, Birkan B, Ahmet Burak Ç, Fahri Y et al. Early Versus Delayed Laparoscopic Cholecystectomy for Acute Cholecystitis: A Prospective, Randomized Study. *International Surgery*. 2014;Jan-Feb(99(1)):56-61.
- [16]. David F, Charlotte M, Brice R, Hassene H, Thierry Y, Jean-Marc R. Acute Cholecystitis: Preoperative CT Can Help the Surgeon Consider Conversion from Laparoscopic to Open Cholecystectomy. *RSNA JournalRadiology*. 2012;263(1):128-138.
- [17]. Mika S, Ahmad M, Nadir R, Alicia N, Abdel-Rauf Z. Sonographic Diagnosis of Complicated Cholecystitis. *Journal of Ultrasound In Medicine*. 2015;34(12):2231-2236.
- [18]. Gagie N, Frey CF, Gaines R. *Acute cholecystitis, Surg. Gynecol. Obstet*. 1975;140(6):868-74.

Dr. Sudershan Kapoor. , "" "A study of clinical, ultrasonographic and intra-operative findings in acute cholecystitis". " IOSR Journal of Dental and Medical Sciences (IOSR-JDMS), vol. 17, no. 12, 2018, pp 56-61.