

A Comparative Study of Surgical Outcome in Acquired Nasolacrimal Duct obstruction after Conventional External DCR versus Endoscopic Endonasal DCR in a Tertiary Care Centre in Tripura

Dr. Anurag Majumdar^[1], Dr. Abhijit Ray^[2], Dr. Shivam Gupta^[3],
Dr. Rachit Jain^[4]

Corresponding Author: Dr. Abhijit Ray^[2], Asst. Professor, Dept. of Ophthalmology
Dept. of Ophthalmology^[1,2,3], Dept. of Otorhinolaryngology^[4],
Agartala Govt. Medical College and GB Pant Hospital, Agartala, Tripura

Abstract: Dacryocystitis is the inflammation of the lacrimal sac. Spontaneous resolution does not occur without treatment. ^[1]Treatment of choice for this disorder is dacryocystorhinostomy(DCR). The previously published literature shows success rate of both the approaches ranges from 63% - 97%. This study intends to compare the final result of surgical management of acquired naso-lacrimal duct obstruction between external DCR and endoscopic endonasal DCR. Total 60 patients were included for DCR operation. Out of which 30 patients underwent endoscopic endonasal DCR in the department of otorhinolaryngology and 30 patients underwent external DCR the department of ophthalmology. Post operative follow up was done for a period of 48 weeks. Silicone tube was removed after 6 weeks and patency test was done in first 4 weeks, 24 weeks and 48 weeks respectively.

Post operative complication mainly non-patency of nasolacrimal drainage system occurred near 12% of external DCR group and 15% of those with endoscopic endonasal DCRsurgery at the end of 48 weeks (p value 1.00)

Keywords: Dacryocystitis, dacryocystorhinostomy, endonasal, endoscopic DCR, nasolacrimal duct obstruction.

Date of Submission: 13-12-2018

Date of acceptance: 28-12-2018

I. Introduction

Dacryocystitis is the inflammation of the lacrimal sac. Spontaneous resolution does not occur without treatment. ^[1]Treatment of choice for this disorder is dacryocystorhinostomy(DCR). Dacryocystorhinostomy involves the establishment of an alternative pathway for drainage of tear. This pathway is established in between lacrimal sac and middle meatus of nose. Dacryocystorhinostomy (DCR) can be done either by an external approach (conventional DCR) or by an endoscope (endonasal endoscopic DCR). ^[2]

Toti in 1904 formerly described about the technique of external DCR. ^[3]Caldwell was the pioneer of the endonasal approach. All through in its beginning, this procedure was unsuccessful because of technical difficulty and lack of technology.

^[4] Later on Endonasal DCR gained popularity due to subsequent emergence of the nasal endoscope. ^[5]McDonough et al introduced the current technique of endonasal DCR. ^[6]

The previously published literature shows success rate of both the approaches ranges from 63% - 97%. ^[7,8]This wide range of success could be due to different surgical methods, patients demographic and lack of standardized procedure to measure the outcome. ^[9]This study intends to compare the final result of surgical management of acquired nasolacrimal duct obstruction between external DCR and endoscopic endonasalDCR.

II. Material And Methods

The present observational study was conducted in the Department of Ophthalmology and Department of Otorhinolaryngology, Agartala Government Medical College and GB Pant Hospital, Agartala. Total 60 patients were included for DCR operation. Out of which 30 patients underwent endoscopic endonasal DCR in the department of otorhinolaryngology and 30 patients underwent external DCR in the department of ophthalmology. Patient particulars were recorded. A detail history was taken. Thorough ophthalmological and otorhinolaryngological examinations were done. Patients having symptoms of watering and discharge with evidence of regurgitation on syringing were included in the study. Patients presenting with history of previous

DCR operation, obvious lower lid laxity, intranasal pathology i.e. deviated nasal septum, nasal polyp, and younger than 18 years were excluded from the study. Successful surgical outcome was defined by getting symptom free with patent lacrimal drainage system. Failure was defined as lack of symptomatic improvement and persistence of watering and/or discharge along with postoperatively non-patent lacrimal drainage system. All operations were performed under local anesthesia. Silicon tube was inserted intra operatively in all cases of endoscopic DCR. Post operative follow up was done for a period of 48 weeks. Silicon tube was removed after 6 weeks and patency test was done in first 4 weeks, 24 weeks and 48 weeks respectively. Statistical analysis was done with the help of Statistical software Epi Info Version 7. Categorical data were expressed in percentage (%). P value of <0.05 was considered statistically significant.

III. Results

Total 60 patients were included in this study. 30(50%) study population were male and 30(50%) were female. In conventional DCR there were 93.33% successful surgical outcome and in endoscopic endonasal DCR it was 90%. Evaluation of surgical outcome showed that conventional and endoscopic endonasal DCR had nearly similar success rate P value was more than 0.05 in respect to endoscopic endonasal DCR. Majority of the surgery were completed in between 1-1.5 hours in both external and endonasal DCR [Table 1]. Complication rate was very low in both types of surgery. Post operative complication mainly non-patency of nasolacrimal drainage system occurred near 12% of external DCR group and 15% of those with endoscopic endonasal DCR surgery at the end of 48 weeks (p value 1.00)

IV. Data Analysis

Table 1: Showing duration of surgery in both external and endonasal DCR.

Duration of surgery(minutes)	External DCR(n=20)	Endonasal DCR(n=20)	P value (Fisher's Exact test)
45 minutes	5	1	P=0.194
1-1.5 hour	20	23	P=0.567
> 1.5 hour	5	6	P=1.00

(Statistically Significant p value < 0.05)

Table 2: Shows Surgical results of study population

NLP patency	External DCR (n=20) No(%)	Endonasal DCR(n=20) No(%)	P value (Fisher's Exact test)
4 Weeks	30(100%)	30(100%)	P=0.00
24 Weeks	30(100%)	28(93.33%)	P=0.491
48 Weeks	28(93.33%)	27(90%)	P=1.00

(Statistically Significant p value < 0.05)

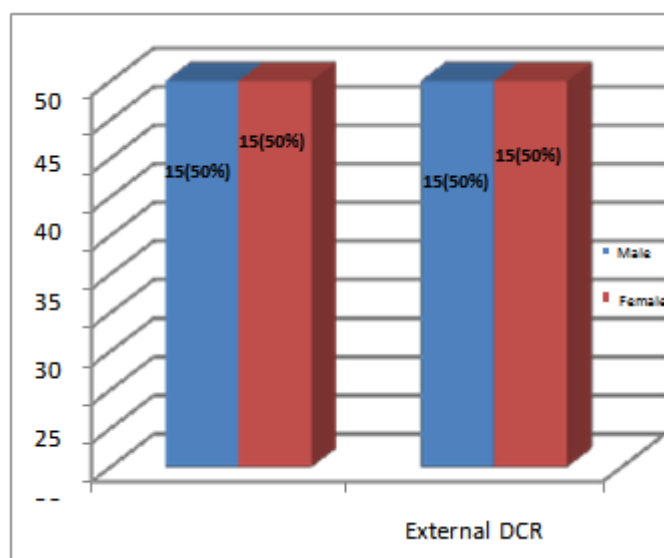


Figure 1: Showing gender distribution of endoscopic and external DCR.

V. Discussion

In chronic dacryocystitis, there is persistence of low grade infection in the nasolacrimal sac which ultimately comes to end with complete nasolacrimal duct (NLD) obstruction. The treatment of choice for Chronic Dacryocystitis is DCR. ^[10]External DCR still remains the gold standard treatment for NLD obstruction. Direct visualization of the anatomical structures of nose in external DCR has got advantages over endoscopic DCR. But it has got some disadvantages like cutaneous scar, injury to the angular vein and medial canthal structures, lacrimal pump failure and cerebrospinal fluid (CSF) rhinorrhea. ^[11]

Endonasal endoscopic DCR has got some advantages over external DCR. It's popularity increases due to its equally promising outcome and cosmetic superiority. Lacrimal sac pathology can be directly visualized through the endoscopic procedure and allows immediate diagnosis and management of nasal pathology. ^[9]Complication of endonasal endoscopic DCR is slightly more than external DCR. Intra operative bleeding, re-stenosis of the nasolacrimal opening, and some time injury to the orbital contents is associated with this procedure. External or endoscopic DCR is only indicated when the obstruction is away from the common canaliculus. ^[12]

In our study, right sided involvement was found in 67.7% of the cases. This finding is correlated with previous studies. ^[13,14] The exact cause of dacryocystitis in the right eye was not known. In our study, the most common presenting symptom was epiphora as found in earlier studies. ^[14-16] Probing of nasolacrimal duct and syringing for detection of nasolacrimal duct patency was done preoperatively in the operating eye. To find out the level of obstruction in the lacrimal apparatus Jones's dye test was also performed.

In a study in Bangladesh, Khan et al., reported that for endoscopic DCR the surgical duration was higher than external DCR, which were 59.7±8.8 minutes and 54.3±5.6 minutes respectively. ^[9]

Hartikainen et al., showed that average duration of surgery was 38 minutes and 78 minutes for endoscopic and external DCR respectively. ^[17] Muscatello et al., in their study found that duration of surgery ranges from 15-110 minutes and mean time for endonasal endoscopic DCR was 30 minutes. They also conclude that, with increasing surgical skill, duration of surgery progressively decreased. ^[18] In this present study we found that average time required to complete the surgery was 1 hour and 1-1.5 hours for endoscopic endonasal DCR and external DCR respectively. In our study, most of the surgery was done by junior residents who do not have much surgical experience. So the time taken to complete the surgeries was comparatively longer in duration. In this study, we can conclude that duration of surgery is directly related to the surgical skill and experience of the surgeon and intra-operative bleeding. The complication rate was seen to be low and comparable in both type of surgeries, as also seen in study done by Moras et al. ^[19]

We followed up our patients post operatively for 48 weeks. The surgical success rate in external and endoscopic DCR group was 100 % and 93.33% respectively after 24 weeks of follow-up period. At the end of 48 weeks of follow-up, 27(90%) out of 30 cases finally free from symptoms and had a patent pathway in endoscopic DCR. On the other hand, in external DCR it was 28 (93.33%) out of 30 cases. This difference was not statistically significant ($P=0.661$).

The success rate for endoscopic DCR was ranging from 78% to 97% in comparison to the "gold standard" external approach. ^[20,21] In our study surgical outcome in two groups is comparable to previously published studies worldwide. Khan et al, in their study, showed that successful surgical outcome was 73.3% with endoscopic approach as compared to 80%

with external approach. ^[9] Karim et al, has found similar success rate in two approaches, endoscopic DCR 82.4% versus external DCR 81.6% ($P=0.895$). ^[15] The study conducted by Gupta et al, reported that 90% cases of endonasal DCR had successful surgical outcome after a single procedure and it increases to 95% after revision procedure. This revision results was equal to the external approach. ^[22] In the study from west Bengal, Saha et al reported that surgical success rate of both the procedures were 93.3% in external DCR and 92% in endoscopic DCR after 6 month of followup.

^[13] Both the findings are nearly analogous to our study.

VI. Conclusion

From the above study, we can conclude that both external and endoscopic endonasal DCR has similar success rate and minimal complications. Yet endoscopic endonasal DCR produces no external scar. So, we suggest that endoscopic endonasal DCR should be the preferable intervention of choice for chronic dacryocystitis.

Bibliography

- [1]. Sihota R, Tandon R. Parsons' Diseases of the Eye. 20th Ed. New Delhi: Butterworth Heinemann Elsevier India; 2007. p.446-447.
- [2]. Vinod Gauba V. External Versus Endonasal Dacryocystorhinostomy In A Specialized Lacrimal Surgery Center. Saudi Journal of Ophthalmology. 2014;28: 36-39.
- [3]. Toti A. Nuovometodoconservatorecicuraradiclellesuppurazoni- croniche del saccolacrimal (Dacriocistorinostomia). Clin Mod

- Firenze1904;10:385-7.
- [4]. Caldwell GW. Two new operations for obstruction of the nasal duct, with preservation of canaliculi, and with an incidental description of a new lacrimal probe. *Am J Ophthalmol* 1893; 10:189-193.
- [5]. Stammberger H. Endoscopic endonasal surgery: concepts in treatment of recurring rhinosinusitis. Part II. Surgical technique. *Otolaryngol Head Neck Surg* 1986; 94(2):147-56.
- [6]. McDonough M, Meiring JH. Endoscopic transnasal dacryocysto- rhinostomy. *J Laryngol Otol* 1989; 103:585-7.
- [7]. Tarbet KJ, Custer PL. External dacryocystorhinostomy, surgical success, patient's satisfaction, and economic cost. *Ophthalmology* 1995; 102:1065-1070.
- [8]. Durvasula V, Gatland DJ. Endoscopic Dacryocystorhinostomy: Long term results and evolution of surgical technique. *J Laryngol Otol* 2004; 118:628-632.
- [9]. Khan MKH, Hossain MA, Hossain MJ, Al-Masud A, Rahman MZ. Comparative Study Of External And Endoscopic Endonasal Dacryocysto- rhinostomy For The Treatment Of Chronic Dacryocystitis. *JAFMC Bangladesh*. 2011;2:15-17.
- [10]. American Academy of Ophthalmology: BSCSC. Section-7. 2009-2010.p29.
- [11]. Shun-Shin GA, Thurairanjan G. External dacryocystorhinostomy – an end of an era? *Br J Ophthalmol* 1997; 81:716-717.
- [12]. Kanski JJ. *Clinical Ophthalmology A Systemic Approach*. 7th ed. London: Butterworth Heinemann Elsevier; 2007.p.75-78.
- [13]. Saha R, Sinha A, Phukan JP. Endoscopic versus external approach dacryocystorhinostomy: A comparative analysis. *Niger Med J*. 2013; 54:165-69.
- [14]. Nichlani SS, Jagade MV, Ganeshan A comparative study between endoscopic and external approach dacryocystorhinostomy. *Bombay Hosp J*. 2010;52:189-96.
- [15]. Karim R, Ghabrial R, Lynch TF, Tang B. A comparison of external and endoscopic endonasal dacryocystorhinostomy for acquired nasolacrimal duct obstruction. *Clin Ophthalmol*. 2011;5:979-89.
- [16]. Aslam S, Awan AH, Tayyab M. Endoscopic dacryocystorhinostomy: A Pakistani experience. *Pak J Ophthalmol*. 2010;26:2-6.
- [17]. Hartikainen J, Antila J, Varpula M, Puukka P, Sepp H, Grénman R. Prospective randomized comparison of endonasal endoscopic dacryocystorhinostomy and external dacryocystorhinostomy. *Laryngoscope* 1998;108:1861-6.
- [18]. Muscatello L, Giudice M, Spriano G, Tondini L. Endoscopic dacryocystorhinostomy: Personal experience. *Acta Otorhinolaryngol Ital*. 2005;25:209-13.
- [19]. Moras K, Bhat M, Shreyas CS, Mendonca N, Pinto G. External dacryocystorhinostomy versus endoscopic dacryocystorhinostomy: A comparison. *J Clin Diagn Res*. 2011;5:182-6.
- [20]. Smith W, Merkonidis C, Draper M, Yung M. Endoscopic dacryocystorhinostomy in warfarinized patients. *Am J Otolaryngol*. 2006;27:327-9.
- [21]. Jin HR, Yeon JY, Choi MY. Endoscopic dacryocystorhinostomy: Creation of a large marsupialized lacrimal sac. *J Korean Med Sci*. 2006;21:719-23.
- [22]. Gupta S, Goyal R, Thakur AS, Singh H. Conventional dacryocysto- rhinostomy versus endonasal dacryocystorhinostomy - a comparative study. *Peoples J Sci Res*. 2008;1:1-4.

Dr. Abhijit Ray. "A Comparative Study of Surgical Outcome in Acquired Nasolacrimal Duct obstruction after Conventional External DCR versus Endoscopic Endonasal DCR in a Tertiary Care Centre in Tripura." IOSR Journal of Dental and Medical Sciences (IOSR-JDMS), vol. 17, no. 12, 2018, pp 05-08.