

## Orbital Myocysticercosis: An Unusual Presentation

Amit Arora<sup>1</sup>, Gaurav Kapoor<sup>1</sup>, Harpreet A Singh<sup>2</sup>, Ashok Kumar<sup>1</sup>,  
Vikas Ambiya<sup>1</sup>, Shivani Arora<sup>3</sup>, Sonam Karan<sup>1</sup>

1.Department of Ophthalmology, Army College of medical sciences, Delhi Cantt

2.Department of Paediatrics, Army College of medical sciences, Delhi Cantt

3.SGRD Dental college, Amritsar, Punjab

Corresponding Author: Dr Gaurav Kapoor

Date of Submission: 13-12-2018

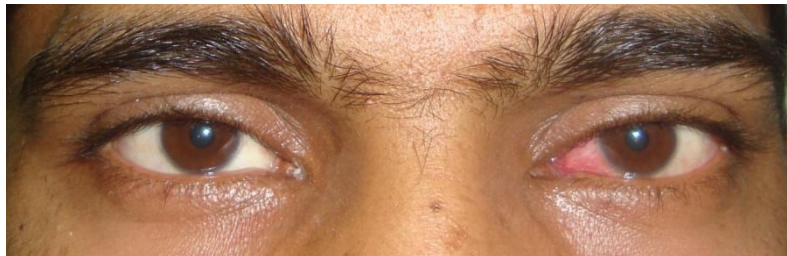Date of acceptance: 28-12-2018

### I. Introduction

Ocular cysticercosis is one of the most common parasitic infections in humans. Humans are occasionally infected with *Taenia solium* through the ingestion of contaminated water or uncooked pork and through autoinfection.<sup>1</sup> *Cysticercus cellulosae*, the larval form of the cestode, *Taenia solium*, affects human eye in 13–46% of larva infested patients. Ocular cysticercosis occurs in all ethnic groups regardless of dietary habits and is endemic in tropical areas, such as sub-Saharan Africa, India, East Asia, Mexico and Latin America.<sup>2</sup> The human becomes an accidental intermediate host by ingesting food or water contaminated with eggs or autoinfection. Ocular cysticercosis has varied presentations and may be extraocular (subconjunctival, extraocular muscles or orbital tissues) or intraocular (vitreous, subretinal space, or anterior chamber). Extraocular cysticercosis is reported more commonly from India.<sup>3</sup> We report a case of young individual presented to eye opd with conjunctival congestion and diagnosed as a case of extraocular cysticercosis.

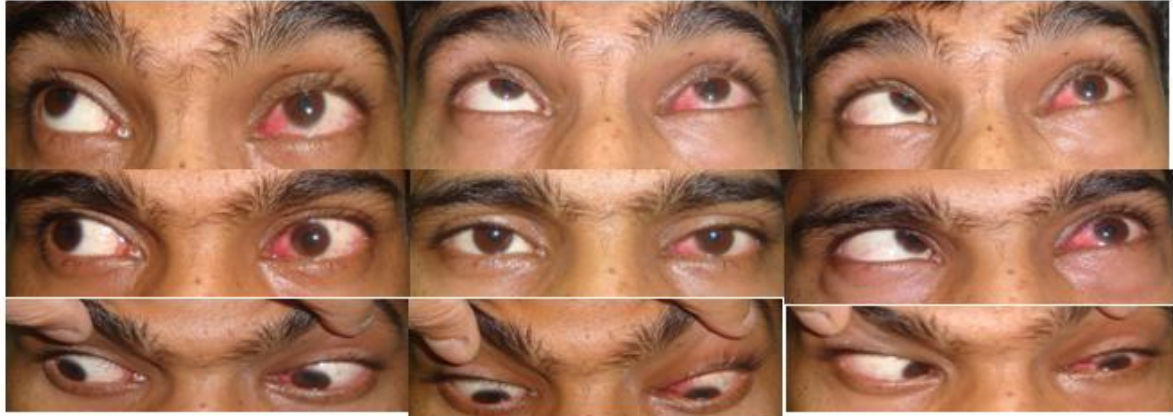### II. Case

A 22 year old male presented with h/o conjunctival congestion nasally in left eye for 3 days . It was associated with mild pain in left eye .There was no h/o diminution of vision, diplopia in primary gaze, watering or discharge. There was no h/o trauma and any associated systemic co-morbidities.



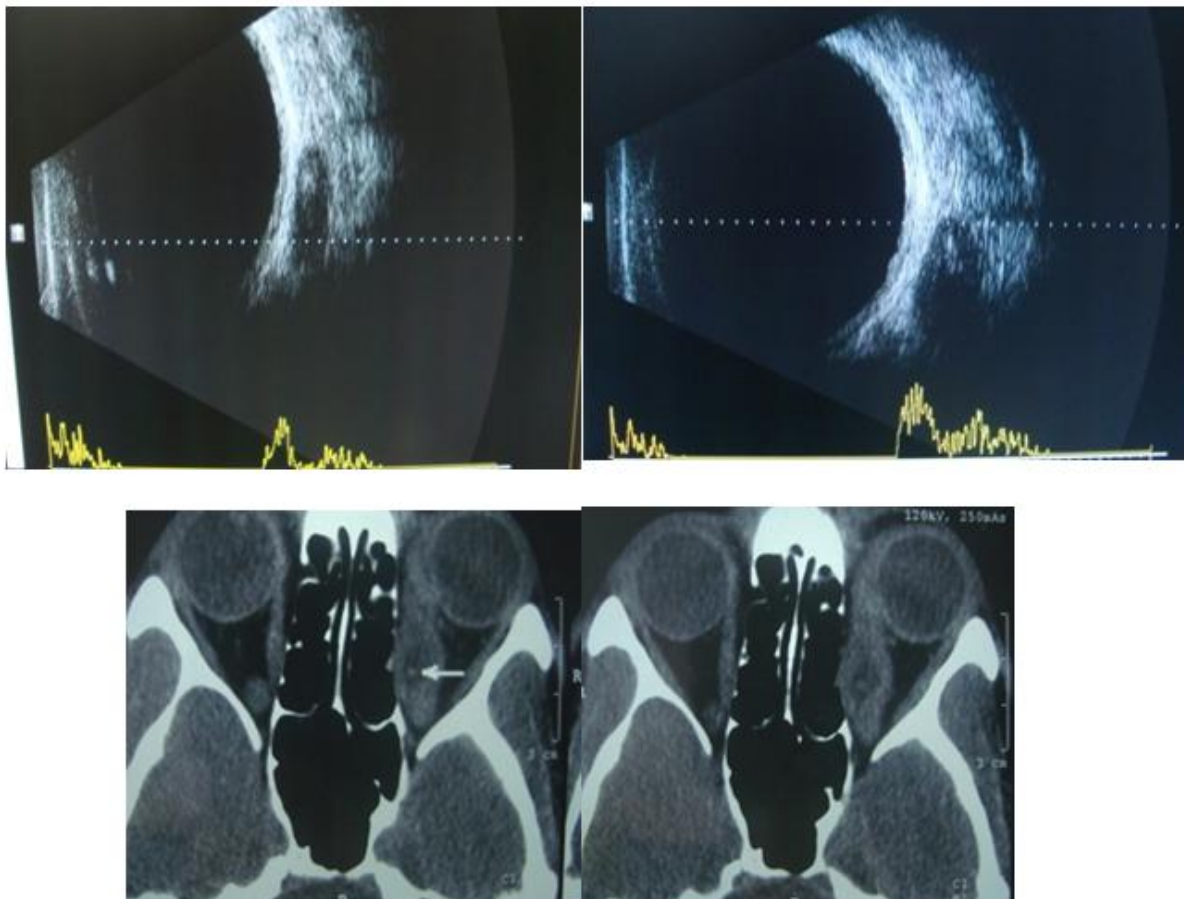
On ocular examination visual acuity was normal, BCVA- 6/6 (Both eyes),Right eye revealed normal anterior segment and fundus with intraocular pressure of 14 mm Hg. Left eye revealed periorbital edema, sectoral superficial conjunctival congestion(nasally) associated with underlying dilated and tortous episcleral vessels. Rest anterior segment and fundus were within normal limits with intraocular pressure of 40 mmHg.

Ocular movements in left eye were restricted in abduction,levelevation,levodepression on first day which progressed to restriction in all directions of gaze on second day of presentation. Hertel's exophthalmometry did not reveal any proptosis.



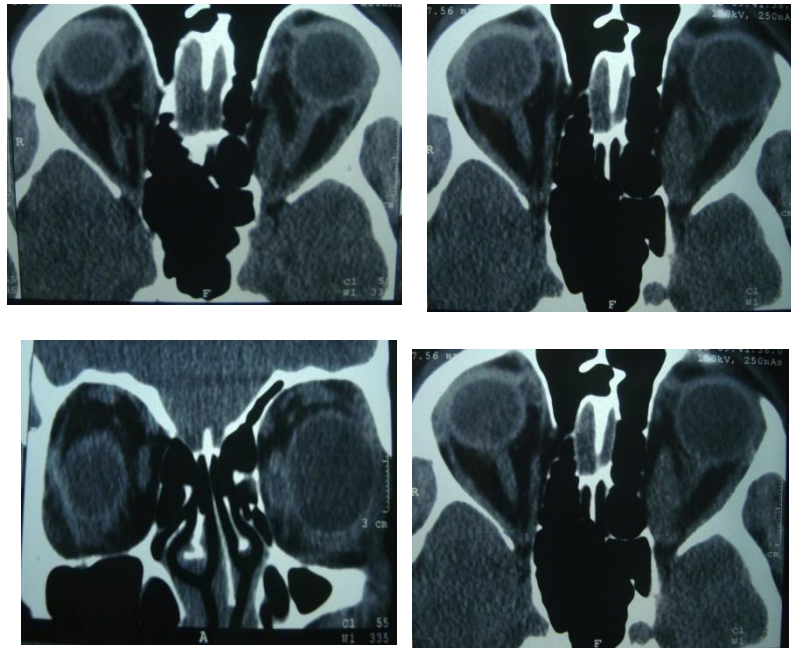
### III. Investigation

All biochemical and haematological investigations were within normal limits. X-ray chest, skull, upper arms and thighs were normal. MRI brain and optic nerve showed thickening of medial rectus with a large cystic lesion in left orbit adjacent to medial rectus. On the basis of clinical findings and MRI there was a high probability of the lesion being cysticercosis which was causing mechanical restriction of ocular movements due to mass effect. CT scan of orbits revealed a cystic lesion within the medial rectus muscle with intralesional calcific focus and the scolex could be visualised. CT scan(Brain and Orbit) revealed diffuse thickening of left medial rectus with ovoid cystic lesion with scolex measuring 12x6x6mm(APxTRxCC) within the muscle.



Patient was diagnosed as a case of **ORBITAL MYOCYSTICERCOSIS LEFT EYE** involving **MEDIAL RECTUS**. He was started on Tab. Albendazole 15mg/kg body wt in two divided doses for 30 days and Tab. Prednisolone 1.5mg/kg body wt.( tapering dose). Ocular movements in left eye slowly became normal in all directions of gaze, ocular congestion relieved and IOP decreased to 14mmHg after 1 month of treatment.

On follow up there is diffuse thickening of the left medial rectus with an ovoid cystic lesion within. As compared to the previous CT/MRI there is complete resolution of the dominant lesion, and persistence of the small, anteriorly placed lesion (7X5mm).



#### IV. Discussion

Orbital cysticercosis can present with a varied signs and symptoms like acquired strabismus, diplopia, recurrent redness, and proptosis. It has to be differentiated from other benign and malignant conditions presenting as ocular mass. One or more extraocular muscles may be simultaneously involved, although a propensity for involvement of the superior muscle complex and the lateral rectus muscles has been reported.<sup>4,5</sup>

In a retrospective case series by Rath et al., the cyst in 80.7% of orbital and subconjunctival cysticercosis is usually in relation to extraocular muscle.<sup>2</sup> The cyst attached to the muscle sheath induces an inflammatory reaction and because of its constant motility it comes to lie in subconjunctival space as subconjunctival swelling or erodes through the conjunctiva resulting in spontaneous extrusion.<sup>6,7</sup>

In this case individual presented with unusual presentation of conjunctival congestion nasally. On detailed examination found to have restricted ocular movements and raised suspicion of ocular pathology and found to have myocysticercosis. He was treated conservatively and responded well to treatment.

#### References

- [1]. Sawhney IM, Singh G, Lekhra OP, et al. Uncommon presentations of neurocysticercosis. *J Neurol Sci* 1998; 154:94–100.
- [2]. Kaliaperumal S., Rao V.A., Parija S.C. Cysticercosis of the eye in south India – a case series. *Indian J Med Microbiol.* 2005;23:227–230.
- [3]. Rath S., Honavar S.G., Naik M. Orbital cysticercosis: clinical manifestations, diagnosis, management, and outcome. *Ophthalmology.* 2010 Mar;117:600–605.
- [4]. Rath S., Honavar S.G., Naik M., Anand R., Agarwal B., Krishnaiah S. Orbital cysticercosis: clinical manifestations, diagnosis, management, and outcome. *Ophthalmology.* 2010;117:600–605.
- [5]. Sundaram P.M., Jayakumar N., Noronha V. Extraocular muscle cysticercosis – a clinical challenge to the ophthalmologists. *Orbit.* 2004;23:255–262.
- [6]. Mohan K., Saroha V., Sharma A. Extraocular muscle cysticercosis: clinical presentations and outcome of treatment. *J Pediatr Ophthalmol Strabismus.* 2005 Jan–Feb;42:28–33.
- [7]. Bansal R.K., Gupta A., Grewal S.P.S. Spontaneous extrusion of cysticercosis. Report of three cases. *Indian J Ophthalmol.* 1992;40:59–60.

Dr Amit Arora. “Orbital Myocysticercosis: An Unusual Presentation.”” *IOSR Journal of Dental and Medical Sciences (IOSR-JDMS)*, vol. 17, no. 12, 2018, pp 32-34.