

A Rare Case Of Unilateral Morning Glory Disc With PHPV Cataract And Prominent Ciliary Processes

Priti Shende¹, V Rajesh Prabu², JK Reddy³

¹-Fellow in Department of Paediatric Ophthalmology & Strabismus, Sankara Eye Hospital, Coimbatore, Tamil Nadu, India

²-Consultant & Head, Department of Paediatric Ophthalmology & Strabismus, Sankara Eye Hospital, Coimbatore, Tamil Nadu, India

³-Consultant & Head, Department of Cornea, Sankara Eye Hospital, Coimbatore, Tamil Nadu, India
*Corresponding Author: Priti Shende

Abstract: Morning glory disc anomaly is a congenital excavation of the posterior pole that involves optic disc. It is usually unilateral and common in females (2:1). Some authors postulate, as failure of closure of the fetal fissure and it is a variant of optic nerve coloboma. Alternatively, a primary mesenchymal abnormality has been demonstrated on the basis of the glial tuft, the scleral and vascular abnormalities. We report a case of an 11 year old girl, with diminution of vision in right eye along with deviation of eye inwards since childhood. Anterior segment showed prominent ciliary processes, cataract with morning glory disc and PHPV stalk attaching from the disc. There was no systemic abnormality. Patient underwent right eye cataract surgery. Morning glory syndrome is associated with many cerebrovascular abnormalities. Systemic workup should be done. Along with persistent hyperplastic primary vitreous, patient is at risk of developing strabismus, amblyopia. If diagnosed early, patients can be benefitted by surgery and restoration of vision.

Keywords: Morning glory disc, MGS, Persistent hyperplastic primary vitreous, PHPV, PAX 6

Date of Submission: 23-05-2018

Date of acceptance: 05-06-2018

I. Introduction

Morning glory syndrome is so named because of its resemblance to the morning glory flower. It was first named by killer in 1970. It is a congenital funnel shaped excavation of the posterior fundus which incorporates the optic disc, with a white tuft of glial tissue overlying the central portion of the disc and the increased number of blood vessels arising from the periphery of the disc.^[1] Persistent hyperplastic primary vitreous (PHPV) occurs because of failure of the primary vitreous and the hyaloid system to regress. PHPV typically manifests as unilateral, persistence of hyaloid system in the cloquet's canal. It is associated with microphthalmia, cataract, retinal traction or dysplasia, and elongation of ciliary processes.^[2,3]

II. Case Report

An 11 year old girl presented to our hospital with diminution of vision in right eye since childhood. Best corrected Visual acuity in Right eye was 3/60. Slit lamp biomicroscopy of the anterior segment showed posterior polar cataract and prominent ciliary processes (figure 1). Fundus examination with (+90 D and IDO) was done which showed funnel shaped excavated disc along with peripapillary staphyloma at the centre of which was a greyish white tuft of tissue with blood vessels running from the disc to the periphery of the retina (figure 2&3). These vessels were abnormally straight, veins and arteries which could not be precisely distinguished. B-scan ultrasound showed prominent hyaloid artery attached to the disc. Extraocular movements were full and free in all gazes and 14 prism dioptres of esotropia was noted on modified krimsky test. Left eye anterior and posterior segments were normal. Systemic examination was insignificant. Patient underwent an uneventful cataract surgery with PCIOL implantation through anterior limbal approach in the right eye. Best corrected visual acuity of 6/60 was achieved after one month. Patient is still under follow-up.

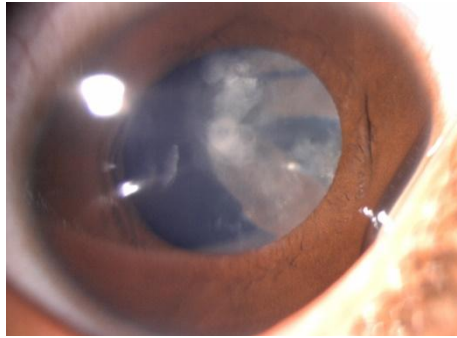


Figure 1

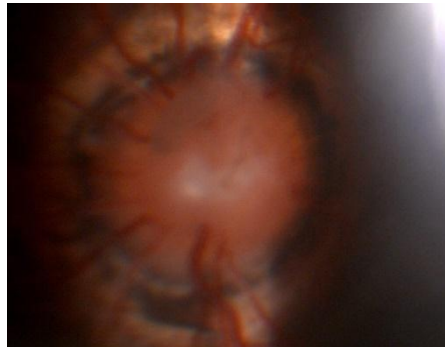


Figure 2

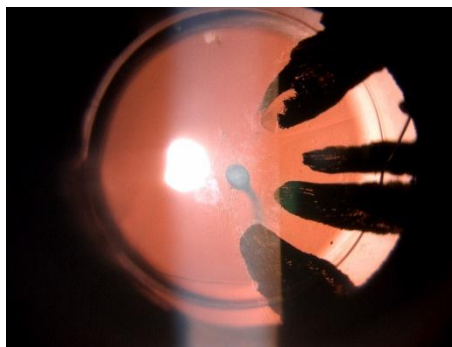


Figure 3

III. Discussion

The embryogenesis of morning glory disc is poorly understood. According to some authors, it results due to abnormal closure of the embryonic fissure. Recent studies suggested that it is a primary mesenchymal abnormality which results in faulty closure of posterior scleral wall and the poor development of lamina cribrosa. The association of MGS and PHPV suggested that regression of hyaloid vasculature is easily compromised in the presence of optic disc defects.^[4] PHPV may be a fundamental condition in MGS, it may present as anterior PHPV, Posterior PHPV, or a whitish glial tissue only (type of posterior PHPV). PHPV with MGS may have a genetic basis.^[5] Visual prognosis is good in anterior PHPV than the posterior. In this entity, the posterior pole is entirely normal with no evidence of retinal folds and no abnormality of optic nerve and macula. The ciliary processes can be quite elongated as they are drawn into the fibrovascular membrane. Elongated ciliary processes are pathognomonic of PHPV, but Oslen and Moller stated that it can occur in any cases associated with retrolental shrinkage.^[6]

PAX 6 is involved in ocular morphogenesis and is expressed in the developing central nervous system and various ocular tissues during development. PAX6 mutations have been identified in patients of optic disc malformations like coloboma, MGS, PHPV, optic nerve hypoplasia, and oraplasia.^[7]

Morning glory disc is commonly seen in females (2:1). If associated with PHPV, it can cause cataract, glaucoma, strabismus, amblyopia, retinal detachment, and even phthisis bulbi. Secondary glaucoma can occur in PHPV due to forward pushing of the iris lens diaphragm causing angle closure. Brown and associates reported 2 cases of PHPV in association with morning glory disc: one in a 37-year-old man and another in a 5-year-old boy.^[8] Cennamo and colleagues have reported another case of morning glory disc with PHPV and two

lens colobomas in a unilaterally involved eye.^[9] They believed that morning glory disc, optic disc pit, optic nerve coloboma were the variants of the same disease process and PHPV was a condition in which morning glory syndrome was part of the same entity. There are very few cases reported on morning glory disc with PHPV. MGS syndrome is associated with basal encephalocele, retinal arterio-venous communications, neurofibromatosis 2, midline or other brainstem abnormalities such as agenesis of corpus callosum, craniofacial clefting.^[10] Fortunately we did not find any such associations in our case.

IV. Conclusion

The main concern is to prevent complications like cataract, glaucoma, retinal detachment. If diagnosed early, it can help in restoring vision and preventing amblyopia. Regular follow-up is essential in these patients.

References

- [1]. Kindler P. Morning glory syndrome: unusual congenital optic disc anomaly. *Am J Ophthalmol* 1970;69:376-84.
- [2]. Reese AB. Persistent hyperplastic primary vitreous. *AM J Ophthalmol* 1955;40:317-31.
- [3]. Goldberg MF. Persistent fetal vasculature (PFV): an integrated interpretation of signs and symptoms associated with persistent hyperplastic primary vitreous (PHPV). *LIV Edward Jackson Memorial Lecture. AM J Ophthalmol* 1997;124:587-626.
- [5]. Pollock S. The morning glory disc anomaly: contractile movement, classification and embryogenesis. *Doc Ophthalmol* 1987;65:439-60.
- [6]. Cogan DG. Coloboma of optic nerve with overlay of peripapillary retina. *Br J Ophthalmol* 1978;62:347-50.
- [7]. Oslen J, Møller PM. Persistent primary hyperplastic vitreous. *Acta Ophthalmol* 1968;46:413-417.
- [8]. Azuma N, Yamaguchi, Handa H, et al. Mutations of the PAX6 gene detected in patients with a variety of optic nerve malformations. *Am J Hum Genet* 2003;72:1565-70.
- [9]. Brown GC, Gonder J, Levin A. Persistence of the primary vitreous in association with the morning glory disc anomaly. *J Pediatr Ophthalmol Strabismus* 1984;21:5-7.
- [10]. Cennamo G, Liguori G, Pezone A, et al. Morning glory syndrome associated with marked persistent hyperplastic primary vitreous and lens colobomas. *Br J Ophthalmol* 1989;73:684-6.
- [11]. Lee B, Traboulsi EI. Morning glory disc anomaly revisited. *Ophthalm Genet* 2008;29:47-52.

Priti Shende "A Rare Case of Unilateral Morning Glory Disc With PHPV Cataract and Prominent Ciliary Processes." *IOSR Journal of Dental and Medical Sciences (IOSR-JDMS)*, vol. 17, no. 6, 2018, pp 39-41.