

## Incidence of Ocular and Orbital Lesions in a Tertiary Care Hospital

Dr Sabbavarapu Mary Lavanya<sup>1</sup>, Dr Yejjala Akshay Babu<sup>2</sup>,  
Dr P.V.N. Kanchana<sup>3</sup>, Dr C.J. Raghuram<sup>4</sup>

(Consultant Pathologist, Pradhama multispeciality hospital, Visakhapatnam, India<sup>1</sup>, Postgraduate, Department of pathology, Maharajah's Institute of Medical Sciences, Vizianagaram, India<sup>2</sup>, Associate Professor I/C Head of the department, Department of pathology, Maharajah's Institute of Medical Sciences, Vizianagaram, India<sup>3</sup>, Associate Professor, Department of pathology, Maharajah's Institute of Medical Sciences, Vizianagaram, India<sup>4</sup>)

### Abstract:

**Introduction:** Ophthalmic lesions show varied distribution on the basis of geographical location. They include a wide range of lesions from benign, premalignant and malignant lesions. Eye being a unique sensory organ need to be studied both clinically and histopathologically.

**Materials and methods:** This study is a Restrospective-prospective study undertaken in the Department of Pathology at a tertiary care hospital over a period of 6 years (July 2013-June 2019).

**Results:** A total of 107 cases was studied, out of which benign combined with non-neoplastic lesions were more common, followed by malignant and other lesions. The most common age group of presentation was 41-50 years. Among all the cases, Squamous cell carcinoma was the most common malignant lesion in this study whereas nevus was a more common lesion in the benign category.

**Conclusion:** The most common ocular malignancy was Squamous cell carcinoma and among benign lesions, nevus was the most common, followed by cavernous hemangioma with male patients having a predominance among the total cases.

**Keywords:** Nevus, Cavernous hemangioma, Squamous cell carcinoma

Date of Submission: 17-01-2020

Date of Acceptance: 05-02-2020

### I. Introduction

Eye being a unique sensory organ needs to be studied both clinically and pathologically.<sup>1</sup> Vision is a major quality-of-life issue. The unprotected superficial location of eye and orbit are exposed to a myriad of adverse climatic conditions like toxic chemicals, solar radiation, physical trauma, antigens and microorganisms. Pathologies ranging from trauma, degenerative, inflammatory and neoplastic conditions can affect any of the various components of orbito-ocular system.<sup>2</sup> Numerous diseases affect the eye and careful communication with the ophthalmologist is essential for a meaningful diagnosis. A wide variety of tumors arise from different ocular structures.<sup>3</sup>

The ophthalmologist's need to preserve vision when treating malignancies requires the pathologist to adjust standard procedures for the gross examination of tissues and the construction of pathology reports. Although, the histopathologic diagnosis of basal cell carcinoma of eyelid or squamous dysplasia of the conjunctival epithelium might not be difficult, communicating precise information about margins of resection can be exceptionally challenging.

Surgical Pathologists will also encounter familiar neoplasms with unfamiliar behaviours within and around the eye. Although cutaneous and conjunctival melanomas originate in an epithelial compartment, uveal melanomas originate in mesenchymal compartments- The choroid, ciliary body and iris.<sup>4</sup>

Ophthalmic lesions, more precisely orbital and ocular tumors or tumor-like lesions, require surgical treatment mostly. Hence a correct preoperative provisional diagnosis followed by series of investigations and clinical examination and confirmation of the same by doing Histopathological examination of the specimen plays a huge role in treating both benign and malignant ocular and orbital lesions inpatient care.<sup>5</sup>

### II. Materials And Methods

This was a retrospective and prospective study conducted in the Department of Pathology, Maharajah's institute of medical sciences, Nellimarla, Vizianagaram. A total of 107 cases were studied in the duration of 6 years

**Study Design:** Descriptive Retrospective and prospective study.

**Study Location:** This study was conducted in the Department of Pathology, Maharajah's Institute of Medical Sciences, Nellimarla, Vizianagaram.

**Duration of study:** Retrospective study July 2013-June 2017 , Prospective study June 2017-June 2019

**Sample size:** 107 cases

**Inclusion criteria:** Surgical specimens of the ocular and orbital lesions received in the department.

**Exclusion criteria:** Inadequate biopsies.

**Methodology:** Histopathological sections, tissue blocks and case records for the retrospective cases were retrieved from the archives of the concerned departments. The cases from 2013 to 2017 were studied retrospectively.

Surgical specimens of the ocular and orbital lesions received in the department of pathology. All the details of specimens received in the pathology department namely identification, history and clinical details were noted. After gross examination findings recorded and sections from representative areas were taken, and subjected to processing by routine histopathological techniques.

The excised specimens were fixed in 10% formalin solution and routinely processed for histopathology using Haematoxylin and eosin staining. Special stains were done wherever required.

### III. Results

Among the total of 107 cases studied, 100 cases were biopsy specimens, and 7 cases of which were enucleation specimens and 2 were exenteration specimens. Among all cases, most of them were biopsy specimens.

**Age-wise distribution:**

The present study included patients in the age range of 7 days to 80 years. The commonest age group was 41-50 years (20.56%). The youngest age of presentation was 7 days and the oldest age was 80 years.

**Table no.1:** Age-wise distribution of the study group

Age	Total	Percentage
0-10	8	7.47%
11-20	14	13.08%
21-30	8	7.47%
31-40	18	16.82%
41-50	22	<b>20.56%</b>
51-60	14	13.08%
61-70	16	14.95%
>70	7	6.57%
Total	107	100%

**Table no.2 :** Categories of lesions as per age

Age	Diagnosis				
	Developmental	Inflammatory	Benign	Malignant	Others
0-10	1	0	4	2	1
11-20	3	0	10	0	1
21-30	2	2	4	0	0
31-40	0	3	4	8	3
41-50	0	4	8	6	4
51-60	0	1	2	9	2
61-70	0	1	3	11	1
>70	0	2	2	3	0
Total	6	13	37	39	12
%	5.6%	12.15%	34.58%	36.45%	11.22%

The developmental lesions were commoner before the age of 20 years of age, inflammatory were common in 31-50 years of age group, benign were more common in 11-20 years, and malignant were more common in more than 50 years of age.

**Sex distribution:**

Out of the total 107 cases, there were 59 males and 48 females showing a male preponderance.

**Table no. 3:** Distribution of the study group by sex.

Sex	No. of patients	Percentage
Male	59	<b>55.15%</b>
Female	48	44.85%
Total	107	100%

**Site wise distribution:**

Among all the cases observed, eyelids were involved most often than all other sites, with 44% (47/107) cases, followed by conjunctiva 18.7%(20/107).

**Table no. 4 :** Site wise distribution of ophthalmic lesions

Site	No. of patients	Percentage (%)
Eyelids	47	<b>44%</b>
Conjunctiva	20	18.7%
Orbit	19	17.6%
Lacrimal gland and sac	10	9.4%
Ocular globe	7	6.6%
Medial canthus	4	3.7%

**Distribution of lesions:**

The most common of the benign lesions was nevus, followed by cavernous hemangioma.

**Table no.5:** Histologic types of benign ophthalmic lesions

Type of benign lesions	No. of patients	Percentage (%)
Nevus	9	<b>24.32%</b>
Trichilemmal cyst	1	2.7%
Lipoma	1	2.7%
Seborrheic keratosis	2	5.41%
Pyogenic granuloma	2	5.41%
Benign lymphoepithelial	1	2.7%
Fibrous dysplasia	1	2.7%
ALHE	1	2.7%
Cavernous hemangioma	6	8.11%
Neurofibroma	5	13.51%
Pleomorphic adenoma	1	2.7%
Squamous papilloma	3	8.11%
Schwannoma	2	5.41%
Rhabdomyoma	1	2.7%
Chondroid syringoma	1	2.7%
Total	37	100%

From the table below, the frequency of different malignant lesions can be noted. The most common among them was Squamous cell carcinoma(SCC), followed by basal cell carcinoma(BCC).

**Table no. 6:** Histologic types of malignant ophthalmic lesions:

Malignant lesions	No. of patients	Percentage (%)
SCC	12	<b>30.8%</b>
Basal cell carcinoma(BCC)	11	28.3%
Meibomian gland carcinoma(MGC)	5	12.8%
Embryonal rhabdomyosarcoma	1	2.56%
Adenoid cystic carcinoma	2	5.1%
NHL	4	10.22%
Retinoblastoma	1	2.56%
Malignant melanoma	2	5.1%
Hemangiopericytoma	1	2.56%
Total	39	100%

**Eyelid lesions:**

Among all the cases, 47 lesions were of eyelid, 28 were benign and the commonest was nevus 21.43%(6/28), and 19 were malignant the most common lesion in that category was basal cell carcinoma 52.64%(10/19)

**Table no.7:** Frequency of benign and non neoplastic lesions in the eyelid:

Types of benign and non-neoplastic lesions of eyelid	No. of patients	Percentage(%)
Nevus	6	<b>21.43%</b>
Chalazion	2	7.14%
Granulomatous	2	7.14%
Dermoid cyst	2	7.14%
Epidermal inclusion cyst	3	10.71%
Pyogenic granuloma	1	3.57%
Seborrheic keratosis	1	3.57%
Trichilemmal cyst	1	3.57%
ALHE	1	3.57%

Neurofibroma	5	17.86%
Cavernous Hemangioma	1	3.57%
Squamous papilloma	1	3.57%
Rhabdomyoma	1	3.57%
Chondroid syringoma	1	3.57%
Total	28	100%

**Table no. 8:** Frequency of malignant lesions of eyelid:

Types of malignant lesions of eyelid	No. of patients	Percentage (%)
BCC	10	<b>52.64%</b>
MGC	5	26.32%
SCC	3	15.78%
NHL	1	5.26%
Total	19	100%

**Table no.9:** Various types of orbital lesions:

Orbital lesions	No. of patients	Percentage(%)
Dermoid cyst	1	5.26%
Inflammatory Pseudotumour	1	5.26%
Chronic inflammatory lesion	1	5.26%
Cavernous hemangioma	5	<b>26.32%</b>
Fibrous dysplasia	1	5.26%
Schwannoma	1	5.26%
Malignant melanoma	2	10.53%
Adenoid cystic carcinoma	1	5.26%
NHL	3	15.8%
Hemangiopericytoma	1	5.26%
Others	2	10.53%
Total	19	100%

**Table no. 10:** Various types of conjunctival lesions:

Various types of conjunctiva lesions	No. of patients	Percentage(%)
Keratitis	2	10%
Epithelial inclusion cyst	2	10%
Pyogenic granuloma	1	5%
Squamous papilloma	2	10%
Nevus	3	15%
Lipoma	1	5%
Bowen's disease	3	15%
SCC	6	<b>30%</b>
Total	20	100%

**Lacrimal Gland and Sac:**

Among 10 cases, 4 were chronic dacryocystitis, 2 are an infection caused by Rhinosporidiosis, one case being pleomorphic adenoma, one case of adenoid cystic carcinoma and remaining 2 cases were Kimura's and lymphoepithelial lesion.

**Medial Canthus:**

Among all the 107 cases, 3 cases were in this area, out of which 2 cases were dermoid cyst and one case of basal cell carcinoma with squamous differentiation.

**Intraocular lesions:**

Out of all the cases, 5 were enucleations and 2 exenterations, Four were tumors: retinoblastoma, choroidal schwannoma, malignant melanoma and a rare lesion encountered which was embryonal rhabdomyosarcoma. The rest of the three cases show atrophic changes, cornea with fibrosis and vitreous haemorrhage.

**IV. Discussion**

The eye is an important organ among all others in the human body. We come across various ophthalmic lesions. A few lesions are very aggressive and it may endanger the patient's vision and life. The early and accurate diagnosis without much inconvenience to the patient helps in the early treatment, especially makes a huge impact on the outcome of malignant conditions.<sup>6,7</sup>

Among the total 107 cases studied, 100 cases (%) were biopsy specimens and 5 cases (%) of which were enucleation specimens and 2 were exenteration specimens. Among all cases, most of them were biopsy specimens.

In the present study, it was found that ophthalmic lesions were highest (20.56%) in the 41-50 year age group. These figures were in correlation with a study done by Shastry Srikanth<sup>8</sup>(2014) and Subba Rao et. Al<sup>9</sup>

(2016) showing the highest (34.56%) in that age group. Among all the 107 cases, 59 (55.15%) were male patients and 48(44.85%) were female patients. A male preponderance was observed in this study with 1.2:1. A similar observation was noticed by Pudasaini et al<sup>10</sup>, Gupta Y et al<sup>1</sup> and Onwubuya IM<sup>11</sup>. The most common site of involvement is the eyelid in 44% of cases which correlated with the finding of Bastola P et. Al 2013<sup>12</sup> who reported 57% and Wani LA et al<sup>13</sup> who reported 43.33%.

In the present study, a predominance of benign and non-neoplastic lesions together consisting of 52.33% and malignant lesions consisting of 36.45% and other lesions being 11.22%. These values were correlated with the studies done by Wani LA et al<sup>13</sup> with 52.83% cases reported as benign and 33.96% as malignant. They were also similar to studies by Chauhan SC et al<sup>14</sup> and Shah AS et al. <sup>15</sup>

Among the Benign lesions, Nevus was the commonest 24.32%, followed by cavernous hemangioma 16.22%, which was in correlation with studies by Wani LA et al<sup>13</sup> and Kudrimoti J et al. <sup>16</sup>, out of which 4 were intradermal nevi. Among the malignant lesions, Squamous cell carcinoma was the commonest lesion comprising of 30.8%, followed by BCC 28.3% which was correlating with the results of a study done by Wani LA et al<sup>13</sup> which were 44.4% for SCC and 27.77% for BCC. The increase in the incidence of SCC might be due to the solar radiation effect.

In the present study, the most common benign tumor of the eyelid was nevus 21.43% and the most common malignant tumor of the same was BCC followed by MGC which was in correlation with Studies by Subba Rao AV et al<sup>9</sup> for nevus and Farhat F et al. and Sean Paul et al.<sup>18</sup> for BCC. In this study, one Case of Angiolymphoid hyperplasia with eosinophilia(ALHE) was encountered with bilateral eyelid involvement. Ueda et al. stated that the involvement of bilateral ocular adnexa is rare.<sup>20</sup>. Although its cause remains uncertain, Trauma preceded the onset in a few.<sup>4</sup>

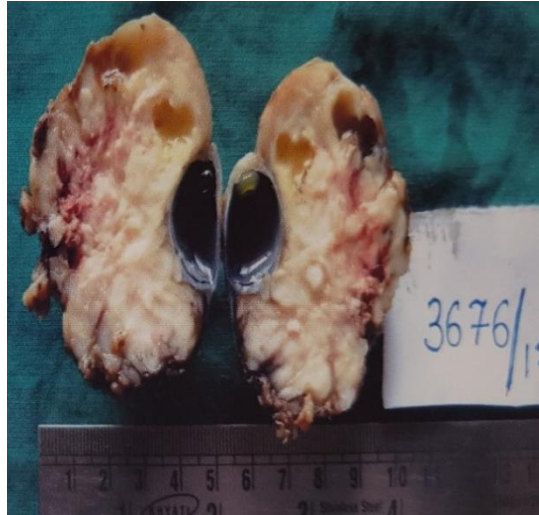
In the orbit, the most common lesion was benign being cavernous hemangioma 26.32% which correlated with Domingo RED et al<sup>27</sup> and the most common malignant lesion in this area was Non hodgkins lymphoma(NHL) which correlated with Bastola P et al<sup>12</sup> and Gupta Y et al.<sup>1</sup> One case of Fibrous dysplasia, Inflammatory pseudotumor and ancient schwannoma were also encountered. Schwannomas of the orbit are rare and account for only 1-6%. Among the malignant tumors, 2 cases of Malignant melanoma and one case of adenoid cystic carcinoma and a rare lesion of hemangiopericytoma were found in the study.

Primary Malignant melanoma is exceedingly rare, with approximately 50 cases reported to date. Anna M. Rose et al.<sup>30</sup> reported 13 cases of orbital malignant melanomas in 25yearperiod. They also stated that they can remain quiescent for extended periods of time before following an aggressive course. Hemangiopericytoma is a very rare orbital tumor. In a study, Chi-Hsin Hsu et al.<sup>29</sup> reported only six cases of these lesions during 9 years period.

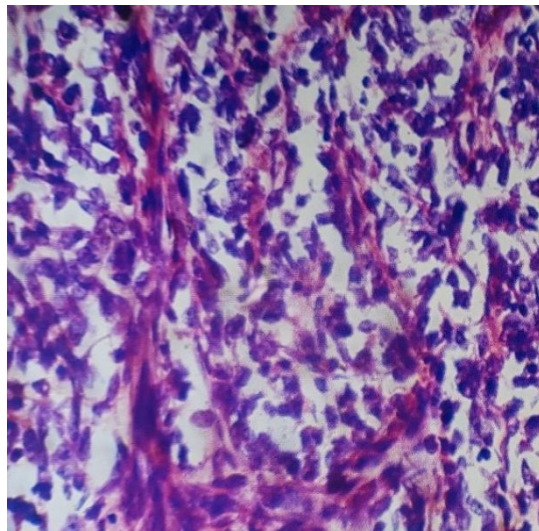
In the present study, malignant lesions of the conjunctiva showed an increase in the incidence due to the increase in the invasive SCC 30%, which correlated with Ud-Din N et al<sup>19</sup>, Bastola P et al<sup>12</sup>, Charles NC et al<sup>21</sup> and Gupta et al<sup>1</sup>. The most common benign lesion in this area was nevus 15% which correlated with Subba Rao AV et al.<sup>9</sup> One case of squamous papilloma along with other lesions, were found in this study. A few studies state that it can occur as a result of ocular surface infection by HPV<sup>22</sup>. The high rate of conjunctival inflammatory lesions may be due to a high rate of usage of traditional medications in our environment in addition to other factors like trauma, presence of foreign body and facial rash.<sup>24</sup> Of the 9 cases of malignant lesions, 3 were intraepithelial tumors and 6 were malignant. These values correlated with Tunc M et al., who reported 22 intraepithelial tumors and 38 invasive SCC. Intraepithelial squamous, previously known as Bowen's disease and invasive squamous cell carcinoma of the conjunctiva is histologically differentiated according to the invasion of the basement membrane as in the latter cells invade the substantia propria.<sup>22</sup>

Lacrimal sac lesions constitute about 5%-13% of all the lesions.<sup>23</sup> Among the 10 cases, most common was dacryocystitis 4, which correlated with the study by Shields CL et al. who reported 142 cases lacrimal gland lesions. 2 cases were rhinosporidiosis and this incidence is due to increased prevalence in southern India. Management is by surgical removal followed by histopathological confirmation as the organism is always found in the lesions.<sup>25</sup> Only one case of adenoid cystic carcinoma was received. Font RL et al. stated that these are rare malignant tumors accounting for 1.6% of all orbital tumors.<sup>26</sup>

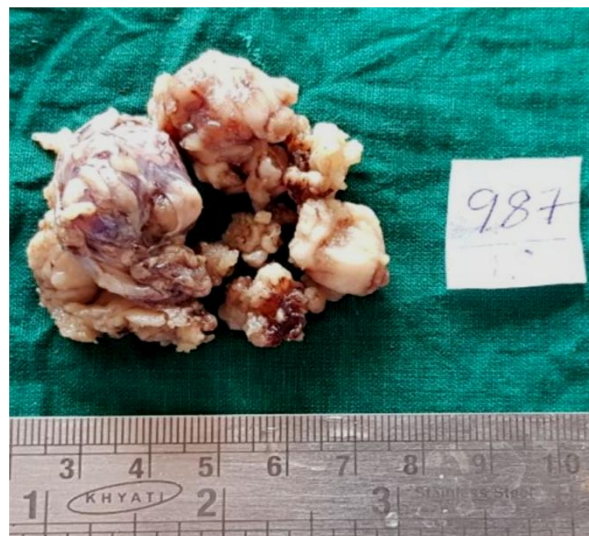In the present study, only one case of retinoblastoma was reported in a 2-year-old female among the lesions of the retina which correlated with a study done by Kudrimoti J et al.<sup>16</sup> One rare case of embryonal rhabdomyosarcoma(RMS) was reported and the age of presentation was a 7-day female. RMS is a common, highly malignant childhood tumor and is extremely rare in neonates consisting of about 1%-2% of all childhood RMS.



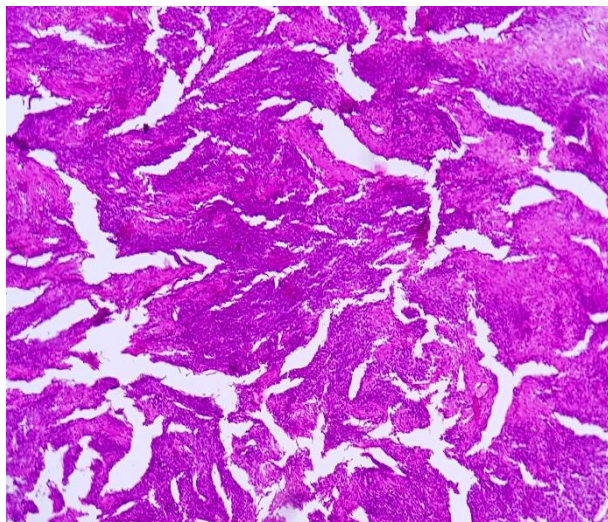
**Image 1 :** Gross specimen of Embryonal Rhabdomyosarcoma: Cut section showing grey white tumor with cystic spaces behind the eyeball.



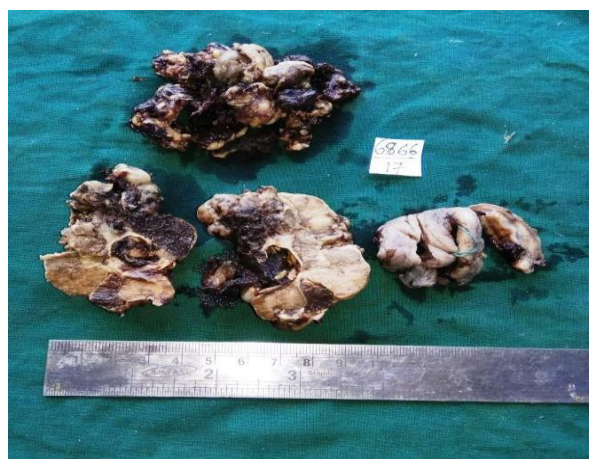
**Image 2 :** H&E (400x): Primitive cells devoid of rhabdomyoblastic differentiation with focal areas showing elongated cells having cross striations.



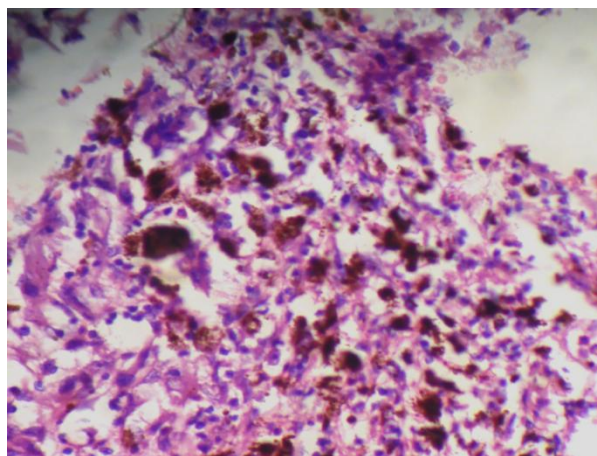
**Image 3:** Gross specimen of hemangiopericytoma: Partially capsulated mass with a nodular surface with areas of congestion.



**Image 4: H&E (100x): Proliferation of small benign-appearing spindle cells around branching blood vessels showing a staghorn appearance.**



**Image 5: Grey-white to grey-brown nodular soft tissue masses along with eyeball.**



**Image 6: H&E (400x): Oval to polyhedral cells with few areas showing spindle patterns with numerous areas of pigmentation.**

## **V. Conclusion**

The eye is the vital organ of the body for vision. Varied presentation and a vast spectrum of neoplastic and non-neoplastic lesions as encountered in the present study, emphasize the need for a region-wise study. The study concluded that a histopathological examination of excised or incised orbital or ocular lesions are absolutely mandatory for each case to a definitive diagnosis and further care of patients in management.

## References

- [1]. Gupta Y, Gahine R, Hussain N and Memon MJ. Clinico-pathological spectrum of Ophthalmic Lesions: An experience in Tertiary care hospital of central India. *J Clin Diagn Res.* @2017;11(1): EC09-EC13.
- [2]. 3. Eye an ocular adenexa. In: Rosai J, (editor). *Rosai and Ackerman;s Surgical Pathology.* 10<sup>th</sup> ed. New York, USA: Elsevier: Elsevier; 2004. P. 2467-501.
- [3]. 4. Klintworth GK. The eye and ocular adnexa. In: Stacey E. Mills ed. *Sternberg’s Diagnostic pathology* 6<sup>th</sup> ed. Mosby;2005;1073-1180.
- [4]. 5.Robert Foldberg. Tumors of the eye and ocular adnexa. In: Christopher D.M. Fletcher *Diagnostic Histopathology of Tumors.* 4<sup>th</sup> ed. Vol(2); 2086-2116.
- [5]. 6.Dutton JJ. Orbital diseases. In Yanoff M, Duker J S. *Ophthalmology.* 2<sup>nd</sup> ed. Elsevier; 2004. p729.
- [6]. 100. Ceylan OM, Uysal Y, Erdurman FC et al. Clinical and histopathological analysis of conjunctival tumors. *Gulhane Med J* 2010; 52:248-51.
- [7]. 101.Saornil MA, Becerra E, Mendez MC, Blanco G. Conjunctival tumors. *Arch Soc Esp Oftalmol* 2009; 84:7-22.
- [8]. 56.Srikanth S. Spectrum of histopathological study of ocular lesions: One year study. *J NTR Univ Health Sci* 2014;3:12-4
- [9]. 64.Subba Rao AV, Karthika ML, Manasa RV. Distribution and Histopathological Evaluation of eyelid, Conjunctival and orbital tumors. *IOSR Journal of Dental and Medical Sciences.* 2016;15(9).PP 59-62.
- [10]. 54.Pudasaini S, Kansakar I, Prasad KBR, Rauniyar SK. A histopathological study of ophthalmic lesions. *Nepal Med Coll J* 2013; 15(1): 78-80.
- [11]. 60.Onwubuya IM, Owoyele TM, Olaofe OO, Ezike KN. Morphological Spectrum of Orbitoocular Diseases in a Tertiary Health Centre in Keffi, North Central Nigeria. *Advances in Medicine.*2015;Article ID619414: 5 Pages.
- [12]. 52.Bastola P, Koirala S, Pokhrel G, Ghimire P, Adhikari RK. A Clinico-Histopathological Study of Orbital and Ocular Lesions; a Multicenter Study. *Journal of Chitwan Medical College.* 2013; 3(4): 40-44.
- [13]. 63.Wani LA, Sahaf BR, Mushtaq S, Akhter R, Qayoom N, Rashid S, Reshi R. Morphological Spectrum of Ophthalmic Biopsies from a tertiary care hospital in Kashmir. *International Journal of Currents Research* 2016; 8(9): 39383-85.
- [14]. 48.Chauhan SC et al. A histopathological study of ophthalmic lesions at a teaching hospital. 2012; 2(2); 133-136.
- [15]. 62.Shah AS, Ganguly, Das J, Das SS, Phukan A. Spectrum of ocular lesions in a tertiary care centre: a five year retrospective study. *Int J Res Med Sci.* 2016; 4(5):1355-1360.
- [16]. 65.Kudrimoti J, Khedkar S, Gholap S, Jadhav M. A pathologic review of ophthalmic neoplasms at tertiary care hospital. *Indian Journal of Basic and Applied Medical Research.* 2016; 6; (1): 415-419.
- [17]. 35. Farhat F, Jamal Q, Saeed M, Ghaffar Z. Evaluation of eyelid lesions at a tertiary care hospital, Jinnah Postgraduate Medical Centre (JPMC), Karachi. *Pak J Ophthalmol* 2010; 26(2):83-86.
- [18]. 40. Sean Paul, Dat T, Rona Z. Slikiss. Malignant and benign eyelid lesions in San Francisco: Study of a diverse urban population. *Am J of Cli Med.* 2011;(8) 40-46.
- [19]. 24. Ud-Din N, Mushtaq S, Mamoon N, Khan AH, Malik IA. Morphological Spectrum of ophthalmic tumors in northern Pakistan. *J Pak Med Assoc.* 2001;51:19-22.
- [20]. 50. Ueda et al.: Angiolymphoid hyperplasia with eosinophilia occurring in bilateral eyelids. *BMC Ophthalmology* 2013;13:38.
- [21]. 57. Charles NC, James EV. A study of the histopathological pattern of orbito-ocular disease in a tertiary hospital in Nigeria. *Sahel med J* 2014;1760-4.
- [22]. 104. Lee GA, Hirst LW. Ocular surface squamous neoplasia. *Surv Ophthalmol* 1995;39:429-49.
- [23]. 106. Shields CL, Shields JA, Eagle RC, Rathmell JP. Clinicopathologic review of 142 cases of lacrimal gland lesions. *Ophthalmology.* 1989; 96(4):431-435.
- [24]. 105.Ukponmwan CU, Momoh N. Incidence and complications of traditional eye medications in Nigeria in a teaching hospital. *Middle East Afr J Ophthalmol* 2010;17:315-9.
- [25]. 111.Mukherjee B, Mohan A, Sumathi V, And Biswas J. Infestation of the lacrimal sac by *Rhinosporidium Seeberi*: A clinicopathological case report. *Indian J Ophthalmol.* 2013 Oct; 61(10): 588-590.
- [26]. 18.Font RL, Smith SL, Bryan RG. Malignant epithelial tumors of the lacrimal gland: a clinicopathological study of 21 cases. *Arch Ophthalmol.* 1998;116(5): 613-616.
- [27]. 61. Domingo RED, Manganip LE, Castro RM. Tumors of the eye and ocular adenexa at the Phillipines eye research institute: 10-year review. *Clin Ophthalmol.* 2015; 9:1239-1247
- [28]. 20. Tunc M, Char DH, Crawford B, Miller T. Intraepithelial and invasive squamous cell carcinoma of the conjunctiva: analysis of 60 cases. *Br J Ophthalmol* 1999;83:98-103.
- [29]. Chi-Hsin Hsu, Yi-Hsuan Wei, Yeh Peng. Orbital Hemangiopericytoma in an Asian Population:*Journal of the Formosan Medical Association* June 2014 ; 6: 113; 356-363.
- [30]. Rose, Anna & Luthert, Phil & Jayasena, Channa & Verity, David & Rose, Geoffrey. (2017). Primary Orbital Melanoma: Presentation, Treatment, and Long-term Outcomes for 13 Patients. *Frontiers in Oncology.* 7. 10.3389/fonc.2017.00316.

Dr Sabbavarapu Mary Lavanya, etal. “Incidence of Ocular and Orbital Lesions in a Tertiary Care Hospital”. *IOSR Journal of Dental and Medical Sciences (IOSR-JDMS)*, 19(2), 2020, pp. 10-17.