

Role of Varicocele in Primary Male Infertility Based On Semen Parameters and Pregnancy

Dr Rajkamal Kanojiya¹, Dr Ankit Goyal², Dr Himad Rathod³

¹Professor & Unit Head, Department of General Surgery

² Post Graduate Resident 3rd Year, Department of General Surgery

³Post Graduate Resident 1st Year, Department of General Surgery

Mahatma Gandhi Medical College & Hospital, Sitapura, Jaipur, Rajasthan

Corresponding Author: Dr Ankit Goyal

Abstract: The most common type of male infertility is idiopathic, which is characterized by the presence of one or more abnormal semen parameters with no identifiable cause. Varicoceles are dilatation and tortuosity of the testicular & pampiniform plexus of veins. The surgical treatment is varicocelelectomy i.e. ligation of testicular veins along with pampiniform plexus. Evaluation of a male patient with infertility should include a careful medical and reproductive history, physical examination, and at least two semen analyses. Varicoceles are typically graded on a scale of 1 to 3.

Aim & Objectives : To establish varicocelelectomy as an standard treatment option for male infertility with varicocele before assisted reproductive techniques .

Material & Methods: The study was done on 50 patients with varicocele with infertility prospectively from November 2017 to August 2019.

Observation : There is a significant improvement in sperm motility in both grade 2 & 3 varicoceles which is upto 60 % in grade 2 and 66 % in grade 3 after 12 months.

There is a significant improvement in sperm motility in both grade 2 & 3 varicoceles. In grade 2 varicocele patients 27.78 % i.e. 5 out of 18 in left sided and 25% i.e. 1 out of 4 in right sided pathology were able to conceive . In grade 3 varicocele 44% i.e 11 out of 25 in left sided and 33.3% i.e 1 out of 3 in right sided were able to conceive .

Date of Submission: 17-01-2020

Date of Acceptance: 05-02-2020

I. Introduction

Infertility is considered as one of the main public health issues, as it affects about 15% of the couples in their reproductive age.^{1,2} The male factor is involved in 40%–50% of infertility cases.³ The most common type of male infertility is idiopathic, which is characterized by the presence of one or more abnormal semen parameters with no identifiable cause. Another common cause of male infertility is varicocele. Varicoceles are dilatation and tortuosity of the testicular & pampiniform plexus of veins. While varicocele has an incidence of 4.4%–22.6% in general population, 21%–41% of men with primary infertility and 75%–81% of those with secondary infertility presents with this condition. Venous reflux and testicular temperature elevation appear to play important roles in varicocele-induced testicular dysfunction; although the exact pathophysiologic mechanisms involved are not yet completely understood.

Most commonly involved veins are the internal spermatic veins, but the external spermatic veins and cremasteric veins sometimes have also been implicated.^{4,5}

The surgical treatment is varicocelelectomy i.e. ligation of testicular veins along with pampiniform plexus. Improvements in semen quality after varicocele repair were first suggested by Barwell, in 1885; Bennett, in 1889; Macomber and Sanders, in 1929.^{6,7,8} Access to the veins can be gained through subinguinal, transinguinal, or suprainguinal incision. This operation can be done by open, laparoscopic, microscopic, or embolization unilaterally or bilaterally. Ligation of varicocele is known to cause marked improvement in semen parameters and also improve the fertility and conception rate.

This study has been undertaken with an idea to analyse the effect of varicocelelectomy on semen parameters and fertility status. The purpose of our study was to analyse the effect of varicocele on the semen composition characteristics by semen analysis before and after varicocelelectomy and also to assess the improvement in fertility status after surgery.

Detection Of Varicocele

Evaluation of a male patient with infertility should include a careful medical and reproductive history, physical examination, and at least two semen analyses.⁹ The physical examination should be performed with the patient in both the upright and recumbent positions. A palpable varicocele feels like a “bag of worms” and disappears or is very significantly reduced when the patient is recumbent. When a suspected varicocele is not clearly palpable, the scrotum should be examined while the patient performs a Valsalva maneuver in a standing position. Varicoceles are typically graded on a scale of 1 to 3, with grade 3 being present on visual inspection of the scrotum, grade 2 being easily palpable, and grade 1 only being palpable with Valsalva maneuver.¹⁰

Scrotal Ultrasound: High frequency ultrasound of the scrotum has become a mainstay in the evaluation of testicular & scrotal lesions. Recently, Scrotal Colour Doppler has been used to investigate varicoceles. Diagnostic criteria that define a varicocele vary widely, a pampiniform venous diameter > 3 mm is considered abnormal.⁹

Spermatic venography may be useful to demonstrate the anatomic position of refluxing spermatic veins that recur or persist after varicocele repair.

II. Materials & Methods

The study was done on 50 patients with varicocele with infertility prospectively from November 2017 to August 2019. These patients underwent varicocelectomy at our hospital. The study was approved by the institutional ethics committee. All patients provided informed consent. Preoperative evaluation included a complete history, physical examination, and semen analysis. The presence of varicocele was diagnosed by physical examination in a temperature controlled room at over 23°C under adequate illumination. The couples with infertility history of minimum one year were included in the study. The female partner's were evaluated separately by our institutional gynaecologists. Studied parameters included age of male and female partner, type and duration of infertility, testicular volume, side and grade of varicocele, side of varicocelectomy, and time since operation. The varicocele diagnosis was categorised according to the World Health Organization grading.

Azoospermia-Absence of sperm in semen.

Oligospermia- Sperm count <15million/ml. It is of 3 types

A. Mild-Sperm count is 10-15 million/ml

B. Moderate-Sperm count is 5-10 million/ml

C. Severe-Sperm count fall between 0 to 5 million/ml

A few reports have independently found that surgical varicocele repair in men with oligospermia resulted in induction or enhancement of spermatogenesis in 40-60% of patients, thus demonstrating the benefit of performing surgery in men with oligospermia.^{11,12,13} Scrotal ultrasonography was used for testicular volume estimation.

In all these patients, preoperative semen analysis was performed using two different semen specimens, each obtained by masturbation and at least 3 weeks preoperatively. And also 3, 6, and 12 months after varicocelectomy according to the World Health Organization recommendation (2010).

Specifically the abstinence period was 2-3 days in all cases.

Sperm concentration less than or equal to 20 (106/ml), sperm motility at first hour less than or equal to 50%, and normal sperm morphology less than or equal to 30% were considered abnormal.

The spontaneous pregnancy rate was calculated at 3, 6, & 12 months after varicocelectomy.

Exclusion Criteria. We excluded patients who were above 40 years of age, patients with subclinical varicocele, and patients with normal semen analysis, Grade I varicocele, idiopathic non-obstructive azoospermia (INOA), gonadal and chromosomal abnormalities and with known female partner infertility.

Varicocele in Adolescents

Although they are rarely seen in pre-pubertal boys, most varicoceles are present by the time puberty is completed¹⁸. The management of varicoceles in adolescents is more complicated. Since many men with varicoceles do not suffer from fertility problems, it is obvious that repairing all varicoceles would represent overtreatment. However, in a proportion of adolescents, the presence of a varicocele has detrimental effects on testicular growth and can lead to irreversible testicular damage¹⁹. Thus, it is important to identify appropriate candidates for treatment. The most widely accepted indication for varicocele treatment in adolescents is a marked discrepancy in testicular volume (a >20% discrepancy in testicular volume is usually considered to be significant).

Time Interval Between Varicocele Repair And Improvements In Spermatogenesis

From a practical viewpoint, assessing how soon improvements in semen parameters are seen after varicocele repair is important, especially in elderly couples. In humans, the entire spermatogenic process takes approximately 64 days¹⁴. Studies evaluating the time interval between varicocelectomy and improvements in semen parameters revealed that sperm parameters improved during the first 3 months after varicocele repair, but did not show further improvements thereafter^{15,16}. Correspondingly, the American Society for Reproductive Medicine Practice Committee has stated that improvements in semen parameters are typically seen after 3 to 6 months¹⁷. These findings are useful for designing therapeutic strategies for candidates for varicocelectomy and underscore the necessity of not delaying other approaches for managing infertility.

Complications:

The potential complications of surgical varicocele repair occur infrequently and are usually mild. Overall, complications may occur in 1% to 5%, based on the approach used. All approaches to varicocele surgery are associated with a small risk of wound infection, hydrocele, persistence or recurrence of varicocele, and, rarely, testicular atrophy. Potential additional complications from an inguinal incision for varicocele repair include scrotal numbness and prolonged pain, although these are somewhat rare.

III. Observation & Results :

The median age of patients was 31 year. The average duration of infertility history was 3.6 years. Grade II varicocele was presented in 22 and Grade III in 28 patients respectively. The varicocele was noted more commonly in left sided in 43 patients out of 50 as compared to remaining 7 in right side.

There is a significant improvement in sperm motility in both grade 2 & 3 varicoceles which is upto 60 % in grade 2 and 66 % in grade 3 after 12 months.

Sperm concentration improved upto 44 million/ml in grade 2 and 41 million per ml in grade 3 varicoceles. Morphology and total sperm count also increase significantly. In grade 2 varicocele patients 27.78 % i.e. 5 out of 18 in left sided and 25% i.e. 1 out of 4 in right sided pathology were able to conceive. In grade 3 varicocele 44% i.e 11 out of 25 in left sided and 33.3% i.e 1 out of 3 in right sided were able to conceive .

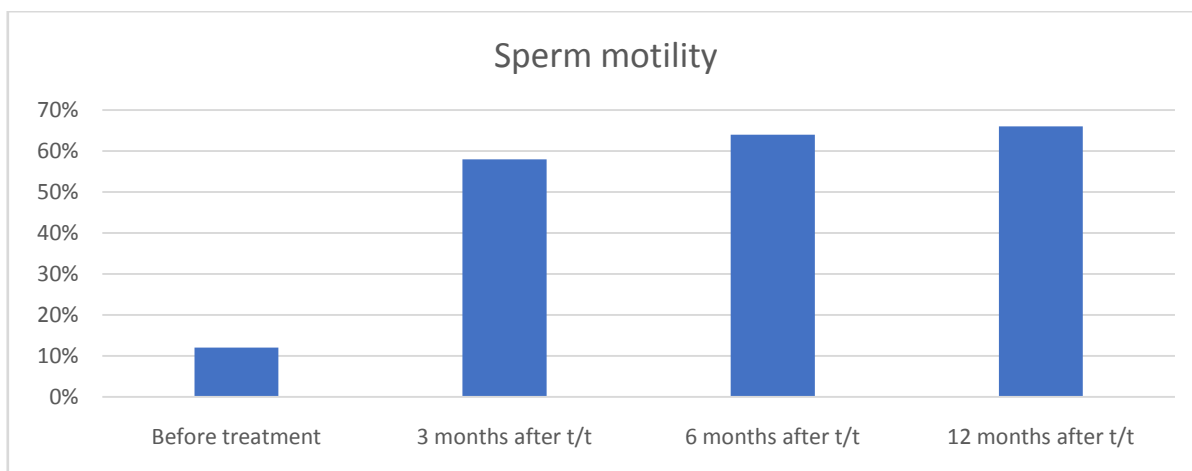
Table depicting improvement in semen parameters after surgery

(a) Sperm motility (b) Sperm concentration

	Varicocele grade	No of patients	Before treatment	After treatment		
				3	6	12 months
Sperm motility (%)	Grade II	22	20	52	56	60
	Grade III	28	12	58	64	66
Sperm Concentration (millions/mL)	Grade II	22	14	26	30	44
	Grade III	28	9	18	29	41

Graph no 2

Showing Improvement in sperm motility in Grade II Varicocele



Graph no 3
Showing Improvement in sperm motility in Grade III Varicocele

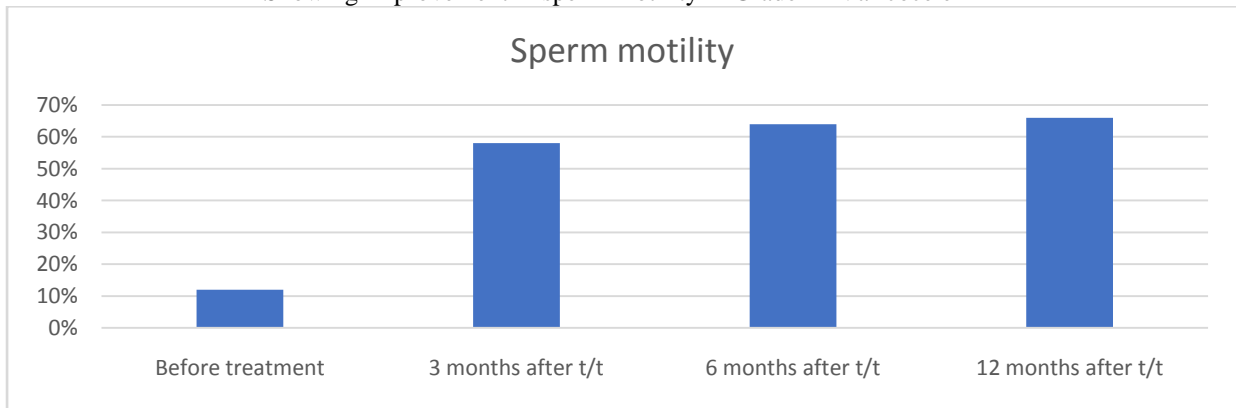


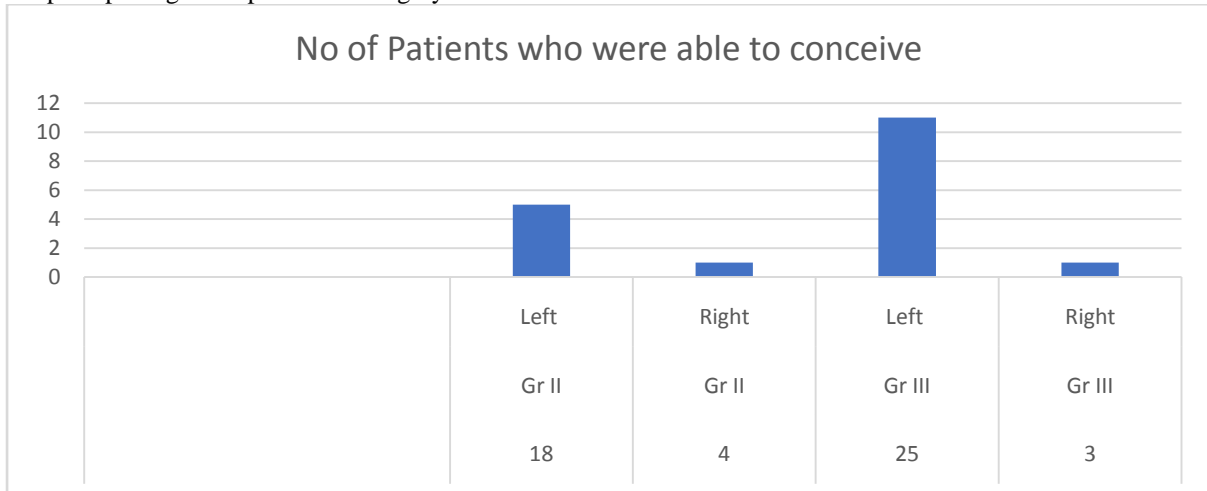
Table no 3 Showing Improvement in Semen parameters-Morphology/Total sperms

Sperm Parameters	Pre operative (Avg.)	% of improvement Non Pregnant	% of improvement Pregnant
Morphology Normal %	7.86	41.8	60.2
Total Sperm (million)	14.6	54.5	73.4

Table depicting
Varicocele grade,side,semen parameter and pregnancy rate post surgery

No of Patients	Clinical Grade of varicocele	Side of varicocele	Semen Parameter improvement with intervention	No of Patients who were able to conceive	Pregnancy Rate
18	Gr II	Left	Yes	5	27.78%
4	Gr II	Right	Yes	1	25.00%
25	Gr III	Left	Yes	11	44.00%
3	Gr III	Right	Yes	1	33.33%

Graph depicting conception after surgery –



IV. Conclusion:

Varicoceles are a common and correctable cause of male infertility. Varicocelectomy gives a statistically significant improvement in sperm concentration, motility, and overall morphology.

Treatment of a clinically palpable varicocele may be offered to the male partner of an infertile couple when there is evidence of abnormal semen parameters and minimal/no identified female factor, including consideration of age and ovarian reserve.

All approaches to varicocele (sub-inguinal, inguinal, or laparoscopic) have shown a significant improvement in seminal parameters.

Adolescents and young men not actively trying to conceive who have a varicocele and objective evidence of reduced ipsilateral testicular size may be offered varicocele repair.

On analysing the patients with successful pregnancy showed that motility is probably the most crucial factor followed by morphology in achieving fertility.

We need further studies to identify the reliable parameters based on which, varicocelectomy as a treatment modality can be suggested.

Time to improvement in semen parameters is approximately 3 to 6 months.

Conflict Of Interest

The authors declare that they have no potential conflict of interest relevant to this article.

References:

- [1]. Outcome of Varicocelectomy with Different Degrees of Clinical Varicocele in Infertile Male Hindawi Publishing Corporation;Advances in Andrology Volume 2015, Article ID 432950, 9 pages;<http://dx.doi.org/10.1155/2015/432950>
- [2]. World Health Organization, Laboratory Manual for the Examination of Human Semen and Sperm-Cervical Mucus Interaction, Cambridge University Press, New York, NY, USA, 4th edition, 1999.
- [3]. L. Speroff, R. H. Glass, and N. G. Kase, "Infertility," in Clinical Gynecological Endocrinology and Infertility, pp. 201–246, Lippincott Williams & Wilkins, Baltimore, Md, USA, 6th edition, 1999.
- [4]. Thomas AJ Jr, Geisinger MA. Current management of varicoceles. Urol Clin North Am 1990;17:893-907.
- [5]. Matthews GJ, Matthews ED, Goldstein M. Induction of spermatogenesis and achievement of pregnancy after microsurgical varicocelectomy in men with azoospermia and severe oligoasthenospermia. Fertil Steril 1998;70:71-5.
- [6]. Kamal KM, Jarvi K, Zini A. Microsurgical varicocelectomy in the era of assisted reproductive technology: Influence of initial semen quality on pregnancy rates. Fertil Steril 2001;75:1013-6.
- [7]. Goldstein M, Gilbert BR, Dicker AP, Dwosh J, Gnecco C. Microsurgical inguinal varicocelectomy with delivery of the testis: An artery and lymphatic sparing technique. J Urol 1992;148:1808-11.
- [8]. Kumar R, Gupta NP. Subinguinal microsurgical varicocelectomy: Evaluation of the results. Urol Int 2003;71:368-72 .
- [9]. Report on varicocele and infertility: a committee opinion Fertility and Sterility® Vol. 102, No. 6, December 2014 0015-0282 American Society for Reproductive Medicine, Published by Elsevier Inc. <http://dx.doi.org/10.1016/j.fertnstert.2014.10.007>.
- [10]. Schlegel PN. Is assisted reproduction the optimal treatment for varicocele associated infertility? A cost-effective analysis. Urology 1997;49:83-90.
- [11]. Matthew's GJ, Matthews ED, Goldstein M. Induction Esteves SC, Glina S. Recovery of spermatogenesis after microsurgical varicocele repair in azoospermic men is related to testicular pathology.
- [12]. Schlegel PN, Hardy MP, Goldstein M. Male reproductive physiology. In: Wein AJ, Kavoussi LR, Novick AC, Partin AW, Peters CA, editors. Campbell-Walsh urology. 9th ed. Philadelphia: Saunders; 2007;577-608.
- [13]. Al Bakri A, Lo K, Grober E, Cassidy D, Cardoso JP, Jarvi K. Time for improvement in semen parameters after varicocelectomy. J Urol 2012;187:227-31.
- [14]. Fukuda T, Miyake H, Enatsu N, Matsushita K, Fujisawa M. Assessment of time-dependent changes in semen parameters in infertile men after microsurgical varicocelectomy. Urology 2015;86:48-51.
- [15]. Practice Committee of the American Society for Reproductive Medicine; Society for Male Reproduction and Urology. Report on varicocele and infertility: a committee opinion. Fertil Steril 2014;102:1556-6.
- [16]. Steeno O, Knops J, Declerck L, Adimoelja A, van de Voorde H. Prevention of fertility disorders by detection and treatment of varicocele at school and college age. Andrologia 1976;8:47-53.
- [17]. Witt MA, Lipshultz LI. Varicocele: a progressive or static lesion? Urology 1993;42:541-3.
- [18]. World health organization, New York, USA.

Dr Ankit Goyal, et al. "Role of Varicocelectomy in Primary Male Infertility Based On Semen Parameters and Pregnancy." *IOSR Journal of Dental and Medical Sciences (IOSR-JDMS)*, 19(2), 2020, pp. 33-37.