

Radiological-Pathological Correlation In Lymph Node Involvement In Endometrial Cancer: A Study Of 96 Cases

C. Bentabet, W. Garouani, M.B. Idrissi, N. Mamouni, S. Errarhay,
C. Bouchikhi, A. Banani.

Department Of Obstetrics And Gynecology I, CHU Hassan II, Faculty Of Medicine, Pharmacy, And Dentistry,
Sidi Mohamed
Ben Abdallah University, Fez, Morocco

Abstract:

Endometrial cancer is the most common gynecological cancer in high-income countries and represents a significant portion of gynecological cancers in Morocco. This study, conducted at CHU Hassan II in Fès, analyzed 96 cases of endometrial cancer, focusing on the correlation between MRI findings and histology in detecting lymph node involvement. MRI revealed suspicious pelvic adenopathy in 22% of cases and suspicious para-aortic adenopathy in 5.2%. FIGO stages determined preoperatively via MRI were often overestimated compared to definitive histopathology. Although lymph node dissection was performed significantly (84 patients), lymph node metastases were only found in 17.85% of cases. The study highlights that MRI is valuable for preoperative staging, with 71% sensitivity and 85% specificity for detecting pelvic lymph node metastases. However, sensitivity for para-aortic metastases remains low at 33%. The findings suggest that current indications for lymph node dissection, especially in low- or intermediate-risk patients, should be reevaluated. Sentinel lymph node assessment emerges as a more suitable alternative, minimizing postoperative complications.

Keywords: Endometrial cancer, MRI, lymph node involvement, lymph node metastases, lymphadenectomy, FIGO, sentinel lymph node, pelvic lymphadenopathy, para-aortic lymphadenopathy, tumor staging.

Date of Submission: 16-01-2025

Date of Acceptance: 26-01-2025

I. Introduction

Endometrial cancer is the most common gynecological cancer in high-income countries [1]. According to Globocan 2020, in Morocco, endometrial cancer ranks as the 4th most common gynecological cancer and the 8th most common cancer among women. Its incidence is increasing by approximately 1 to 2% annually [2].

Patient age, degree of myometrial invasion, stage, grade, and histological type are the main prognostic factors for endometrial cancer [3]. Lymph node involvement is the most frequent form of extra-uterine spread in endometrial cancer and is considered a significant predictor of recurrence and an important prognostic factor [4].

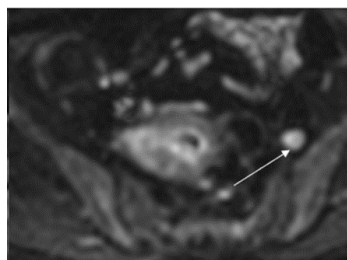
Due to its excellent contrast resolution, MRI is one of the most effective imaging modalities for detecting pelvic and/or para-aortic lymph node involvement [5,6].

Our study focuses on the radiological and histological correlation of lymph node involvement in endometrial cancer, based on 96 cases managed in the Gynecology and Obstetrics Department I at CHU Hassan II in Fez, between January 1, 2017, and June 1, 2022.

II. Results

Among the 96 patients, we were able to retrieve 81 MRI reports, with the following results:

Regarding lymph node status, MRI identified suspicious pelvic lymphadenopathy in 21 patients (22%) and suspicious para-aortic lymphadenopathy in 5 patients (approximately 5.2%).



Characterization of a left external iliac lymph node with restricted diffusion.

Endometrial cancers are classified according to the 2023 revised International Federation of Gynecology and Obstetrics (FIGO) classification. This is a clinico-pathological system that takes into account the histopathology of the surgical specimen. However, the preoperative FIGO staging, based on clinical examination and imaging, helps predict the prognostic score and guide therapeutic decisions. In our series, approximately half of the patients were classified as stage I in tumor progression, representing 46.6%. Stage III ranked second with 30.9%, followed by stage II at 12.4%. Lastly, only 9.3% of our patients were classified as stage IV.

Stade		Effectif	Pourcentage
I 45 patientes	IA	24	25%
	IB	21	21,87%
II		12	12,5%
III 30 patientes	IIIA	7	7,29%
	IIIB	3	3,12%
	IIIC ₁	12	12,5%
	IIIC ₂	8	8,33%
IV 9 patientes	IVA	1	1,04%
	IVB	8	8,33%

Distribution of our patients according to the 2023 FIGO classification.

Lymph node involvement was predicted preoperatively in 20 patients: 12 patients were classified as IIIC1, and 8 patients as IIIC2. Lymph node status is a major prognostic factor as well as a decision-making criterion for adjuvant treatment, making lymph node exploration an essential step in management. Lymphadenectomy (all types combined) was performed in 84 patients. Right pelvic lymphadenectomy was done in 84 patients, representing 87.5%. Left pelvic lymphadenectomy was performed in 81 patients, representing 4.4%. Lombo-aortic lymphadenectomy was done in 41 patients, representing 42.7%. Right pelvic lymphadenectomy yielded > 6 lymph nodes in 73.5% of cases. Left pelvic lymphadenectomy yielded > 6 lymph nodes (considered significant) in 63.7% of cases. Lombo-aortic lymphadenectomy yielded > 8 lymph nodes (considered significant) in 70% of cases. Performing lymphadenectomy requires a minimum number of lymph nodes to be collected to obtain a meaningful representation of the lymphatic area. This constraint increases the invasiveness of the procedure; reoperation for additional lymphadenectomy in a fragile and altered area is complex and should be avoided as much as possible. Currently, there is no consensus on the minimal number of lymph nodes or the topography of the specimen.

Regarding lombo-aortic lymph node staging, picking has no place. Indeed, it exposes patients to the same operative risks, as it requires the same anatomical exposure. Furthermore, only 10% of invaded lymph nodes show increased volume, and 50% of lymph node metastases are microscopic [7].

Séries	Nombre de patientes	Nombre de ganglions pelviens	Nombre de ganglions para-aortiques
Köhler [264] inclus Possover [265]	650	18,8 (2-52)	10,8 (1-52)
Abu-Rustum [266]	114	10,3 (1-39)	5,3 (à-21)
Altgassen [267]	108	24,3 - 21	5,1 - 10,6
Scribner [268]	103	23,2	6,8
Dottino [269]	94	11,9	3,7
Vidauretta [270]	84	18,5	-
Spirtos [271]	84	23,8	10,3
Childers [272]	64	Non précisé	Non précisé
G. Cartron et al. [202]	708	17,5 (5-51)	20 (3-38)
Notre série	96	16,59 (0-31)	10,4 (0-21)

The number of lymph nodes collected in several large studies [8].

Regarding our study, our results align with those in the literature. For lymphadenectomy outcomes, our results are consistent with the data from the literature, with 17.85% of patients presenting with lymph node metastases.

Série	% des métastases ganglionnaires
Belhaddad e al. [138]	21,87%
Gilda et al. [252]	13%
Rahaouda et al. [253]	22%
Notre série	17,85%

Pourcentage des métastases ganglionnaires

In our study, compared to the study by Park et al. (9), MRI showed a slightly increased sensitivity for detecting para-aortic lymph node metastases: 33% versus 14.3%. Its sensitivity and specificity for detecting pelvic lymph node metastases align with the results found in Park's study.

	Ganglions para-aortiques		Ganglions pelviens		Tous ganglions confondus	
	Sensibilité	Spécificité	Sensibilité	Spécificité	Sensibilité	Spécificité
Park et al. (9)	14,3%	91,7%	83,3%	87%	46,2%	87,9%
Notre série	33%	80%	71%	85%	86%	82%

Sensitivity and specificity of MRI for the detection of lymph node metastases.

After the results of the postoperative histopathology, 24 tumors were reclassified, representing 25% of cases. The FIGO stage was underestimated in 14 tumors, which advanced by one or more stages after the final histopathological results. For the remaining 10 tumors, their stage was overestimated. The following table compares the number of cases for each stage before and after surgery:

Stade	Prédiction du stade FIGO en préopératoire	Stade FIGO définitif
IA ↓	24	23
IB ↑	21	24
II ↓	12	10
IIIA ↓	7	5
IIIB ↓	3	2
IIIC1 ↓	12	9
IIIC2	8	8
IVA ↓	1	0
IVB ↑	8	15

Comparison of the 2023 FIGO classification preoperatively and postoperatively.

Based on these data, it can be said that, generally, there is a tendency to overestimate the FIGO stage, particularly for stages II and III.

III. Conclusion:

Endometrial cancer is generally an endometrioid adenocarcinoma. It primarily presents with postmenopausal metrorrhagia. We based our staging of these tumors on MRI data, which had a sensitivity of 71% and a specificity of 85% for detecting pelvic lymph node metastases. However, its sensitivity for lombo-aortic lymph node metastases was 33%, with a specificity of 80%.

Radiology tended to overestimate lymph node involvement. Indeed, lymphadenectomy performed on patients with low, intermediate, and high-intermediate risk revealed no lymph node metastases. These results prompt us to reconsider our indications for lymphadenectomy, given that patients with low, intermediate, and high-intermediate risk did not present any lymph node metastases. Moreover, lymphadenectomy in this category only increased morbidity and mortality. The application of the latest recommendations, particularly the use of sentinel lymph nodes for low and intermediate-risk patients, thus seems more logical and beneficial for patients.

References:

- [1] Crosbie EJ, Kitson SJ, Mcalpine JN, Mukhopadhyay A, Powell ME, Singh N. Endometrial Cancer. *Lancet*. 2022 Apr 9;399(10333):1412-1428. Doi: 10.1016/S0140-6736(22)00323-3. PMID: 35397864.
- [2] Daniilidis A, Margioulas-Siarkou C, Margioulas-Siarkou G, Papandreou P, Papanikolaou A, Dinas K, Petousis S. Sentinel Lymph Node Mapping In Endometrial Cancer To Reduce Surgical Morbidity: Always, Sometimes, Or Never. *Prz Menopauzalny*. 2022 Sep;21(3):207-213. Doi: 10.5114/Pm.2022.119862. Epub 2022 Oct 1. PMID: 36254127; PMCID: PMC9551362.
- [3] Brüggmann D, Ouassou K, Klingelhöfer D, Et Al. Endometrial Cancer: Mapping The Global Landscape Of Research. *J Transl Med* 2020; 18: 386
- [4] Toptaş T, Şimşek T, Karaveli Ş. Prognostic Risk Factors For Lymph Node Involvement In Patients With Endometrial Cancer. *Turkish J Obstet Gynecol* 2017;
- [5] F. Machado, J. Moreno, M. Carazo, J. León, G. Fiol, Et R. Serna, « Accuracy Of Endometrial Biopsy With The Cornier Pipelle For Diagnosis Of Endometrial Cancer And Atypical Hyperplasia », *Eur. J. Gynaecol. Oncol.*, Vol. 24, N O 3 4, P. 279 281, 2003.
- [6] A. Di Spiezo Sardo Et Al., « Should Endometrial Biopsy Under Direct Hysteroscopic Visualization Using The Grasp Technique Become The New Gold Standard For The Preoperative Evaluation Of The Patient With Endometrial
- [7] Mariani A, Webb MJ, Keeney GL, Haddock MG, Calori G, Podratz KC. Low-Risk Corpus Cancer: Is Lymphadenectomy Or Radiotherapy Necessary ? *Am J Obstet Gynecol* 2000;182: 1506–19.
- [8] Orton J. Adjuvant External Beam Radiotherapy (EBRT) In The Treatment Of Endometrial Cancer: Results Of The Randomised MRC ASTEC And NCIC CTG EN.5 Trial. *J Clin Oncol* 2007;25
- [9] Park J-Y., Kim EN., Kim D-Y., Suh D-S., Kim J-H., Kim Y-M., Et Al. Comparison Of The Validity Of Magnetic Resonance Imaging And Positron Emission Tomography/Computed Tomography In The Preoperative Evaluation Of Patients With Uterine Corpus Cancer. *Gynecol Oncol* 2008, 108 : 486-49