

"The Forgotten Zone: How Neutral Zone Techniques Improve Complete Denture Success: A Case Report"

Author

Abstract:

Residual ridge resorption (RRR) is progressive, irreversible, and cumulative condition that poses significant challenges in the fabrication and functionality of complete dentures. This process leads to the loss of sulcular depth, vertical dimension, and decreased lower facial height, adversely affecting denture stability and patient comfort. The consequences of mandibular ridge resorption on denture performance include: Loss of Retention and Stability and Neuromuscular Challenges. Mandibular ridge resorption presents significant challenges in complete denture fabrication and function. A comprehensive understanding of the multifactorial etiology, combined with appropriate clinical techniques such as the neutral zone approach and consideration of implant-supported solutions, can enhance denture stability and patient comfort. The neutral zone concept plays a significant role in overcoming these challenges. The neutral zone is the area where the outward forces from the tongue are neutralized or nullified by the forces of the lips and cheeks acting inward during functional movements. It is most effective for dentures where there is a highly atrophic ridge and history of denture instability. The technique aims to construct a denture that is shaped by muscle function and is in harmony with the surrounding oral structures. This article discusses the use of addition silicone impression material to create index which is helpful in fabricating functionally stable and retentive mandibular complete denture.

Date of Submission: 12-02-2025

Date of Acceptance: 22-02-2025

I. Introduction:

Sir Wilfred Fish first described the influence of the polished surfaces on retention and stability in 1931. He also described how dentures should be constructed in the 'dead space', which later became known as the neutral zone.⁽¹⁾ The Neutral zone is the potential space between the lips and cheeks on one side and the tongue on the other; that area or position where the forces between the tongue and cheeks or lips are equal.⁽²⁾ The goal of this technique is to place the teeth such that the forces exerted by the tongue and the cheek muscles are nullified, and the teeth remain in a safe, protected zone. Traditionally, the arrangement of teeth is based on the principles of teeth setting. However, in the neutral zone technique, the placement of teeth is dictated by the oral musculature that varies from one patient to another.⁽³⁾ Various materials like tissue conditioners, Impression compound, Waxes, Impression plaster have been advocated to record neutral zone which has their own advantages as well as disadvantages.⁽⁴⁾ Neutral zone is also known as dead zone, stable zone, zone of minimal conflict, zone of equilibrium, zone of least interference, biometric denture space, denture space and potential denture space. (fig 1)⁽⁵⁾

The neutral zone is that area in the mouth where, during function, the forces of the tongue pressing outward are neutralized by the forces of the cheeks and lips pressing inward. Since these forces are developed through muscles contraction during the various functions of chewing, swallowing and speaking, they vary in magnitude and direction in different individuals and in different periods of life. The way these forces are directed against the dentures will either help to stabilize them or will tend to dislodge them.⁽⁵⁾

As the surface area of the impression surface decreases and the external surface area increases, the contour of the external surface becomes critical. The polished denture surfaces must align with the tongue and cheek muscles, with the upper denture inclined inward and downward and the lower inward and upward. External forces vary during swallowing, speaking, and chewing, remaining constant only when the mouth is at rest. If teeth were always in contact, the external surface would be less important for stability, while the reverse is true if teeth rarely contact. Teeth meet mainly during mastication and swallowing, but lips, cheeks, and tongue are in constant function, emphasizing the horizontal forces they exert. Artificial teeth should be positioned relative to musculature, adapting for age, tonus, ridge resorption, and changes in the neutral zone.⁽⁵⁾ A denture shaped by the neutral zone technique will ensure that the muscular forces are working more effectively and in harmony. The dentures will have other advantages: ⁽¹⁾

- Improved stability and retention
 - Posterior teeth will be correctly positioned allowing sufficient tongue space
 - Reduced food trapping adjacent to the molar teeth
-

- Good aesthetics due to facial support.

II. Case Report:

A 60-year-old man reported to the Department of Prosthodontics reported with the chief complaint of an unstable loose mandibular denture. The medical history of the patient revealed no relevant history. The patient presented with no history of neuromuscular in-coordination. He complained of difficulty moving his jaws with complete denture for the past two years, leading to difficulty in chewing and speech, primarily due to loose lower dentures. On clinical examination, the maxillary residual alveolar ridge was rounded and well formed, but the mandibular residual ridge was unfavorable due to a high degree of resorption (classified as Atwood's Order V : low and well-rounded) (fig 1).

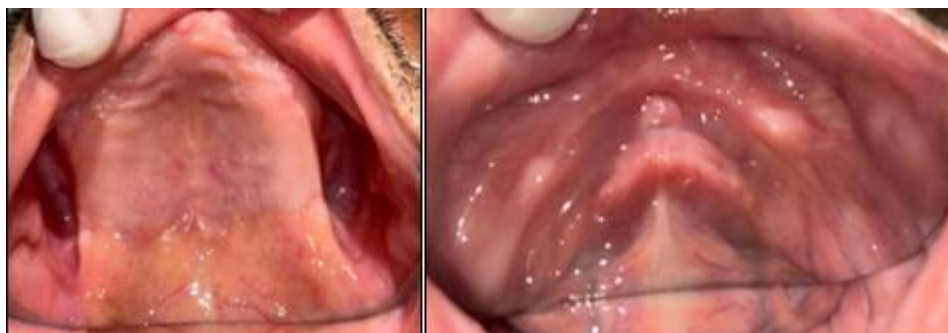

FIGURE 1

The treatment approach for this patient was to construct a mandibular denture using the neutral zone technique and to use improvised procedures to minimize the chair-side visits for the patient.

Objective Of The Treatment:

The objectives of the treatment are rehabilitation with complete denture therapy in a patient using an improvised neutral zone technique to achieve maximum prosthesis stability, comfort, and function; locating the neutral zone and arranging the denture teeth accordingly; and minimizing the ongoing diminution of the residual alveolar ridges. Figure 2 reveals an orthopantomograph of a resorbed mandibular arch.

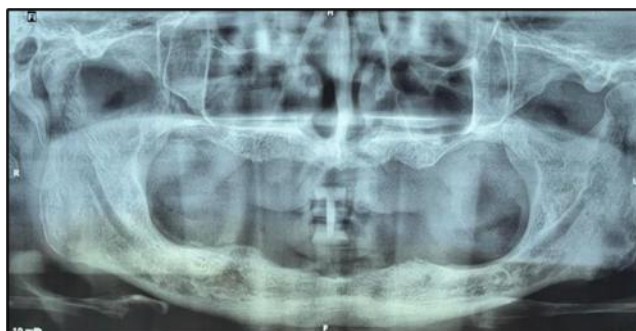

FIGURE 2

STEP 1:

- During the patient's first visit, a preliminary impression of the maxillary and mandibular edentulous residual ridges was made with Impression compound (DPI - Pinnacle Impression Compound, The Bombay Burmah Trading Corporation, Ltd., Mumbai, India) (fig 3).

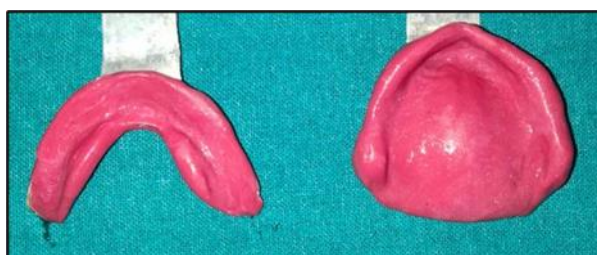

FIGURE 3

- The impressions were immediately cast in dental plaster (DPI Dental Products of India - The Bombay Burmah Trading Corporation, Ltd., Mumbai, India) and primary casts were prepared.
- Custom trays were fabricated with (DPI Dental Products of India) - RR cold cure acrylic material (Bombay Burmah Trading Corporation, Ltd., Mumbai, India).
- On the next day, border molding was done with admix material – three parts by weight of impression compound and seven parts by weight of tracing compound (DPI - Pinnacle Impression Compound and Tracing Sticks, The Bombay Burmah Trading Corporation, Ltd., Mumbai, India). The secondary impression was also made with the admix material (fig 4).

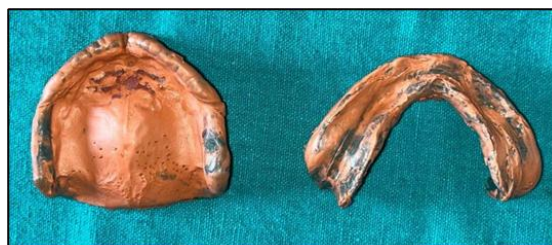

FIGURE 4

- The master casts were poured in dental stone (DPI Dental Products of India - The Bombay Burmah Trading Corporation, Ltd., Mumbai, India) and record bases were constructed with self-cure acrylic resin for the maxillary and mandibular cast. The wax occlusal rim was fabricated for the maxillary arch. A record base over the mandibular cast was fabricated with self-cure acrylic pillars.

STEP 2:

- The maxillary occlusal rim was inserted and parallelism was verified using the Fox plane.
- The mandibular record base was also placed in the patient's mouth and checked for extension and stability by guiding the patient to perform mandibular movements. Once the mandibular record base was stabilized, the vertical jaw relation was determined with the help of self-cure acrylic resin vertical stops (3 mm × 8 mm) placed on either side of the mandibular canine-premolar region.
- The vertical and horizontal jaw relation was recorded.
- The resin vertical stops were fabricated and verified with the maxillomandibular jaw relation. 22 gauge stainless steel wire in the shape of alternating rectangles was placed from one vertical stop to other as shown in the figure 5. It was used to support the impression compound that will be used to make impression of the neutral zone.

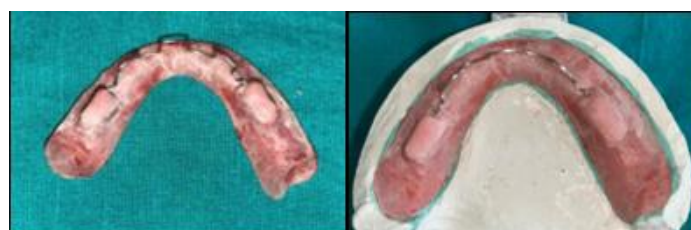

FIGURE 5

STEP 3:

- Place the mandibular denture base in the patients mouth and impression is made with impression compound.
- The patient was instructed to perform routine mandibular movements (including swallowing, sucking of the lips, and pronouncing the vowels), which aided in molding the neutral zone space (fig 6).

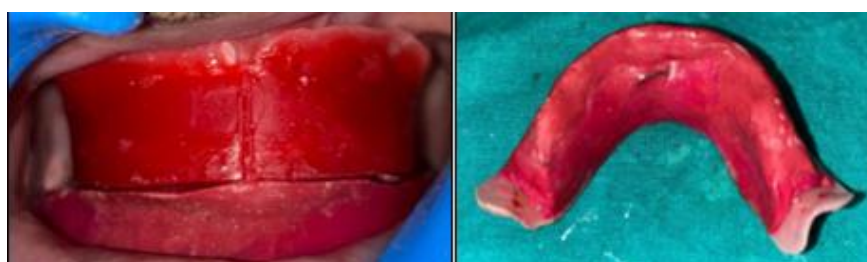


FIGURE 6

- The external surface was completely contoured by the orofacial musculature. The maxillary and the mandibular rims were fused at the centric relation. The maxillary and mandibular occlusal rims were articulated in a mean value articulator to fabricate indices surrounding the neutral zone compound impression on the mandibular cast.

STEP 4:

- Three notches were made on the cast: one in the anterior and two in the posterior regions.
- This was followed by applying separating medium on the cast, the record base, and over the neutral zone record.
- The Addition silicone elastomeric impression material (putty consistency) indices were made. The indices were sectioned into a labial and buccal index and a lingual index in order to guide the removal and placement of these indices.
- The neutral zone record is then removed, and the acrylic stops are trimmed off from the denture base. Wax was poured in the space surrounding the index, representing the neutral zone, forming the new occlusal rim on the mandibular record base. Figure 7 shows the occlusal rim created and the putty index.

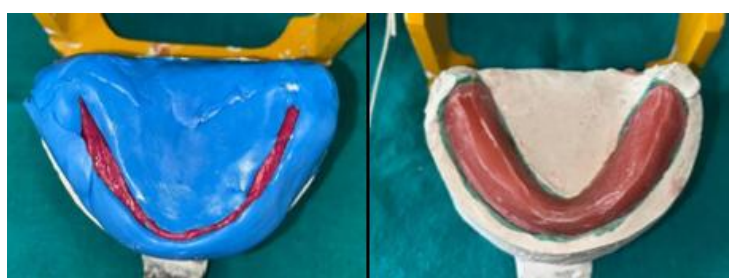


FIGURE 7

STEP 5:

- The mandibular teeth were arranged following the index, and the maxillary teeth were arranged following the mandibular teeth arrangement.
- In order to preserve the contours established by the plaster indices in the neutral zone, no additional wax added to the denture flanges.
- Since the patient showed no relevant medical history and the neuromuscular inc-ordination was not found, so we decided to use semi-anatomic teeth in place of monoplaner teeth.
- A wax try-in was performed to evaluate mandibular record base stability, aesthetics, and intraoral occlusion. The patient successfully performed all the movements mentioned earlier.
- The teeth arranged were verified with the help of addition silicone elastomeric impression material (putty consistency) index. (fig 8).
- The trial dentures were processed with heat-cure acrylic resin. The denture was polished so that the customized contours remained unaltered.

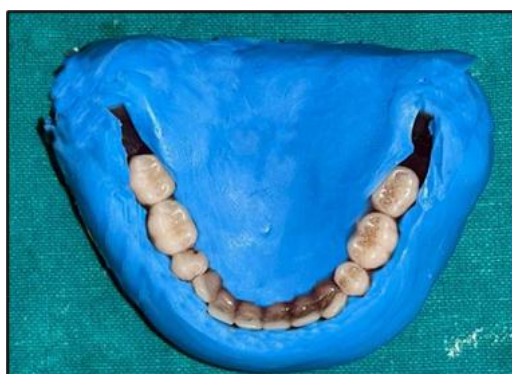

FIGURE 8

- The denture was inserted and verified for retention, stability, and occlusion. The patient was comfortable with the complete denture prosthesis. Periodic recall visits were scheduled to verify the retention, comfort, and function. (fig 9)
- Patient was scheduled for follow-up visits at intervals of 1 week, 1 month and 3 months. And as per our observations the results were satisfactory.

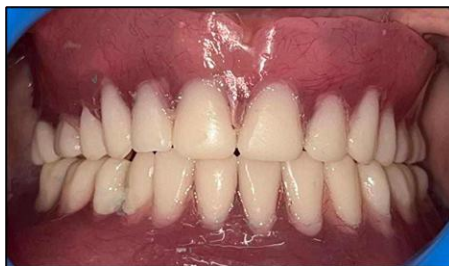

FIGURE 9

III. Discussion:

Creating a stable prosthesis is considered the utmost aim in clinical practice. The restoration of masticatory function and aesthetics is recognized as both satisfying and rewarding, particularly in cases involving severe bone resorption. However, the process is acknowledged as challenging, requiring meticulous attention to detail and strict adherence to established protocols. ⁽⁷⁾ The neutral-zone philosophy is based upon the concept that for each individual patient, there exists within the denture space a specific area where the function of the musculature will not unseat the denture and where forces generated by the tongue are neutralized by the forces generated by the lips and cheeks.⁽⁸⁾

By positioning the denture within this zone, the prevention of displacement caused by an imbalance between lingual and vestibular forces is achieved. Consequently, the exact placement of teeth on the crest of the residual alveolar ridge is not always possible to ensure denture stability. The appropriate positioning of teeth is determined by the equilibrium of opposing muscle pressures. Therefore, tooth placement should not rely solely on static principles; due consideration must be given to the dynamic forces present within the denture space.⁽⁹⁾ The technique provides for the construction of an ideal lower denture and the opposing upper denture is made to conform to it. ⁽¹⁰⁾

IV. Conclusion:

The neutral zone technique for denture fabrication is taken advantage of the stabilizing potential of surrounded soft tissues, instead of being dislodged by them. Retention and stability of dentures are improved, especially in the severely atrophic ridges. When patients cannot undergo an implant overdenture therapy, an alternative, time-saving, and relatively simple way to obtain a favorable result is provided by this article. This technique might be time taking and add additional steps in laboratory procedure, but the results showed better retention and stability of the mandibular denture when compared with denture fabricated with conventional method. Various materials have been recommended by different authors for recording neutral zone. The impression materials that are used in the neutral zone impression technique are modeling plastic impression compound, soft wax, silicone, polyvinylsiloxane, tissue conditioner, and polyether.⁽¹²⁾

Using PVS addition silicone putty consistency impression material to create an index offers several advantages, including ease of use, dimensional stability, biocompatibility, and easy retrieval from the cast. The putty index is resistant to breaking or tearing and can be repeatedly repositioned to verify the placement of teeth on the lower denture.

References:

- [1] Fish E W. An Analysis Of The Stabilising Factors In Full Denture Construction. Br Dent J 1931; 52: 559–570.
- [2] The Glossary Of Prosthodontic Terms Of 2023. 10th Edition
- [3] Saravanakumar P, Thirumalai Thangarajan S, Mani U, Et Al. Improvised Neutral Zone Technique In A Completely Edentulous Patient With An Atrophic Mandibular Ridge And Neuromuscular Incoordination: A Clinical Tip .2017, Cureus 9(4): E1189.
- [4] Agarwal S,Gangadhar P, Ahmad N, Bhardwaj A.A Simplified Approach For Recording Neutral Zone.J Indian Prosthodont Soc (Apr-June 2010) 10(2):102–104.
- [5] Srivastava V, Gupta NK, Tandan A, Kaira LS, Chopra D. The Neutral Zone: Concept And Technique. J Orofac Res 2012;2(1):42-47.
- [6] Gahan M.J, Walmsley A.D. The Neutral Zone Impression Revisited,British Dental Journal 2005; 198: 269–272.
- [7] Jain M. Impression Techniques For The Resorbed Mandibular Arch: A Guide To Increased Stability. J Sci Soc 2015;42:88-91.
- [8] Beresin V E, Schiesser F J. The Neutral Zone In Complete Dentures P 15. C.V. Mosby Co., 1976.
- [9] Rill, N., Tryde, G., And Cantor, R.: The Dynamic Nature Of The Lower Denture Space, J. PROSTHET. DENT. 15: 401-418, 1965.
- [10] Russell, A. F.: The Reciprocal Lower Denture, J. PROSYHET. DENT. 9: 180-190, 1959.
- [11] Lammie, G. A.: Aging Changes In The Complete Lower Denture, J. PROSTHET. DENT. 6: 450-464, 1956.
- [12] Yeh Y.L , Paw Y.H, Chen Y.Y. Neutral Zone Approach To Denture Fabrication For A Severe Mandibular Ridge Resorption Patient: Systematic Review And Modern Technique.Journal Of Dental Sciences, 2013; 8, 432-438.