

# Type 1 Dentin Dysplasia- A Rare Case Report And Review

Sindhu V<sup>1</sup>, Murali Gopika Manoharan<sup>2</sup>

(Post graduate, Oral Medicine and Radiology, TamilNadu Government Dental College and Hospital, Chennai)  
(Professor and Head of the Department, Oral Medicine and Radiology, TamilNadu Government Dental College and Hospital, Chennai)

---

## Abstract

Type I dentin dysplasia (DD-I) is a rare genetic disorder with autosomal dominant or recessive mode of inheritance. It is a rare developmental disturbance affecting dentin characterised by normal enamel and crown morphology with atypical dentin formation and abnormal pulpal morphology. Type I (radicular) and Type II (coronal) are the two forms of DD. Type I is more common, and includes single or multiple teeth in primary and permanent dentition. This case report documents one such rarity of type 1 DD in an 8 year- old female child with clinical and radiographical findings.

**Keywords:** dentin dysplasia, radicular, dentin

---

Date of Submission: 21-02-2025

Date of Acceptance: 01-03-2025

---

## I. Introduction

Dentin dysplasia (DD) is an autosomal dominant hereditary disorder of dentin formation affecting both primary and permanent dentitions. Rushton coined this term in 1939 and was first described by Balchsmiede as rootless teeth[1]. Dentin dysplasia (DD) is a rare developmental anomaly of dentin characterized by normal enamel and crown morphology with atypical dentin formation, small roots and abnormal pulp morphology. The prevalence rate of dentin dysplasia is estimated to be 1 in 100000 cases and occurs in both genders. DD can be categorized as (i) radicular and coronal DD, (ii) Type I and Type II DD and (iii) generalized (>30% affected) or localized (<30% affected). Carrol et al proposed a subclassification based on radiographic findings. Type I was subclassified into 4 subtypes: 1a, 1b, 1c and 1d [2]. Type 1 DD is characterized by short, conical, pointed roots or rootless teeth and affects both primary and permanent dentition and type II dentin dysplasia (DD-II) is characterized by primary teeth with brown or blue opalescent colour [3].

Radicular DD is clinically characterised by nearly normal appearing crowns with hypermobility of the teeth. Delayed dental eruption pattern, opaque incisal borders and premature exfoliation because of the short, blunt, tapering or even absent roots are the regular findings of radicular DD. Teeth eruption is usually unaffected and they are resistant to dental caries. Radiographic examination typically shows short, blunt and malformed roots which is an important diagnostic tool for identifying radicular DD,. The other typical findings include the obliteration of pulp chambers with crescentshaped pulpal remnants parallel to the cemento enamel junction and several periapical radiolucencies involving the noncarious teeth [1].

The genetic cause of DD-I is related to the mutation of the Dspg gene (4q21.3), which encodes dentin sialo phosphoprotein, a precursor of dentin sialoprotein and dentin phosphoprotein, which are involved in dentinogenesis [3].

Type II DD is considered to be much rarer and a definite incidence rate has not been reported so far [4]. Here we report a case of a dentin dysplasia in an 8 year old female child patient with clinical and radiographic findings.

## II. Case Report

A 8-year-old female child patient reported to the Department of Oral Medicine and Radiology with the chief complaint of missing teeth in the front and back region in both the upper and lower jaw. Patient's mother gave no history of trauma and extractions related to the missing teeth. The patient's past medical history was non-contributory. The past dental history revealed early exfoliation of deciduous teeth when the child was 3 years old and non-eruption of permanent teeth. Family history revealed consanguineous marriage between parents and no such abnormality among other family members. General examination revealed-no obvious signs of systemic illness. On extraoral examination, no abnormalities were detected (Fig.1). Intraoral examination

revealed multiple missing teeth and erupted 55, 16, 64, 65, 26, 75, 85 (Fig.2a). Crown portion of all the teeth were of normal size, morphology and colour (Fig.2b). No pathological tooth mobility was found.

Panoramic radiograph revealed presence of tooth buds 11, 14, 15, 17, 24, 25, 27, 32, 34, 35, 37, 38, 42, 43, 44, 45, 47, 48 (Fig 3). There was absence of root formation in most of the teeth. Short/incomplete or malformed roots evident in 16, 26, 36, 37, 46, 47. Apical migration of furcation was present in permanent molars and generalised obliteration of pulp chambers were present.

Based on clinical and radiological findings, the case was provisionally diagnosed-as dentin dysplasia type I with a considerable degree of progression.

Differential diagnosis of dentin dysplasia for this case includes partial manifestation of ectodermal dysplasia, non-syndromic oligodontia.

There is no definitive treatment approach for this condition which complicates the regular management of radicular DD. The early diagnosis and regular followup of DD cases by the clinicians are of paramount importance. Treatment plan was developed with the aim of preserving existing teeth, enhancing occlusion, mastication and aesthetics for these patients. The patient was advised partial denture prostheses with relief and the patient was kept under follow-up to monitor the status of eruption of permanent teeth. The possibility of endosseous implants is being considered when the patient reaches her late teens and growth is complete.

### **III. Discussion**

DD is an uncommon developmental anomaly affecting dentin, resulting in short root, mobile teeth and early exfoliation. Dentin dysplasia is rarely seen in children, with the prevalence of 1 in 100,000. There are 2 types of dentin dysplasia. Type I (radicular) dentin dysplasia affects both deciduous and permanent dentition, although the teeth are in normal morphologic appearance and colour but the teeth exhibit extreme mobility and premature exfoliation of teeth is common. Both the dentitions are affected in type II dentin dysplasia (coronal); however, the deciduous teeth exhibits bluish or amber discoloration, while the permanent dentition appears normal. Primary teeth shows total obliteration pulp chamber and thistle tube pulp configuration and pulp stones in pulp chambers are present in permanent teeth.

DD still remains a disease entity with an unexplained aetiology. It may also cause difficulties at both diagnostics and treatment stages. It is usually an autosomal dominant condition, but in our patient there was no relevant familial history, so she can be considered as a first-generation sufferer.

The routine clinical examination has shown complete normal crowns with no mobility in the maxillary and mandibular teeth. As a result of the absence of teeth, the affected patient's aesthetics and masticator function is compromised necessitating the need for prosthesis.

DD is a disturbance in dentin formation. Dentin sialoprotein (DSP) and dentin phosphoprotein (DPP), are the two non-collagenous dentin matrix proteins expressed by odontoblasts and transiently by ameloblasts. These proteins are responsible for initiation and control of mineralization in conversion of predentin to dentin. DSP and DPP are considered to be cleavage products encoded by dentin sialo phosphoprotein (DSPP) gene on human chromosome 4. Mutations in this gene are detected in several disorders of dentin formation process including DD and dentinogenesis imperfecta [5].

Wesley et al proposed that the condition is caused by an abnormal interaction between odontoblasts and ameloblasts leading to abnormal differentiation and function of these odontoblasts. Dentin dysplasia type I should be distinguished from dentin dysplasia type II, dentinogenesis imperfecta and odontodysplasia. In our patients, the constricted pulp chambers and multiple rootless teeth are characteristic findings for the diagnosis of DD type I [6].

The diagnosis of DD-I is based on the evidence collected in radiological investigations such as orthopantomography (abnormal roots, pulp obliteration, partially obliterated crescent shaped pulp chamber, and rarely pulp stones). The diagnosis can be supported by molecular testing. There is a 50% chance that a person with this disease inherits it to their children. The age of the patient at the time of diagnosis is an important factor which influences the dental prognosis; however, even with an early diagnosis, the severity of dysplasia often makes it impossible to plan a conservative approach [3].

O Carroll et al proposed a criteria that in radicular DD the permanent teeth should fulfill any one of the four distinct radiographic findings [1]. The present case showed absence/incomplete roots which fulfilled the criteria proposed by O Carroll et al.

In our patient, there were no variations in the morphology of the affected teeth but reports have suggested that there are possible variations in the morphology of teeth affected by this type of dysplasia. The peri-apical radiolucent regions observed in the majority of DD patients have been histopathologically interpreted as radicular cysts; nevertheless, peri-apical granuloma has been described as the diagnosis in few cases [7].

Early diagnosis is necessary for planning and preventive measures. In our patient, preventive measures were adopted in order to retain the healthy teeth, such as control of sugar intake and adequate oral hygiene.

There is no specific treatment for this genetic condition. Overall, the suggested approaches seek to preserve the erupted teeth for as long as feasible.

Still, life expectancy of dentition is short, and the patient will need periodic adaptations in the oral prosthesis [8].

Unfortunately, in spite of the use of different treatment methods, a tooth loss frequently occurs in root dentin dysplasia patients. Then it is necessary to provide a prosthetic rehabilitation in order to restore the chewing function and improve the aesthetics of the patient's dentition.

#### **IV. Conclusion**

Dentin dysplasia (DD) is a rare developmental disorder of dentin with an autosomal dominant mode of inheritance. The goal of treating children with dentin dysplasia is to provide them with adequate preventive therapy since periodontitis and shorter roots cause early loss of teeth. So, meticulous oral hygiene measures and dietary instructions must be reinforced for the retention of teeth as long as possible. Prosthetic rehabilitation should be considered if there are multiple missing teeth in order to restore the mastication and improve the aesthetics. In this regard, dental surgeons play an important role in early diagnosis of this condition and in guiding patients in the selection of measures to prolong the retention of affected teeth.

#### **References**

- [1] Patnana AK, Chugh VK, Chugh A. An Unusual Variation Of Radicular Dentin Dysplasia: A Rare Case Report With Review Of Literature. *Indian J Dent Res* 2020;5:807-12.
- [2] Akhil Jose EJ, Palathingal P, Baby D, Thachil JM. Dentin Dysplasia Type I: A Rare Case Report. *J Oral Maxillofac Pathol* 2019;23:309.
- [3] Putrino, A.; Caputo, M.; Galeotti, A.; Marinelli, E.; Zaami, S. Type I Dentin Dysplasia: The Literature Review And Case Report Of A Family Affected By Misrecognition And Late Diagnosis. *Medicina* 2023, 59, 1477.
- [4] Daryani D, Nair GR, Naidu G. Dentin Dysplasia Type II: An Exclusive Report Of Two Cases In Siblings. *J Indian Acad Oral Med Radiol* 2017;29:132-4
- [5] Shimasadat Miri, Mahsasadat Miri<sup>2</sup>, Parisa Soltani, And Amirhossein Moaddabi, "Dentin Dysplasia Type I: A Rare Case Report And Management Protocol." *International Journal Of Dental Sciences And Research*, Vol. 5, No. 5 (2017): 122-124. Doi: 10.12691/Ijdsr-5-5-2.
- [6] Singh A, Gupta S, Yuwanati MB, Et Al. CASE REPORT Dentin Dysplasia Type I *BMJ Case Rep*. Doi:10.1136/Bcr-2013- 009403.
- [7] Toomarian Et Al.: Dentin Dysplasia Type I: A Case Report And Review Of The Literature. *Journal Of Medical Case Reports* 2010 4:1.
- [8] Carmem D V S D M, Lúcia D F A D D M, Heloisa C S S, Markelane S S, Graciela M O S ,Et Al. Dentin Dysplasia Type I- Diagnosis And Treatment: Case Report. *Adv Dent & Oral Health*. 2017; 6(1): 555676.

#### **Pictures**



Fig.1. Extraoral examination of the patient.

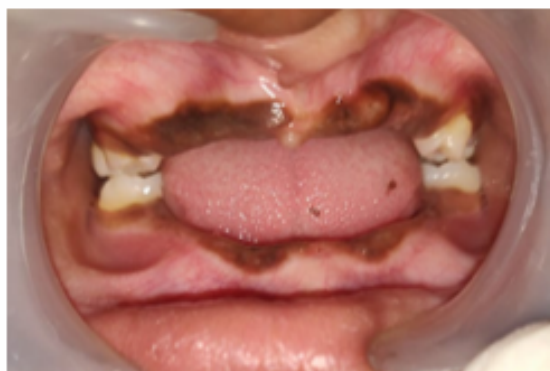

Fig.2a. Representing missing teeth and erupted 55, 16, 64, 65, 26, 75, 85

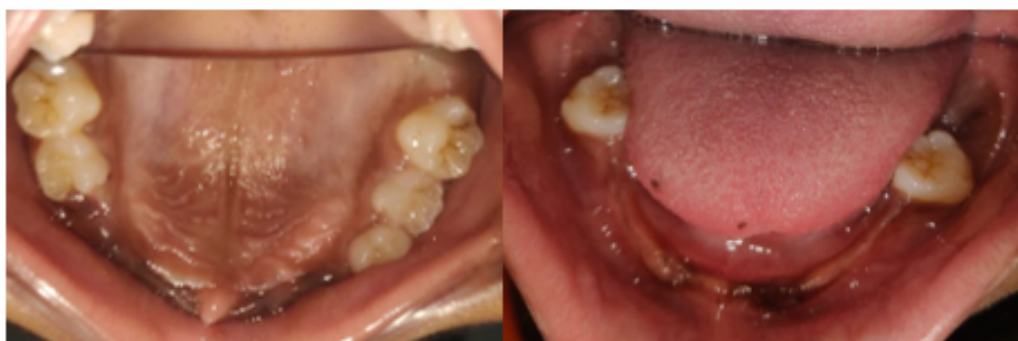

Fig.2b. Multiple missing teeth, normal crown morphology and colour

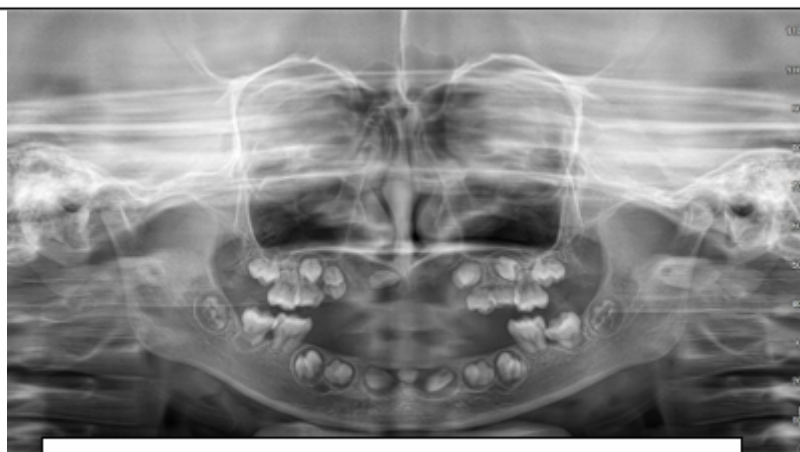


Fig.3. Presence of tooth buds 11, 14, 15, 17, 24, 25, 27, 32, 34, 35, 37, 38, 42, 43, 44, 45, 47, 48