

“Evaluation Of The Diagnostic Utility Of VELscope In Oral Candidiasis Among Denture Wearers”

Author

Abstract

Introduction- Oral candidiasis in denture wearers—commonly known as denture stomatitis—is a fungal infection predominantly caused by *Candida albicans*. It primarily affects the mucosa beneath dentures, especially in elderly or immunocompromised individuals. Traditionally, diagnosis involves clinical examination, microbial culture, and exfoliative cytology using Periodic Acid-Schiff (PAS) staining. Recently, the **VELscope**, a non-invasive, rapid screening tool, has gained attention. It utilizes tissue autofluorescence, using blue light (400–460 nm) to identify fluorophore changes in oral tissues. Abnormalities, including fungal infections, appear as areas of altered fluorescence—often yellowish or with loss of fluorescence—making detection easier than conventional white light.

Aim & Objectives- 1. To evaluate the efficacy of: i) VELscope ii) Exfoliative cytology (PAS stain) in diagnosing oral candidiasis among diabetic and non-diabetic denture wearers. 2. To compare the diagnostic efficiency of VELscope and PAS staining between the two groups.

Materials And Method- The study population included of 30 complete denture wearers, divided into two groups: Group I: Diabetic Group II: Non-diabetic. All participants underwent: 1. Clinical oral examination 2. Fluorescence screening using **VELscope**, assessing the denture-bearing mucosa and dorsum of the tongue 3. **Exfoliative cytology** using PAS staining for fungal confirmation

Results And Conclusion- both VELscope and PAS cytology demonstrated a statistically significant difference in detection of oral candidiasis between diabetic and non-diabetic groups. **VELscope p-value: 0.006 PAS stain p-value: 0.009.** VELscope proved to be a useful adjunctive tool for early identification of mucosal changes associated with fungal infection. These results suggest that both diagnostic tools are effective, with higher positivity in the diabetic group, reinforcing the importance of regular screening in vulnerable populations.

Keywords: Oral Candidiasis, Denture Stomatitis, VELscope, PAS Stain, Exfoliative Cytology, Diabetes Mellitus

Date of Submission: 25-03-2026

Date of Acceptance: 05-04-2026

I. Introduction

Candidiasis is an opportunistic fungal infection caused by *Candida* species, commonly affecting immunocompromised individuals¹. In the oral cavity, it presents in various clinical forms each with distinct features. **Pseudomembranous candidiasis** manifest as soft, white plaques on the tongue or buccal mucosa, which reveal red, inflamed mucosa when scraped². **Erythematous candidiasis**, often associated with prolonged antibiotic or steroid therapy, manifests as painful red areas, frequently with central papillary atrophy of the tongue¹. **Chronic hyperplastic candidiasis**, also called candidal leukoplakia, is characterized by firm, white plaques that may persist for years and carry premalignant potential³. Other **Candida-associated lesions** include denture stomatitis, angular cheilitis, and median rhomboid glossitis. These lesions are often exacerbated by poor oral hygiene, systemic illness, or denture use⁴. In more severe cases, **secondary forms** such as chronic mucocutaneous and endocrinopathy-associated candidiasis may develop. Prompt diagnosis and management are essential to prevent progression and complications.

Denture stomatitis is a recurrent inflammatory condition of the oral mucosa that commonly affects individuals wearing partial or complete removable dentures. It is characterized by chronic erythematous changes beneath the denture-bearing areas⁵. The prevalence varies widely, affecting approximately 11% to 67% of denture wearers, with a higher incidence in women⁴. The condition is strongly associated with the formation of **denture biofilms**, which are structurally similar to dental plaque on natural teeth. However, dentures provide a more favorable environment for **Candida** species, particularly *Candida albicans*, due to their porous surface. Poor oral hygiene and systemic factors such as **diabetes** further exacerbate the condition. *C. albicans* not only adheres to denture surfaces but also invades the mucosal tissue, increasing its virulence and contributing to the chronicity of the infection. Diagnostic aids include cytology smear using special stain as (Periodic Acid Schiff) stain PAS, microbial culture and serological tests. Recently early diagnostic aids which are quick, non-invasive and based on autofluorescence has been emerged. These include VELscope, VELscan and Vizilite, etc.

Autofluorescence refers to the natural emission of light by biological tissues when excited by specific wavelengths, usually in the ultraviolet to blue light range⁶. Unlike induced fluorescence, it does not require external stains and is produced by endogenous fluorophores. These include collagen, elastin, keratin, NADH, FAD, lipofuscin, and hemoglobin, each with unique fluorescence patterns⁷. In healthy tissues, autofluorescence appears uniform and consistent. However, in pathological conditions like inflammation, dysplasia, or malignancy, biochemical and structural changes alter these fluorophores. This results in disrupted or reduced fluorescence signals. Such changes help in distinguishing normal tissue from abnormal⁸. This principle is utilized in optical diagnostic tools like **VELscope**. It enhances visualization of oral mucosal abnormalities through real-time tissue fluorescence. Autofluorescence thus serves as a valuable, non-invasive aid in early disease detection.

The VELscope system operates on this principle of tissue autofluorescence and serves as a valuable non-invasive tool for the early detection of oral mucosal abnormalities. It works by emitting blue light in range of (400–460 nm)⁷. According to McAlpine et al⁹, four distinct autofluorescence patterns can be identified using the VELscope:

1. Normal healthy tissue shows pale green autofluorescence, which serves as a reference baseline.
2. Loss of fluorescence (LOF) appears as dark brown to black areas, typically associated with dysplastic or neoplastic changes, indicating increased malignant potential.
3. Gained fluorescence (GF) is observed as increased brightness, often seen in hyperkeratotic lesions such as leukoplakia or morsicatio buccarum.
4. Porphyrin fluorescence (PF) appears as a red-orange emission, most commonly on the dorsal tongue, caused by porphyrins—metabolic byproducts of microorganisms. PF is characterized by a peak emission at 636 nm. It may also be observed on the soft and hard palate, likely due to contact with the tongue surface.

This study is based on property of porphyrin fluorescence pattern of candida in Diabetic and non diabetic denture wearer.

II. Aims & Objectives –

To evaluate the efficacy of **i) VELscope** and **ii) exfoliative cytology (PAS stain)** in diagnosing oral candidiasis in diabetic and non-diabetic denture wearers.

To compare the efficacy of **VELscope** with **exfoliative cytology (PAS stain)** in detecting oral candidiasis in diabetic and non-diabetic denture wearers.

III. Materials And Methods

The study sample consist of 30 chronic denture wearing patients divided into two groups based on diabetes status, with following inclusion and exclusion criteria. The study population was categorized into **two groups**:

- **Group A:** Diabetic denture wearers (n = 15)
- **Group B:** Non-diabetic denture wearers (n = 15)

Prior to the commencement of the study, **approval was obtained from the Institutional Ethical Committee**, ensuring adherence to ethical research standards.

Inclusion Criteria:

Participants were selected based on the following criteria:

- Must be a **chronic complete denture wearer**
- Patients having either **upper or both upper and lower complete dentures**
- Belonged to either **diabetic and non-diabetic** groups.

Exclusion Criteria:

Subjects were excluded if they:

- Were on **immunosuppressants or corticosteroid therapy**
- Had a **recent history of antifungal treatment**
- Had **comorbid systemic conditions** other than diabetes

IV. Methodology –

All participants from both groups underwent a thorough clinical examination. A detailed case history was recorded for all 30 individuals. Based on their medical history with respect to diabetes, participants were divided into two groups: diabetic and non-diabetic, with each group comprising 15 individuals.

The clinical examination included inspection of the entire oral cavity, with particular focus on the denture-bearing areas, such as the palate, alveolar ridge, and vestibule. The dorsal surface of the tongue was also examined, as it provides a favorable environment for Candida colonization.

This was followed by an examination using the VELscope system.(fig 1) Protective precautions were taken to prevent any potential harm from the emitted light—protective eyewear was provided to all participants. A complete intraoral scan was performed under the blue light (400–460 nm) emitted by the VELscope device.

The fluorescence patterns of the tissues were carefully observed:

- Areas exhibiting a bright green fluorescence were considered normal.
- Areas displaying a yellow or yellowish-orange fluorescence were considered suspicious for Candida infection. some areas showed loss of fluorescence. Photographic record was collected for these areas. (fig 2,3)

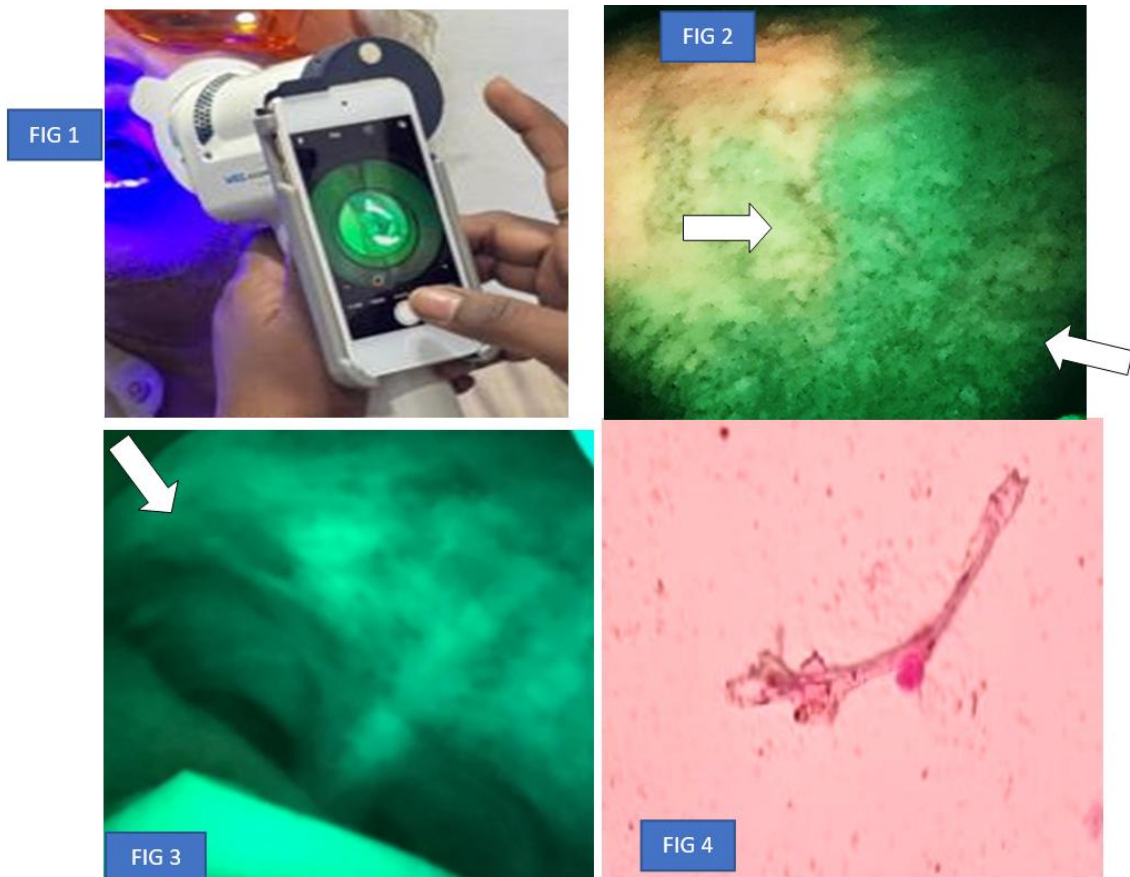


Fig 1 – Intraoral examination using VELscope. Fig 2 – Yellow fluorescence observed on the left side and normal fluorescence on the right side. Fig 3 – Area showing loss of fluorescence under VELscope. Fig 4 – PAS stain revealing fungal hyphae indicative of candidiasis.

To confirm the presence of Candida, brush cytology was performed on the suspected sites. The collected samples were stained using Periodic Acid–Schiff (PAS) stain and examined under a microscope for the presence of fungal hyphae.(fig 4)

V. Observations & Results –

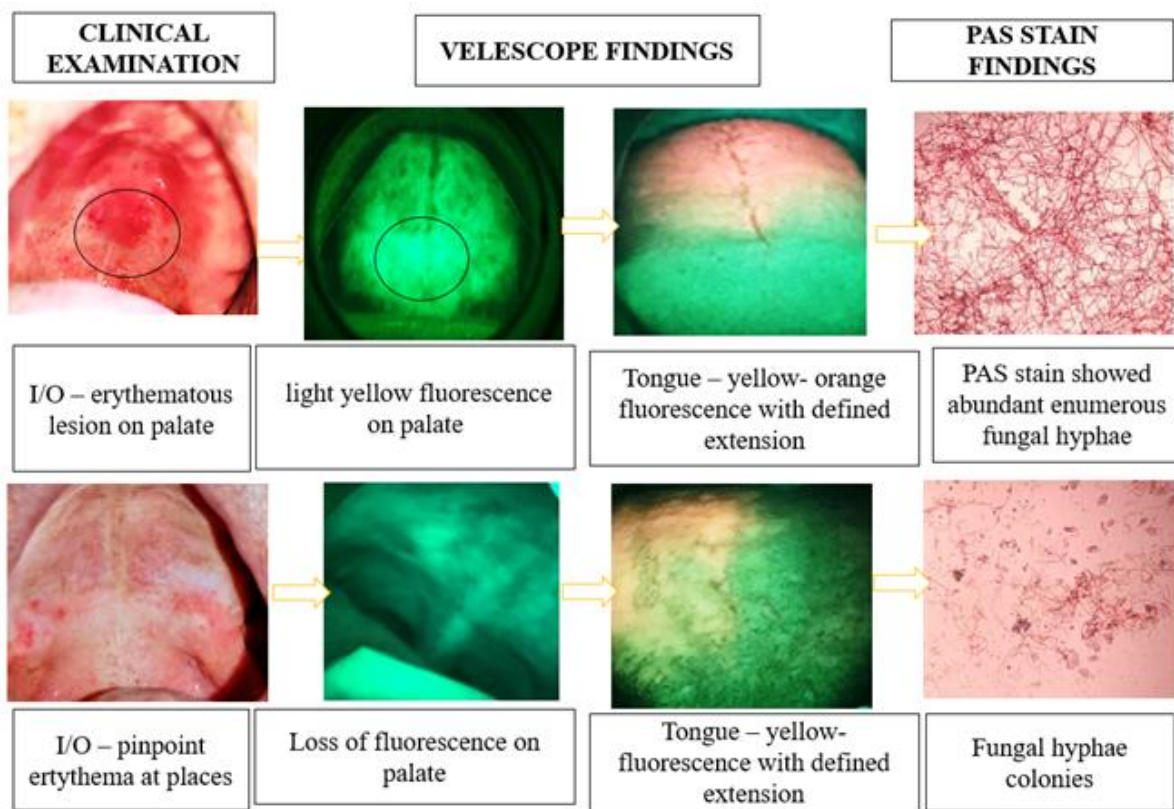


Fig 5-Group A -Diabetic denture wearer group

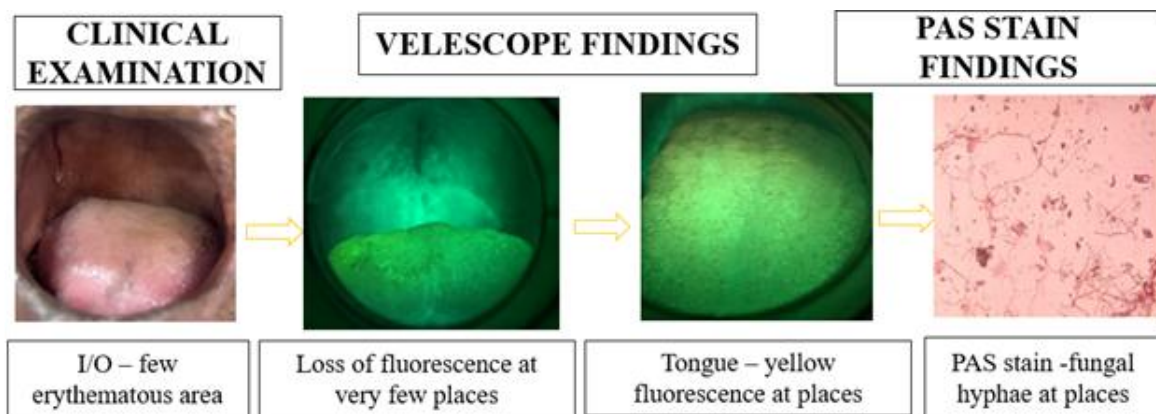


Fig 06 - Group B- Nondiabetic denture wearer group

The diabetic group (n = 15) comprised participants aged between 49 and 72 years, with a mean age of 61.33 years and a standard deviation (SD) of 8.68, indicating moderate variability. The non-diabetic group (n = 15) ranged in age from 49 to 71 years, with a mean age of 58.20 years and a SD of 6.95, reflecting slightly lower age variability compared to the diabetic group.

Under VELscope examination, a significantly higher proportion of non-diabetic participants (86.7%) exhibited no changes in fluorescence, indicating normal mucosal health. In contrast, only 33.3% of diabetic participants showed no fluorescence changes. Altered fluorescence patterns—including orange, yellowish, and loss of fluorescence—were more frequently observed in the diabetic group. Notably, **yellowish fluorescence and loss of fluorescence were observed exclusively in diabetics**. The difference in fluorescence findings between the two groups was statistically significant, with a p-value of **0.001***.

PAS staining results further supported these findings. A higher percentage of diabetic participants (73.3%) tested positive for Candida, compared to 40% in the non-diabetic group. Meanwhile, in the non-diabetics group, 60% participant showed negative PAS results, suggesting lower level of fungal colonization. Although the difference was evident, the p-value of **0.070** indicates it is **not statistically significant** at the 0.05 level, though it approaches significance and may suggest a trend worth further investigation.

“Evaluation Of The Diagnostic Utility Of VELscope In Oral Candidiasis Among Denture Wearers”

An intergroup comparison of PAS efficacy for diagnosing oral candidiasis between diabetic and non-diabetic denture wearers was conducted using the **Mann–Whitney U test**. This analysis did not reveal statistically significant differences (**p > 0.05**) in PAS results between the two groups.

Both **VELscope** and **PAS findings** showed a **statistically significant difference** between diabetic and non-diabetic groups.

The **p-values (< 0.05)** for both tests (**0.006** and **0.009**) indicate that:

- The **distribution of fluorescence patterns (VELscope)** is significantly different in diabetics vs. non-diabetics.
- The **presence of fungal hyphae (PAS positive cases)** also differs significantly between the groups.

Method of statistical analysis –

Statistical analysis was performed using Statistical package for social sciences (SPSS) software (IBM Corp) (v.21.0). Frequency and percentage statistics was performed of the different parameters in the study. Mann Whitney U test was used to assess significant differences between 2 groups. A p-value of < 0.05 was considered as statistically significant at 95% confidence intervals.

Table & Graph 1 – Descriptive statistics of Age of the study participants in different groups

Groups	N	Minimum	Maximum	Mean	Std. Deviation
Diabetic group	15	49.00	72.00	61.33	8.682
Non-Diabetic group	15	49.00	71.00	58.20	6.950

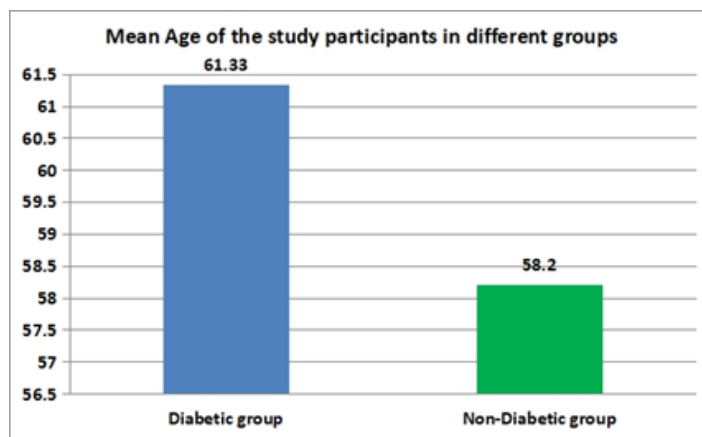


Table & Graph 2 – Frequency distribution of the study participants according to Gender in different groups

Gender	Diabetic group		Non-Diabetic group	
	Frequency (n)	Percent (%)	Frequency (n)	Percent (%)
Male	12	80.0	11	73.3
Female	3	20.0	4	26.7
Total	15	100.0	15	100.0

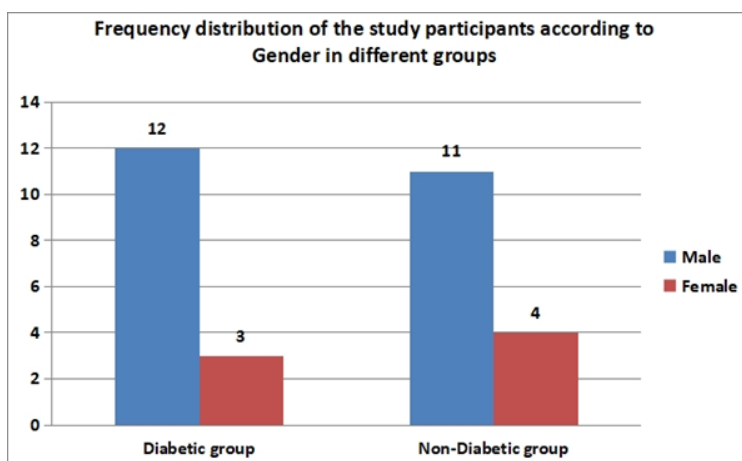


Table & Graph 3 - Intergroup comparison of efficacy of VELscope for diagnosing oral candidiasis in diabetic and non-diabetic denture wearers

VELscope -findings	Diabetic group		Non-Diabetic group		p value
	Frequency (n)	Percent (%)	Frequency (n)	Percent (%)	
No changes in fluorescence	5	33.3	13	86.7	0.001*
Orange fluorescence	2	13.3	2	13.3	
Yellowish fluorescence	4	26.7	0	0	
Loss of fluorescence	4	26.7	0	0	
Total	15	100.0	15	100.0	

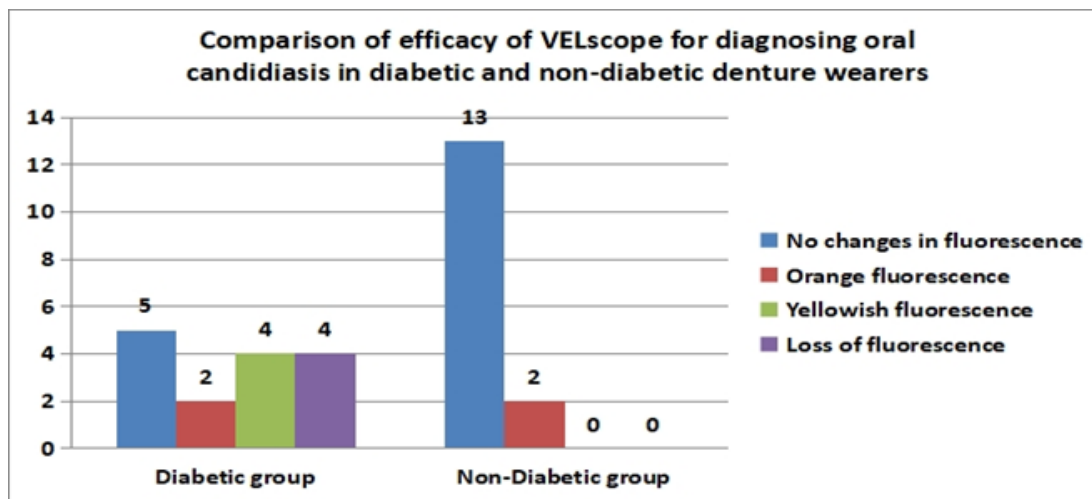


Table & Graph 4 - Intergroup comparison of efficacy of PAS for diagnosing oral candidiasis in diabetic and non-diabetic denture wearer.

PAS	Diabetic group		Non-Diabetic group		p value
	Frequency (n)	Percent (%)	Frequency (n)	Percent (%)	
Positive for Fungal hyphae	11	73.3	6	40.0	0.070
Negative for fungal hyphae	4	26.7	9	60.0	
Total	15	100.0	15	100.0	

*p value <0.05 statistically significant, <0.01 highly significant, <0.001 very highly significant

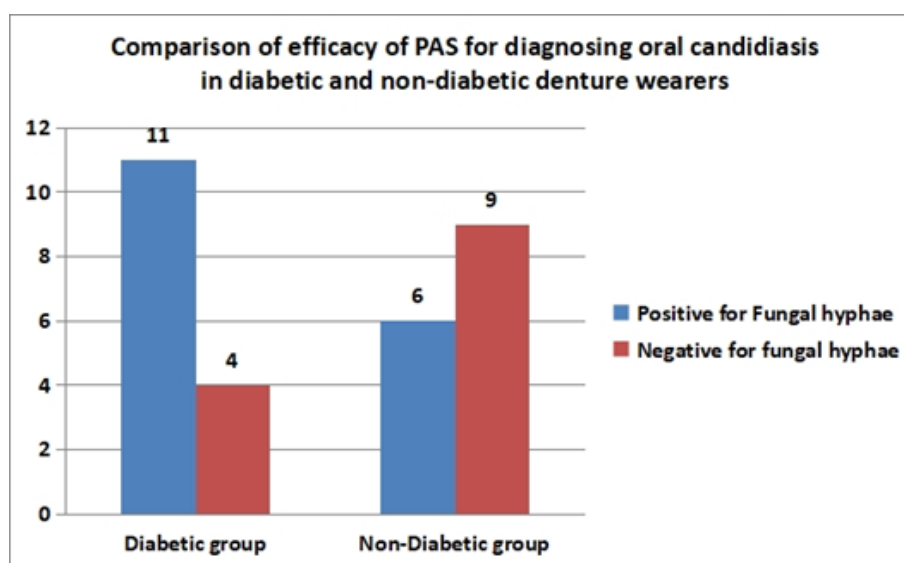
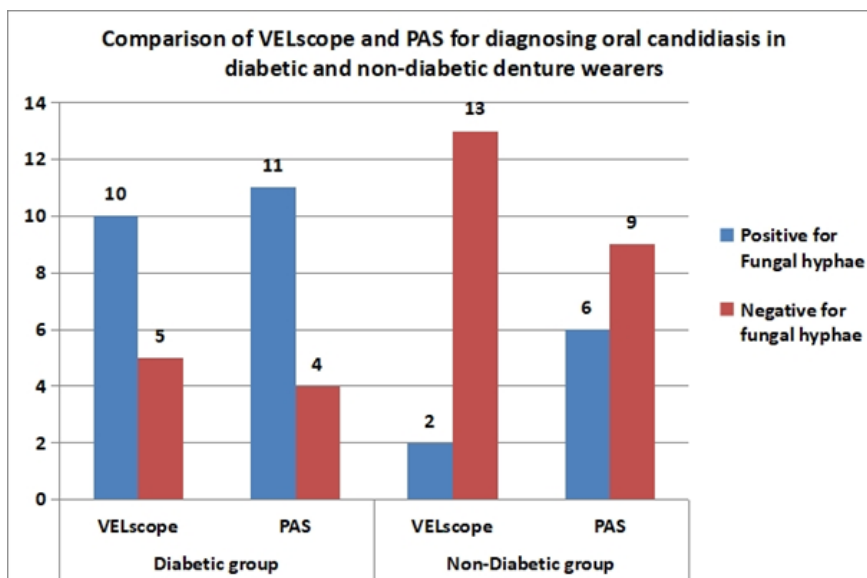


Table & Graph 5 – Intragroup comparison of VELscope and PAS for diagnosing oral candidiasis in diabetic and non-diabetic denture wearers

VELscope vs PAS	Diabetic group	Non-Diabetic group
Mann-Whitney U	51.500	60.000
p value	.006*	.009*

*p value <0.05 statistically significant, <0.01 highly significant, <0.001 very highly significant



VI. Discussion

Denture stomatitis can be classified according to Newton’s classification into three types: Type I (localized inflammation), Type II (diffuse erythematous inflammation), and Type III (papillary hyperplasia), based on the severity and extent of the infection¹⁰. Traditional diagnostic methods for *Candida* infections include direct microscopy, culture-based techniques, and occasionally serological tests. Microscopy typically involves staining with potassium hydroxide (KOH), Gram stain, or periodic acid-Schiff (PAS) to visualize fungal hyphae¹¹. Although these methods are reliable, they are often time-consuming, technically sensitive, and labor-intensive.

A comprehensive oral examination (COE) alone may not reliably distinguish mucosal lesions, which has led to the development of several adjunctive diagnostic aids. For rapid and large-scale screening, tools such as VELscope, Velscan, Vizilite, fluorescence spectroscopy, and optical coherence tomography (OCT) have been introduced to enhance early detection of mucosal abnormalities.

In the present study, the role of diabetes as a comorbidity was evaluated alongside denture stomatitis to assess the impact of metabolic alterations—particularly elevated carbohydrate levels—on the severity of *Candida* infection. A total of 30 participants were included, divided into two groups: diabetic (n = 15) and non-diabetic (n = 15). All selected cases were chronic complete denture wearers. The majority of participants in both groups were male, comprising 80.0% of the diabetic group and 73.3% of the non-diabetic group, while females made up 20.0% and 26.7% respectively.

Candida species are known to contribute to porphyrin fluorescence (PF), primarily due to the presence of endogenous porphyrins in their cell membranes¹². These porphyrins absorb blue light at a wavelength of 420 nm (as emitted by VELscope), which excites π electrons, resulting in the emission of light in the 520–550 nm range¹³. This process produces the characteristic yellow fluorescence seen during VELscope examination. The intensity of this fluorescence is influenced by several factors, including plaque thickness, density of fungal hyphae, concentration of porphyrin fluorochromes, fungal metabolic activity, and the presence of other microbial species.

In the present study, palatal areas exhibiting plaque-like growth demonstrated enhanced yellow fluorescence. The dorsal surface of the tongue was the most frequently affected site, showing yellow to orange fluorescence, highlighting its role as a major reservoir for *Candida*. These findings are consistent with the study by Massimo et al. (2019)¹⁴, which emphasized the tongue’s significance in fungal colonization. The enhanced yellow/orange/red fluorescence observed in these areas suggests the presence of *Candida* hyphae, a result also supported by Singh et al. (2023)¹⁵ and Ramnathan A et al. (2014)¹⁶. Their studies reported that pseudomembranous candidiasis, presenting as white, curdled-milk-like plaques that could be scraped off, exhibited yellow fluorescence under VELscope, with increased fluorescence visualization index (FVI)—likely due to the presence of fungal hyphae and keratin scales.

Additionally, denture-bearing areas frequently showed erythematous changes, particularly in regions with close mucosal contact. These sites commonly harbor plaque-like fungal biofilms, favored by the moist and enclosed environment created by the denture base. In the present study, such areas often exhibited loss of fluorescence, attributed to underlying inflammatory changes. Similar observations have been reported by Sreeshlya et al. (2020)¹⁷ and Simran Sunil Singh et al. (2023)¹⁸, further confirming the association between *Candida* colonization and altered autofluorescence in denture-wearing individuals.

When areas showing enhanced fluorescence were further evaluated using cytological smear examination with PAS staining, a correlation was observed between the intensity of VELscope findings and the number of fungal hyphae identified in the cytological smear. These correlations were more prominent among diabetic denture wearers compared to the non-diabetic group. This suggests that the rate of candidal carriage is significantly higher in diabetic individuals suggesting a positive correlation between glycemic control and candidal colonization.

Mohammadi et al. (2016)¹⁹ reported that xerostomia and physiological disturbances such as altered pH and glucose levels promote the overgrowth of *Candida* in the oral cavity. These factors are considered important predisposing conditions for oral candidiasis in diabetic patients. Additionally, local factors like denture prostheses further enhance fungal adherence and growth due to surface porosity and prolonged mucosal contact.

A related study by Loyse Martorano-Fernandes et al. (2020)²⁰ reported that the prevalence of oral candidiasis in diabetic patients ranged from 6.8% to 31%, while denture stomatitis ranged from 10.7% to 61.1% in the same population. These findings support the results of the present study, showing that oral candidiasis associated with denture stomatitis is more prevalent in diabetic than in non-diabetic individuals, thus reinforcing the role of metabolic changes in promoting *Candida* overgrowth.

In the present study, out of 30 patients assessed using the VELscope, significant findings were observed in 21 cases, which were further confirmed using Periodic Acid-Schiff (PAS) staining. Among these, 13 patients showed true positive results, and 8 patients showed true negative results, indicating a strong concordance between VELscope observations and PAS confirmation.

However, discrepancies were noted in the remaining 9 denture-wearing patients. Specifically, 3 cases were false positives, and 6 were false negatives with VELscope evaluation. The higher rate of false negatives, especially among non-diabetic individuals, highlights some of the limitations of fluorescence-based detection.

While the VELscope offers both qualitative and real-time visual assessment of mucosal autofluorescence, certain infected areas may not exhibit detectable changes, potentially leading to underdiagnosis. On the other hand, PAS staining remains a highly sensitive diagnostic tool, capable of detecting even minimal fungal hyphae, making it a reliable confirmatory method for diagnosing oral candidiasis.

VII. Conclusion

In addition to detecting dysplastic changes, the VELscope can also be used to uncover underlying fungal lesions, which serves as an added advantage compared to conventional screening tools. There is no direct contact with the patient, thereby reducing the risk of cross-contamination, which makes it a suitable for mass screening and routine clinical application as an adjunctive diagnostic tool. VELscope can be effectively used to closely monitor patients susceptible to *Candida* infections, including denture wearers, individual with diabetics, and those who are immunocompromised. Further research should be conducted to explore the diagnostic potential of VELscope in identifying other types of *Candida* species among various at risk population.

References

- [1]. Patel M. Oral Cavity And *Candida Albicans*: Colonisation To The Development Of Infection. *Pathogens*. 2022 Mar 10;11(3):335.
- [2]. Al-Garawi NA, Suhail AA, Meri MA. An Overview To Candidiasis: Types Of Candidiasis, Virulence Factors, Symptoms Of Infection And Treatment. *Medical Science Journal For Advance Research*. 2022 Mar 1;3(1):12-9.
- [3]. Novo VM, Feletti MP, Maifrede SB, Da Fonseca JZ, Cayô R, Gonçalves SS, Grão-Velloso TR. Clinical And Mycological Analysis Of Colonization By *Candida* Spp. In Oral Leukoplakia And Oral Lichen Planus. *Brazilian Journal Of Microbiology*. 2024 Sep;55(3):2693-703.
- [4]. Qiu J, Roza MP, Colli KG, Dalben YR, Maifrede SB, Valiatti TB, Novo VM, Cayô R, Grão-Velloso TR, Gonçalves SS. *Candida*-Associated Denture Stomatitis: Clinical, Epidemiological, And Microbiological Features. *Brazilian Journal Of Microbiology*. 2023 Jun;54(2):841-8.
- [5]. McCreynolds DE, Moorthy A, Moneley JO, Jabra-Rizk MA, Sultan AS. Denture Stomatitis—An Interdisciplinary Clinical Review. *Journal Of Prosthodontics*. 2023 Aug;32(7):560-70.
- [6]. Cicciù M, Cervino G, Fiorillo L, D’Amico C, Oteri G, Troiano G, Zhurakivska K, Lo Muzio L, Herford AS, Crimi S, Bianchi A. Early Diagnosis On Oral And Potentially Oral Malignant Lesions: A Systematic Review On The Velscope® Fluorescence Method. *Dentistry Journal*. 2019 Sep 4;7(3):93.
- [7]. Shah S, Wakis P, Saha A, Setiya S, Ratra T, Vaswani V. The Use Of Velscope To Assess Cellular Changes Occuring In Oral Premalignancy. *Journal Of Oral Biology And Craniofacial Research*. 2020 Apr 1;10(2):99-103.
- [8]. Cicciù M, Herford AS, Cervino G, Troiano G, Lauritano F, Laino L. Tissue Fluorescence Imaging (Velscope) For Quick Non-Invasive Diagnosis In Oral Pathology. *Journal Of Craniofacial Surgery*. 2017 Mar 1;28(2):E112-5.
- [9].
- [10]. Neppelenbroek KH, Falcão Procópio AL, Gurgel Gomes AC, Campos Sugio CY, Maia Neves Garcia AA, Porto VC, Urban VM. A Modified Newton Classification For Denture Stomatitis. *Primary Dental Journal*. 2022 Jun;11(2):55-8.
- [11]. Coronado-Castellote L, Jiménez-Soriano Y. Clinical And Microbiological Diagnosis Of Oral Candidiasis. *Journal Of Clinical And Experimental Dentistry*. 2013 Dec 1;5(5):E279.
- [12]. Petruzzini M, Della Vella F, Cassandro A, Mosca A, Di Comite M, Contaldo M, Grassi FR, Lauritano D. Dorsal Tongue Porphyrin Autofluorescence And *Candida* Saprophytism: A Prospective Observational Study. *Plos One*. 2019 Sep 26;14(9):E0223072
- [13]. Lee MW, Lee DL, Yen WN, Yeh CY. Synthesis, Optical And Photovoltaic Properties Of Porphyrin Dyes. *Journal Of Macromolecular Science®, Part A: Pure And Applied Chemistry*. 2009 May 27;46(7):730-7.

- [14]. Petruzzi M, Della Vella F, Cassandro A, Mosca A, Di Comite M, Contaldo M, Grassi FR, Lauritano D. Dorsal Tongue Porphyrin Autofluorescence And Candida Saprophytism: A Prospective Observational Study. Plos One. 2019 Sep 26;14(9):E0223072.
- [15]. Singh, Simran Sunil¹; Hebbale, Manjula¹; Mhapuskar, Amit¹; Mahapatra, Subharina¹; Kaur, Avneet². “Velscope As An Adjuvant Chairside Diagnostic Tool” – A Clinical Case Series. Archives Of Medicine And Health Sciences 11(2):P 263-267, Jul–Dec 2023.
- [16]. Ramanathan A, Rosedee NA, Edwer SA, John EP, Palaniswamy K, Bakar ZA. Utility Of Autofluorescence Imaging In The Detection Of Oral Mucosal Lesions In Elderly Institutionalised Subjects. Annals Of Dentistry University Of Malaya. 2014;21(1):6-16.
- [17]. Sreeshyla HS, Jaishankar HP, Shashidara R, Usha H, Priyanka N, Premalatha BR, Srinivas J. Velscope-Tissue Fluorescence Based Diagnostic Aid In Oral Precancer And Cancer. JMDR. 2020 Jun 25;6:41-6.
- [18]. Singh SS, Hebbale M, Mhapuskar A, Mahapatra S, Kaur A. “Velscope As An Adjuvant Chairside Diagnostic Tool”–A Clinical Case Series. Archives Of Medicine And Health Sciences. 2023 Jul 1;11(2):263-7.
- [19]. Mohammadi F, Javaheri MR, Nekoeian S, Dehghan P. Identification Of Candida Species In The Oral Cavity Of Diabetic Patients. Current Medical Mycology. 2016 Jun;2(2):1.
- [20]. Martorano-Fernandes L, Dornelas-Figueira LM, Marcello-Machado RM, Silva RD, Magno MB, Maia LC, Del Bel Cury AA. Oral Candidiasis And Denture Stomatitis In Diabetic Patients: Systematic Review And Meta-Analysis. Brazilian Oral Research. 2020 Sep 21;34:E113.