

Bronchiectasis Revealing A Common Variable Immunodeficiency In An Adult

Author

Abstract

While often thought of as childhood diseases, a significant number of Primary immune deficiency (PID) cases are diagnosed in adults. Common variable immunodeficiency (CVID) is the most common primary symptomatic humoral immunodeficiency in adults, which entails higher susceptibility to sinopulmonary infections and bronchiectasis formation.

Here we report the case of a 54 year-old man, chronic smoker, presenting with dyspnea, fever and cough; He complained of recurring pneumonia since he was 18 years old. High resolution chest scans showed disseminated bronchiectasis. Serum immunoglobulins quantification showed severe hypogammaglobulinemia (total Ig G : 2,54 g/l (5.4- 18,2), Ig A : 0,38 g/l (0,7- 3,8) ,Ig M : 0,02 g/l (0,22 - 2,4)), and the CD19 level was 0, which indicates a B lymphocyte deficiency. Treatment with Human Intravenous Immunoglobulin (IVIG) 10% was started, with antibiotic treatment for the acute bacterial exacerbation of bronchiectasis. Finally, the study discusses CVID as a potential risk factor for pulmonary infections and bronchiectasis, which can be easily overlooked and cause poor outcomes.

Date of Submission: 03-05-2026

Date of Acceptance: 13-05-2026

I. Introduction

Common Variable Immunodeficiency (CVID) is a predominantly antibody primary immunodeficiency in which the humoral immune response is altered. The clinical spectrum of this disease ranges from repeated infections with sequelae such as the appearance of bronchiectasis (1). We report case of a 54-year-old man, a cigarette smoker and with history of recurrent sinopulmonary infections revealing bronchiectasis, in whom a severe hypogammaglobulinemia compatible with Common Variable Immunodeficiency was demonstrated.

II. Case Presentation

A 54-year-old man, chronic smoker, complained of dyspnea, fever and cough with purulent sputum of approximately one week duration, with worsening dyspnea in the past 48 hours until being unable of performing any minimal effort. At admission, he presented tachypnea, with saturation of 80% O₂ (O₂ atmosphere); lung auscultation revealed pulmonary snoring sounds.

As relevant background, he refers pneumonia and sinusitis since he was aged 18 years, with multiples episodes (3 to 5 per year) requiring long courses of oral antibiotics.

High resolution chest scans showed disseminated bronchiectasis (Figure 1). Bloudeau CT scan confirms chronic sinusitis (Figure 2).

Oxygen therapy and antibiotic coverage was initiated with Ceftriaxone, bronchodilators for probable grade B COPD, respiratory drainage physiotherapy and abundant fluids to treat this bacterial exacerbation of bronchiectasis.

Paraclinical income tests showed leukocytosis at the expense of neutrophilia, major bandemia without anemia, normal platelets (281,000/mm³), and elevated acute phase reactants. Kidney function was normal, with no proteinuria; HIV testing was negative. Evaluation for primary immune deficiency was initiated and he was found to have hypoproteinemia at the expense of globulins (total protein: 42 g/l (56-83)), hypogammaglobulinemia : 1.3 g/l (8-13,5). Quantification of total serum immunoglobulins showed severe hypogammaglobulinemia (Total Ig G : 2,54 g/l (5.4- 18,2), Ig A : 0,38 g/l (0,7- 3,8), Ig M : 0,02 g/l (0,22 - 2,4)). Evaluation of lymphocyte subpopulations in peripheral blood showed a B lymphocyte count of 0 cells/μl.

On the basis of the clinical picture, findings from history taking, and laboratory test results, a diagnosis of CVID was made and the patient was started on human immunoglobulin replacement therapy, which resulted in rapid clinical and radiological improvement.

The patient received two doses of IGIV at a dose of 800 mg/kg every 4 weeks and prophylaxis with macrolides. After Two months, the quantification of total serum immunoglobulins becomes normal.

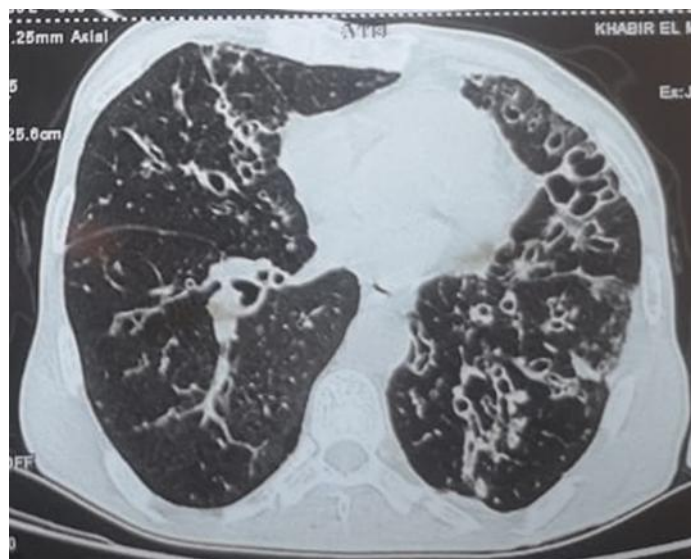


Figure 1: High resolution chest scans : Disseminated bronchiectasis

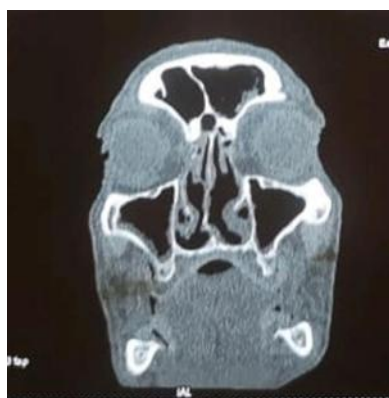

Figure 2: Blondeau CT scan confirms chronic sinusitis

III. Discussion

Common variable immunodeficiency is the most prevalent of the severe primary immunodeficiencies. A diagnosis of CVID is based on reduced levels of IgG, IgA, and (in some cases) IgM, together with reduced levels of specific antibodies, after other causes of hypogammaglobulinemia have been excluded (2).

Common Variable Immunodeficiency (CVID) is the primary immunodeficiency of clinical relevance most frequently found in adulthood (3-4-5).

The incidence of CVI is similar in both genders, with either sporadic or familial distribution.

Patients with CVID typically present with a history of recurrent infections, particularly affecting the upper and lower respiratory tracts, including sinusitis, otitis media, bronchitis, and pneumonia, which are often severe, persistent, or unusually frequent. Sinopulmonary infections are common and may lead to bronchiectasis, which contributes to chronic productive cough, dyspnea, and obstructive lung disease (6-7-8-9).

Bronchiectasis occurs in about 20% of cases which is a structural airway abnormality resulting from recurrent bacterial infections and chronic inflammation.

The diagnostic criteria for CVID were established by the European and Panamerican Immunodeficiencies Societies (ESID/PAGID) in 1999, and still in force so far, include: marked decrease (at least 2 standard deviations below the mean for age) of IgG, IgA and/or IgM in serum; to be older than 4 years, to be negative for isohemagglutinins and/or to have poor responses to vaccines; besides, other causes of hypogammaglobulinemia must have been excluded. Compliance with all of the above criteria is essential for diagnosis prior to initiation of therapy with IVIG replacement, because this therapy modifies serological parameters up to six months after the last application (10).

The goal of treatment is replacement of the humoral response by administering human immunoglobulin in order to reduce infectious and autoimmune complications, and the emergence of granulomas or malignancy. IVIG is typically administered at 300 to 600 mg/kg every 3 to 4 weeks, while subcutaneous IGRT (SCIG) is usually given weekly or biweekly. Selection depends on tolerability, lifestyle considerations,

and access to care; The use of antibiotic prophylaxis is not clearly established; however, it is recommended the use of macrolides and quinolones; and for cases that present with low CD4+T lymphocytes counts, it is recommended prophylaxis with trimethoprim/sulfamethoxazole.

IV. Conclusion

Common variable immunodeficiency (CVID) is the most prevalent symptomatic primary immunodeficiency disorder characterized by infectious and noninfectious complications. Bronchiectasis continues to be a common respiratory problem and therapeutic challenge in CVID. Despite being a genetic disorder, adults are the most affected, so efforts should be attempted to educate medical community.

References

- [1]. Rosel AL, Scheibenbogen C, Schliesser U, Sollwedel A, Hoffmeister B, Hanitsch L, Et Al. Classification Of Common Variable Immunodeficiencies Using Flow Cytometry And A Memory B-Cell Functionality Assay. *J Allergy Clin Immunol.* 2014;135(1):197–208.
- [2]. Kumar Y, Bhatia A. Comment On Common Variable Immunodeficiency In Adults: Current Diagnostic Protocol And Laboratory Measures . *Expert Rev Clin Immunol.* 2013;10(2):187–188
- [3]. Fernandez Romero DS, Juri MC, Paolini MV, Malbran A. Common Variable Immunodeficiency: Epidemiology And Clinical Manifestations In 69 Patients. *Med (B Aires).* 2013;73(4):315–323
- [4]. Shoemark A, Ozerovitch L, Wilson R. Aetiology In Adult Patients With Bronchiectasis. *Respir Med.* 2007;101(6):1163–1170
- [5]. Janssen LMA, Van Der Flier M, De Vries E. Lessons Learned From The Clinical Presentation Of Common Variable Immunodeficiency Disorders: A Systematic Review And Meta-Analysis. *Front Immunol.* 2021;12:620709.
- [6]. Bonilla FA Et Al. Joint Task Force On Practice Parameters, Representing The American Academy Of Allergy, Asthma & Immunology; The American College Of Allergy, Asthma & Immunology; And The Joint Council Of Allergy, Asthma & Immunology. Practice Parameter For The Diagnosis And Management Of Primary Immunodeficiency. *J Allergy Clin Immunol.* 2015 Nov;136(5):1186-205.E1-78.
- [7]. Gathmann B,Et Al, European Society For Immunodeficiencies Registry Working Party. Clinical Picture And Treatment Of 2212 Patients With Common Variable Immunodeficiency. *J Allergy Clin Immunol.* 2014 Jul;134(1):116-26.
- [8]. Cunningham-Rundles C. Common Variable Immune Deficiency: Case Studies. *Blood.* 2019 Nov 21;134(21):1787-1795.
- [9]. Webster AD. Clinical And Immunological Spectrum Of Common Variable Immunodeficiency (CVID). *Iran J Allergy Asthma Immunol.* 2004;3(3):103–113
- [10]. Remiker A, Bolling K, Verbsky J. Common Variable Immunodeficiency. *Med Clin North Am.* 2024 Jan;108(1):107-121.