IOSR Journal of Dental and Medical Sciences (IOSR-JDMS)
e-ISSN: 2279-0853, p-ISSN: 2279-0861.Volume 25, Issue 5 Ser. 3 (May. 2026), PP 19-25
www.iosrjournals.org

Comparative Evaluation Of Topical Vitamin E And Vitamin C On Postoperative Healing Following Gingival Depigmentation Using Toluidine Blue–Based Epithelialization Assessment: A Split-Mouth Clinical Study

Dr. Ashutosh Dubey, Dr. Juhi Dubey, Dr. Omkar Dhumal, Dr. Sejal Ameriya, Dr. Gautam Pawar, Dr. Babita Niranjan

(Professor & HOD, Department Of Periodontology And Implantology, Rishiraj College Of Dental Sciences And Research Center, Bhopal, Madhya Pradesh, India)
(Associate Director, Artificial Intelligence, United Health Group Optum, India)
(Post Graduate, Department Of Periodontology And Implantology, Rishiraj College Of Dental Sciences And Research Center, Bhopal, Madhya Pradesh, India)
(Post Graduate Department Of Periodontology And Implantology, Rishiraj College Of Dental Sciences And Research Center, Bhopal, Madhya Pradesh, India)
(Post Graduate Department Of Periodontology And Implantology, Rishiraj College Of Dental Sciences And Research Center, Bhopal, Madhya Pradesh, India)
(Professor And HOD, Department Of Pediatric And Preventive Dentistry, Rishiraj College Of Dental Sciences And Research Centre, Bhopal, Madhya Pradesh, India)

Abstract:
Background: *Optimization of postoperative healing following gingival depigmentation remains a clinical challenge. Oxidative stress has been implicated in delayed wound healing, and topical antioxidants may enhance tissue repair.*
Aim: *To comparatively evaluate the effect of topical Vitamin E and Vitamin C on healing following gingival depigmentation using clinical parameters and Toluidine Blue–based epithelialization assessment.*
Methods: *A split-mouth clinical study was conducted on 13 systemically healthy patients (26 sites) with bilateral gingival hyperpigmentation. Following scalpel depigmentation, Vitamin E (400 mg) and Vitamin C (100 mg) were randomly applied to contralateral sites. Healing was assessed on days 3, 5, 7, 10, and 14 using Visual Analog Scale (VAS), Healing Index (HI), and Toluidine Blue staining. Statistical analysis was performed using paired and independent t-tests with significance set at $p<0.05$.*
Results: *Vitamin E demonstrated significantly lower pain scores on days 3, 5, and 7 ($p<0.05$). Healing Index scores were significantly higher in the Vitamin E group on days 5 and 7 ($p\leq0.001$). Toluidine Blue staining showed reduced dye uptake in Vitamin E sites, indicating faster epithelialization.*
Conclusion: *Topical Vitamin E enhances early wound healing and reduces postoperative discomfort more effectively than Vitamin C following gingival depigmentation.*
Clinical Relevance: *Vitamin E may serve as a simple and effective adjunct to improve clinical outcomes in esthetic periodontal procedures.*
Key Words: *Gingival depigmentation; Vitamin E; Vitamin C; Toluidine Blue; Epithelialization; Wound healing.*

Date of Submission: 06-05-2026 Date of Acceptance: 16-05-2026

I. Introduction

Gingival hyperpigmentation, caused by excessive melanin deposition in the basal and suprabasal layers of the gingival epithelium, is a common esthetic concern in patients with a high smile line.[1,3] Although physiologically benign, many patients seek treatment to improve smile esthetics and self-confidence.[10,16] Various depigmentation modalities have been described, including scalpel surgery, electrosurgery, cryosurgery, bur abrasion, and laser therapy.[1,10,11] The scalpel technique remains widely used due to its simplicity and predictability,[3,5] yet it leaves a denuded wound surface healing by secondary intention, often associated with postoperative pain, inflammation, delayed epithelialization, and pigmentation recurrence.[1,5]

Wound healing following periodontal surgery involves sequential phases of inflammation, fibroblast proliferation, collagen synthesis, angiogenesis, and epithelial maturation.[8,12] Oxidative stress, mediated by

excess reactive oxygen species (ROS), impairs fibroblast function and collagen deposition, thereby retarding tissue regeneration.[8,14] Antioxidants mitigate this damage by scavenging free radicals and restoring a pro-healing cellular environment.[8,12,14]

Vitamin E (α-tocopherol) is a lipid-soluble antioxidant that stabilizes cellular membranes, inhibits lipid peroxidation, modulates inflammatory mediators, and promotes fibroblast proliferation and collagen maturation.[7,13,14] Its anti-inflammatory and antioxidant actions have been shown to support periodontal tissue repair.[7] Vitamin C (ascorbic acid), a water-soluble antioxidant, is essential for collagen biosynthesis, angiogenesis, fibroblast differentiation, and epithelial regeneration.[9,10,11] It also inhibits melanin synthesis by interfering with tyrosinase activity, making it particularly relevant in depigmentation procedures.[2,3,4] Clinical studies have demonstrated favorable healing outcomes with topical Vitamin C following gingival depigmentation,[2,3,4,5] and a split-mouth comparison of Vitamins E and C in depigmentation has been previously reported.[6]

Toluidine Blue, a metachromatic dye with affinity for nucleic acids in immature epithelial cells, has been used as a chairside tool for assessing epithelialization.[17,18] Traditionally used to identify dysplastic and premalignant oral lesions,[17,18] its application in postoperative periodontal wound monitoring may provide a simple, objective method for evaluating epithelial healing at depigmented sites.

Despite the established roles of both vitamins in wound healing, comparative clinical evidence on their efficacy following gingival depigmentation remains limited. Hence, the present split-mouth study was designed to comparatively evaluate topical Vitamin E and Vitamin C on postoperative healing using clinical parameters and Toluidine Blue–based epithelialization assessment.

II. Materials And Methods

This study was conducted on patients of the Department of Periodontology and Implantology at Rishiraj College of Dental Sciences and Research Center, Bhopal, Madhya Pradesh. A total of 13 patients were selected for the study.

Study Design: Split-mouth clinical study.

Study Location: Department of Periodontology and Implantology, Rishiraj College of Dental Sciences and Research Center, Bhopal, Madhya Pradesh.

Sample Size: 13 patients (26 sites) with bilateral gingival hyperpigmentation.

Intervention:
Group A: Vitamin E (400 mg) applied topically to one side.
Group B: Vitamin C (100 mg) applied topically to the contralateral side.

Inclusion Criteria:
- Age >18 years
- Bilateral gingival hyperpigmentation in anterior region
- Systemically healthy individuals
- Patients willing for depigmentation and follow-up
- Patients providing informed consent

Exclusion Criteria:
- Systemic diseases affecting healing
- Smokers or tobacco users
- Pregnant or lactating females
- Patients on steroids, anticoagulants, or immunosuppressant
- Active periodontal disease
- Previous history of depigmentation
- Allergy to Vitamin E or Vitamin C

Surgical Procedure:

Scalpel depigmentation was performed under local anesthesia. Following the procedure, Vitamin E (400 mg) was applied topically to the randomly assigned test site and Vitamin C (100 mg) to the control site.

Evaluation Parameters:
- Visual Analog Scale (VAS) for pain assessment.
- Healing Index (Landry et al., 1988) for wound healing assessment.
- Toluidine Blue staining for epithelialization assessment on days 3, 5, 7, 10, and 14.

Statistical Analysis:

Data were analyzed using paired t-test (intragroup) and independent t-test (intergroup). A p-value <0.05 was considered statistically significant.

Figure 1: Topical application of Vit.E

Figure 2: Topical application of Vit.C

III. Results

A total of 13 patients (26 sites) completed the study, with no dropouts reported during the follow-up period. Healing outcomes were assessed using Visual Analog Scale (VAS) scores for pain and Healing Index (HI) scores at postoperative days 3, 5, 7, 10, and 14.

Figure 3: Day 3 Postoperative follow up.

Figure 4: Day 5 Postoperative follow up.

Figure 5: Day 7 Postoperative follow up.

Figure 6: Day 14 Postoperative follow up.

Pain Assessment (VAS Scores)

Both groups demonstrated a progressive reduction in postoperative pain over time. However, the Vitamin E group consistently exhibited lower mean VAS scores compared to the Vitamin C group, particularly during the early postoperative period.

Follow-up Days	Vit E		Vit C		P value∞
	Mean	Std Deviation	Mean	Std Deviation	
3rd day	5.23	0.725	6.77	0.725	0.000*
5th day	3.08	0.862	4.15	1.144	0.012*
7th day	1.15	0.801	0.707	0.466	0.009*
10th day	0.15	0.376	0.46	0.519	0.096
14th day	0.000	0.000	0.480	0.133	0.030*

**Statistically significant (p<0.05)*

Table 1: Comparison between VAS scores of two groups at different visits

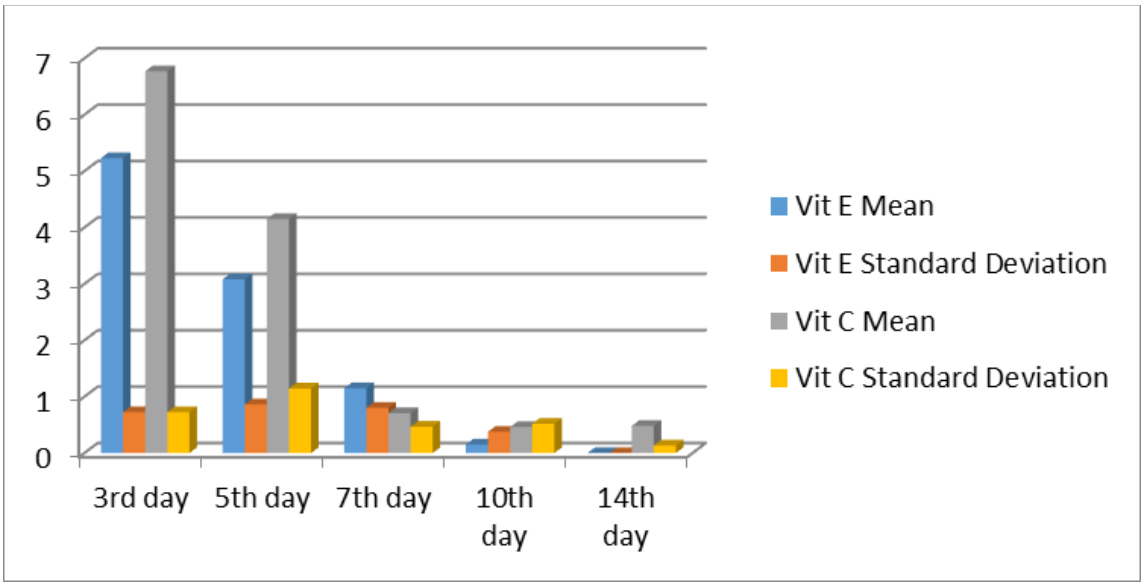

Graph 1: Comparison between VAS scores of two groups at different visits.

On day 3, the mean VAS score for the Vitamin E group was 5.23 ± 0.72, whereas the Vitamin C group showed a significantly higher score of 6.77 ± 0.72 ($p < 0.001$). This difference remained statistically significant on day 5 (3.08 ± 0.86 vs 4.15 ± 1.14; $p = 0.012$) and day 7 (1.15 ± 0.80 vs 2.00 ± 0.70; $p = 0.009$). By day 10, the difference was not statistically significant (0.15 ± 0.37 vs 0.46 ± 0.51; $p = 0.096$). On day 14, the Vitamin E group showed complete resolution of pain (0.00 ± 0.00) compared to residual pain in the Vitamin C group (0.31 ± 0.48), which was statistically significant ($p = 0.030$).

Healing Assessment (Healing Index Scores)

Healing Index scores showed a progressive increase in both groups, indicating improvement in tissue healing over time. However, the Vitamin E group demonstrated comparatively faster healing throughout the follow-up period.

Follow-up Days	Vit E		Vit C		P value∞
	Mean	Std Deviation	Mean	Std Deviation	
3rd day	1.85	0.376	1.62	0.506	0.199
5th day	3.45	0.519	2.54	0.519	0.000*
7th day	4.38	0.506	3.62	0.506	0.001*
10th day	5.00	0.000	4.85	0.376	0.153
14th day	5.00	0.000	4.62	0.506	0.011*

**Statistically significant (p<0.05)*

Table 2: Comparison between Healing Index scores of two groups at different visits

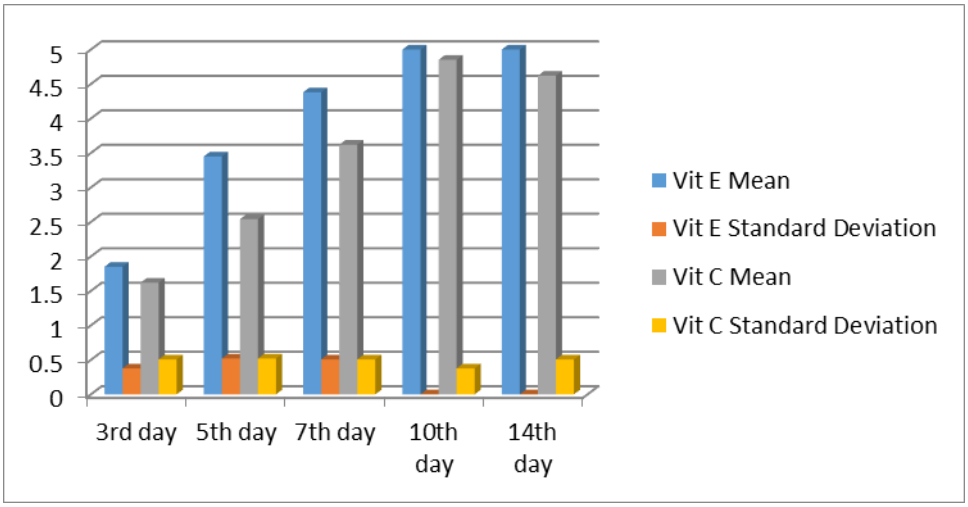

Graph 2: Comparison between Healing Index scores of two groups at different visits

On day 3, no statistically significant difference was observed between the groups (1.85 ± 0.37 vs 1.62 ± 0.50; p = 0.199). However, by day 5, the Vitamin E group exhibited significantly higher HI scores (3.46 ± 0.51) compared to the Vitamin C group (2.54 ± 0.51; p < 0.001). This trend continued on day 7 (4.38 ± 0.50 vs 3.62 ± 0.50; p = 0.001). By day 10, both groups showed near-complete healing (5.00 ± 0.00 vs 4.85 ± 0.37; p = 0.153). On day 14, the Vitamin E group achieved complete healing in all sites (5.00 ± 0.00) compared to the Vitamin C group (4.62 ± 0.50; p = 0.011).

IV. Discussion

The present split-mouth clinical study was designed to comparatively evaluate the efficacy of two widely used topical antioxidants, Vitamin E and Vitamin C, in enhancing postoperative healing following gingival depigmentation. A comprehensive healing assessment framework was employed, incorporating subjective pain measurement via the Visual Analog Scale (VAS), objective clinical healing via the Healing Index, and epithelialization assessment via Toluidine Blue staining, to provide a multi-dimensional evaluation of wound healing dynamics.

Scalpel-based gingival depigmentation creates a denuded connective tissue wound bed that heals by secondary intention, initiating an acute inflammatory response accompanied by oxidative stress and delayed epithelialization. Reactive oxygen species (ROS) generated during the inflammatory phase impair fibroblast activity, collagen deposition, and epithelial migration, collectively prolonging the wound healing process.[8] Modulation of this oxidative burden through adjunctive antioxidant therapy has therefore gained increasing attention as a strategy to accelerate periodontal wound repair.[8,14] This therapeutic rationale is consistent with the findings of Ukaegbu et al., who reviewed the mechanistic basis and therapeutic potential of antioxidants in wound healing,[8] and is further corroborated by Altayeb et al., who noted the clinical challenges associated with postoperative morbidity and recurrence following gingival depigmentation procedures.[1]

In the present investigation, both Vitamin E and Vitamin C yielded progressive improvements in healing outcomes throughout the 14-day follow-up, consistent with the well-established antioxidant role of these vitamins in promoting tissue repair.[9,12] Nonetheless, Vitamin E demonstrated a clear superiority over Vitamin C during the early postoperative period, as evidenced by significantly lower VAS pain scores and higher Healing Index values on days 5 and 7 (p≤0.001). These findings are consistent with those of Agrawal et al., who reported better healing outcomes with Vitamin E compared to Vitamin C in a similar split-mouth depigmentation design,[6] and

align with the broader evidence supporting antioxidant-enhanced wound repair documented by Murererehe et al. and Ruzijevaite et al.[9,10]

The superior early healing performance of Vitamin E may be attributed to its lipid-soluble nature, which allows it to intercalate into and stabilize phospholipid bilayers of cellular membranes, thereby inhibiting lipid peroxidation chain reactions. This membrane-protective action shields gingival cells from oxidative damage and creates conditions conducive to faster epithelial regeneration. Buranasin et al. demonstrated that Vitamin E and related antioxidants enhance fibroblast viability, reduce inflammatory mediator release, and support tissue regeneration in periodontal wounds,[14] supporting its capacity to reduce vascular permeability and attenuate early pro-inflammatory cytokine release — mechanisms that collectively explain the significantly lower pain scores recorded in the Vitamin E group during the first postoperative week. Additionally, Shadisvaaran et al. reviewed the evidence for Vitamin E in periodontal tissue repair and identified its anti-inflammatory and antioxidant actions as the primary drivers of improved clinical outcomes.[7]

The superior retention and bioavailability of Vitamin E at the surgical wound site may represent an additional contributing mechanism. Formulated in a viscous or oil-based vehicle, Vitamin E adheres tenaciously to the moist wound surface, ensuring sustained antioxidant protection throughout the critical early healing period. In contrast, Vitamin C, being water-soluble, is prone to rapid dilution by saliva, potentially limiting the duration and concentration of its local antioxidant activity. This pharmacokinetic disparity may partly account for the observed differences in early pain and healing indices between the two groups.

Vitamin C contributes to wound repair principally by serving as an essential cofactor in prolyl and lysyl hydroxylase reactions, which are rate-limiting steps in collagen cross-linking and maturation. It also promotes angiogenesis and stimulates fibroblast proliferation, effects documented by Pullar et al.[11] and Mohammed et al.[12] Phothipakdee et al. further confirmed in vitro that ascorbic acid promotes gingival fibroblast wound healing behavior in a concentration-dependent manner.[13] However, clinical studies including those by El-Mofty et al., Chaudhary et al., Esmat et al., and Sanadi et al. suggest that Vitamin C's healing effects are more prominent during the proliferative phase than during the acute inflammatory phase.[2,3,4,5] This phase-specific activity may explain why Vitamin C performed comparably to Vitamin E only in the later stages of the follow-up (days 10 and 14), while demonstrating inferior early healing during the inflammatory phase of wound repair. Additionally, Vitamin C's well-documented inhibitory action on tyrosinase activity may reduce melanocyte reactivation at healing sites, a finding of particular relevance to long-term repigmentation prevention.[2,3,16]

A methodologically distinctive feature of the present study was the incorporation of Toluidine Blue staining as a chairside, objective tool to monitor epithelialization at the depigmented sites. Toluidine Blue preferentially stains nucleic-acid-rich immature epithelial cells; as epithelialization progresses and the epithelium matures, the staining intensity diminishes. Sites treated with Vitamin E exhibited a notably earlier reduction in dye uptake compared to Vitamin C sites, indicating accelerated re-epithelialization. These observations corroborate the serial Healing Index scores and are consistent with the chairside utility of Toluidine Blue reported by Durgam et al.[17] and Mehrotra et al.[18] in the context of oral mucosal epithelial assessment. The application of this dye in periodontal wound surveillance is novel and represents a potentially valuable addition to the postoperative monitoring toolkit for depigmentation procedures.

Despite the promising findings of this study, several limitations must be acknowledged. The sample size of 13 patients, while adequate for a preliminary split-mouth investigation, is relatively modest and may limit the generalizability of the results. The follow-up period of 14 days, although sufficient to capture the primary wound healing events, does not permit evaluation of long-term clinical outcomes such as repigmentation — a concern specifically highlighted in the context of Vitamin C's antimelanogenic properties by Aljahdali and Dahlan in their recent systematic review.[16] The absence of histological and biomolecular evaluation of the healing tissue is also a recognized limitation. Furthermore, the hydrogel and nanogel-based biomaterial research reviewed by Nosrati et al. suggests that novel wound dressings incorporating antioxidants may provide more controlled delivery and potentiated outcomes than simple topical application, underscoring directions for future research.[15] Future investigations with larger sample sizes, extended follow-up periods, histological assessments, and biomolecular markers of inflammation and oxidative stress are recommended to further validate and expand upon these preliminary findings.

V. Conclusion

Topical Vitamin E demonstrated superior early wound healing, reduced postoperative pain, and faster epithelialization compared to Vitamin C following gingival depigmentation. Vitamin E may serve as a simple and effective adjunct to improve clinical outcomes in esthetic periodontal procedures.

References

[1]. Altayeb W, Hamadah O, Alhaffar BA, Abdullah A, Romanos G. Gingival Depigmentation With Diode And Er,Cr:YSGG Laser: Evaluating Re-Pigmentation Rate And Patient Perceptions. Clin Oral Investig. 2021;25(9):5351–61.

[2]. El-Mofty M, Elkot S, Ghoneim A, Yossri D, Ezzatt OM. Vitamin C Mesotherapy Versus Topical Application For Gingival Hyperpigmentation: A Clinical And Histopathological Study. Clin Oral Investig. 2021;25(12):6881–9.

[3]. Chaudhary N, Borse S, Kolhe S, Makade C, Kathariya R. Physiological Gingival Melanin Hyperpigmentation Treatment With Injectable Vitamin C And Scalpel Technique: A Randomised Controlled Clinical Trial. Int J Dent. 2023;2023:4586923.

[4]. Esmat SA, El-Sayed NM, Fahmy RA. Vitamin C Mesotherapy Versus Diode Laser For The Esthetic Management Of Physiologic Gingival Hyperpigmentation: A Randomized Clinical Trial. BMC Oral Health. 2023;23:899.

[5]. Sanadi RM, Deshmukh RS. Evaluation Of Gingival Depigmentation Using Different Surgical Techniques And Prevention Of Repigmentation With Vitamin C: A Clinical Study. Cureus. 2025;17(1):E76925.

[6]. Agrawal R, Chauhan SS, Sinha A, Sharma S. Effect Of Vitamin E Versus Vitamin C Application On Wound Healing In The Gingival Depigmentation Procedure: A Split-Mouth Clinical Comparative Study. Dent Med Res. 2024;12(2):65–9.

[7]. Shadisvaaran S, Chin KY, Shahida MS, Ima-Nirwana S, Leong XF. Effect Of Vitamin E On Periodontitis: Evidence And Proposed Mechanisms Of Action. J Oral Biosci. 2021;63(2):97–103.

[8]. Ukaegbu K, Allen E, Svoboda KKH. Reactive Oxygen Species And Antioxidants In Wound Healing: Mechanisms And Therapeutic Potential. Int Wound J. 2025;22(4):E70330.

[9]. Murererehe J, Uwitonze AM, Nikuze P, Patel J, Razzaque MS. Beneficial Effects Of Vitamin C In Maintaining Optimal Oral Health. Front Nutr. 2022;8:805809.

[10]. Ruzijevaite G, Acaite E, Jagelaviciene E. Therapeutic Impact Of Ascorbic Acid On Oral And Periodontal Tissues: A Systematic Literature Review. Medicina (Kaunas). 2024;60(12):2041.

[11]. Pullar JM, Carr AC, Vissers MCM. The Roles Of Vitamin C In Skin Health. Nutrients. 2017;9(8):866.

[12]. Mohammed BM, Fisher BJ, Kraskauskas D, Ward S, Wayne JS, Brophy DF, Et Al. Vitamin C Promotes Wound Healing Through Novel Pleiotropic Mechanisms. Int Wound J. 2016;13(4):572–84.

[13]. Phothipakdee P, Sattayut S, Subbalekha K, Tangsripongkul K. Rinsing With L-Ascorbic Acid Exhibits Concentration-Dependent Effects On Human Gingival Fibroblast In Vitro Wound Healing Behavior. Int J Dent. 2020;2020:3720645.

[14]. Buranasin P, Kominato H, Mizutani K, Mikami R, Saito N, Takeda K, Et Al. Influence Of Reactive Oxygen Species On Wound Healing And Tissue Regeneration In Periodontal And Peri-Implant Tissues In Diabetic Patients. Antioxidants (Basel). 2023;12(9):1787.

[15]. Nosrati H, Khodaei M, Alizadeh Z, Banitalebi-Dehkordi M. Cationic, Anionic And Neutral Polysaccharide-Based Hydrogels And Nanogels For Wound Healing. Int J Biol Macromol. 2021;173:465–83.

[16]. Aljahdali B, Dahlan R. Effectiveness Of Vitamin C For Gingival Depigmentation: A Systematic Review. Int J Dent. 2026;2026:6980625.

[17]. Durgam N, Yenuganti VK, Bhavanam VS, Suchitra S, Mounika V, Boppudi S. Toluidine Blue Staining As An Adjunctive Tool For Early Diagnosis Of Dysplastic Changes In The Oral Mucosa. J Oral Maxillofac Pathol. 2014;18(1):S117–21.

[18]. Mehrotra R, Singh M, Thomas S, Nair P, Pandya S, Nigam NS, Et Al. A Cross-Sectional Study Evaluating Chemiluminescence And Autofluorescence In The Detection Of Clinically Innocuous Precancerous And Cancerous Oral Lesions. J Am Dent Assoc. 2010;141(2):151–6.