

"Giant Cell Fibroma" – A Case Report

Dr. Verdine Virginia Antony, Dr. Rahamathulla Khan

¹ (Department of Periodontics & Implantology, Sirte University, Libya.)

² (Department of Orthodontics, Sirte University, Libya.)

Abstract: *The giant cell fibroma is a localized reactive proliferation of fibrous tissue, much like the irritation fibroma. It usually small, may have be sessile/peduncalated. It is painless, often has lobules/ nodules on its surface. It contains cells with large, stellate shaped fibroblasts, near the surface of the fibrous mass, beneath the overlying epithelium.*

A female patient aged 45 years presented with a small nodule like asymptomatic, sessile gingival overgrowth on the 12,13 region. The lesion was firm and fibrous in consistency with rough surface. The lesion was excised and sent for biopsy. Microscopically the section showed epithelium and connective tissue stroma with large stellate shaped fibroblast. Based on microscopic findings, the lesion was diagnosed as "giant cell fibroma".

Key Words: *Giant cell fibroma, Multinucleated, Stellate fibroblast.*

I. Introduction:

Giant cell fibroma is a benign tumor first reported by Weathers and Callihan [1] in 1974 as a lesion of oral mucosa with distinctive clinico-pathologic features[2,]. The name given to this variant is based on the presence of large multinucleated fibroblasts that tend to occur in close proximity to the overlying epithelium. These giant cells have oval nuclei with eosinophilic cytoplasm and they often assume a stellate appearance[3,4]. Pathologically giant cells are classified in different types. They can be grouped under the following categories inflammatory, neoplastic, metabolic disorders and bone disorders[5,6].

Giant cell fibroma is a fibrous oral benign asymptomatic pedunculated or sessile nodule less than 1 cm in size, more commonly seen in the mandibular gingiva and the lesion may persist for several years[2,3]. The giant cell fibroma is a localized reactive proliferation of fibrous tissue, much like the irritation fibroma. It usually remains small and may have a broad base or be on a thick stalk. It is painless and often has lobules or nodules on its surface. The most characteristic histological feature is the presence of large spindle-shaped and stellate-shaped mononuclear cells and multinucleated cells[4]. These cells occur in a variety of lesions, such as the fibrous papule of the nose, ungual fibroma, acral fibrokeratoma, acral angiofibroma and desmoplastic fibroblastoma[7]. Despite many studies, the nature of the stellate multinucleate and mononuclear cell is not clear[8]. Very few case reports are seen regarding this tumor and controversy regarding the origin of this lesion continues. This case report presents a case of Giant Cell Fibroma followed by brief review of this tumor

Case report:

A 45-year-old female patient was referred to the Department of Periodontics, for a growth over the labial surface of the right maxillary teeth. Patient had noticed the growth over the gingiva four months back but did not seek any medical assistance. Her medical history was non contributory. The growth slowly progressed and attained the current size.

Intra-oral examination revealed a solitary, reddish-pink firm gingival growth on the labial surface of the maxillary right arch of size 2x1cm extending between the distal aspect of lateral incisor and the mesial aspect of the canine. The lesion had a sessile base which was attached to the marginal and the attached gingiva (**Figure:1**). The lesion was firm and fibrous in consistency with rough surface. Radiographic examination using an intra-oral periapical radiograph revealed moderate amount of horizontal bone loss in relation to 12,13 region. Based on its clinical presentation, a provisional diagnosis of fibroma was established. The treatment procedure was then explained to the patient and informed consent obtained. The patient was advised for routine blood investigation and excisional biopsy. The blood investigation results were within the normal limits. The lesion was excised under local anaesthesia after phase I therapy (**Figure:2**). No sutures were necessary. No postoperative antibiotics were given. The patient was instructed to take analgesics if needed. Patient was recalled after one week to evaluate healing. Healing was uneventful (**Figure:3**). The excised specimen was sent for routine histopathological examination. Microscopically the section showed epithelium and connective tissue stroma. The epithelium is stratified squamous parakeratinized type. The connective tissue stroma consists of sinuous bundles of collagen tissue in which large stellate shaped fibroblasts are seen (**Figure:4**). These stellate cells have vesicular nucleus with cytoplasm showing few dendritic process. Endothelial lined blood vessels are

present in the stroma. Based on the microscopic findings, the lesion was diagnosed as “giant cell fibroma”. Later the case has been followed for 6 months and there was no sign of recurrence.

II. Discussion:

Giant cell fibroma is a benign neoplasm that is clinically and microscopically distinct from fibroma. In 1974 Weathers and Callihan [1] introduced the term giant cell fibroma to describe a benign fibrous oral mucosal tumour that has been diagnosed previously as fibroma, fibrous hyperplasia or fibroepithelial polyp. They mentioned that there were sufficient unusual and distinctive clinical and histologic features to warrant separation and reclassification as a separate entity.

Giant cell fibroma makes up about 1% of oral biopsies and 5% of all oral mucosal fibrous lesions. Giant cell fibroma occurs in the first 3 decades of life with peak incidence in the second decade. Lesions in older patients are usually found to be present for many years. These lesions are found to be more common in females and have a marked preponderance for Caucasians[7]. The lesion is most often described as asymptomatic, small raised, pedunculated and papillary growth, often misdiagnosed as papilloma. The vast majority of the lesions are less than 1 cm in diameter with an average size more frequently under 0.5cm. These lesions are most commonly seen on the mandibular gingiva, followed in descending order by the maxillary gingiva, tongue, palate, buccal mucosa, lips and floor of the mouth[2]. The lesion is commonly misdiagnosed as papilloma because of their small size, irregular surface and pedunculated base. The clinical features of the lesion in our case is closely correlating with the classical clinical features described by Weathers and Callihan [1].

Microscopic features of these pedunculated, exophytic masses shows of fibrous connective tissue that is loosely arranged with a prominent vascular element, especially in the subepithelial zone. Inflammation is rarely seen. The most characteristic feature is the presence of large spindle shaped or more often stellate shaped cells [3]. These cells are more often mononuclear, but multinucleated cells may also be present. These cells are more prominent just beneath the epithelium and are less common or absent in the central portion[7].

The microscopic features of the lesion in our case also showed loosely arranged connective tissue with numerous endothelial lined blood vessels and characteristic large stellate shaped giant fibroblasts with very few inflammatory cells, thus suggestive of giant cell fibroma under light microscope. The origin and nature of these cells have been a subject of much debate. It has been suggested that the mononuclear and multinucleated cells of giant cell fibroma might be melanocytes and Langerhans' cells However, the negative staining for S-100 excludes this hypothesis[3,4]. Similar results were also reported by Odell et al. [8] and Magnusson and Rasmusson [9]. The possibility that these cells are derived from macrophage-monocyte lineage is not supported and mast cell origin is incompatible with a negative reaction for tryptase[10]. Erica Campos[11] and Weathers and Campbell[3] suggested that the stellate and multinucleate cells of giant cell fibroma have a fibroblast phenotype and are large atypical fibroblasts. A variety of cutaneous lesions such as the fibrous papule of the nose, ungual fibroma, acral fibrokeratoma and acral angiofibroma containing similar stellate mono and multinuclear giant cells have been described in humans. The main similarity between this group of cutaneous lesions and the giant cell fibroma is their histologic appearance. The differences are that the skin lesions have not been associated with oral lesions and they do not show same frequency of occurrence and age distribution. Three other human mucous membrane lesions have been reported with histology similar to the giant cell fibroma. They are pearly penile papule of the glans penis[12], the retrocuspid papillae and symmetrical gingival fibromatosis[13]. The difference between these lesions and giant cell fibroma is the presence of stellate shaped mononucleated or multinucleated giant fibroblast in giant cell fibroma.

Treatment of choice of this lesion is conservative surgical excision. Recurrences are considered rare. The recurrence of these cases are reported in few incidences and found to be due to incomplete removal of the lesion. Not all authorities believe that the giant cell fibroma should be classified as a separate entity, since they feel that the histology is not sufficiently characteristic or unusual to warrant separation from other focal fibrous hyperplasias. Weathers and Callihan,[1] however, feel that, along with its distinctive histology, the giant cell fibroma's characteristic location, age distribution, size, surface characteristics, and lack of remarkable sex predilection clearly separates it from the usual fibrous hyperplasias of the oral mucosa. Though the mono or multinucleated cells are said to be atypical fibroblasts, further studies are necessary to comment, whether these cells shows degenerative and functional changes, whether the giant cell fibroma will be regarded as a distinct clinical and histologic entity. Similarly the nature of the stellated multinucleate and mononuclear cell is also not clear. Further studies are necessary to address these issues.

Acknowledgement

We would like to thank Dr.Pavlo Davydov, Histopathologist , Ibn-Sena Hospital , Sirte for his valuable contributions.

Reference:

- [1]. Weathers DR, Callihan MD: Giant cell fibroma. Oral Surg Oral Med Oral Pathol 37: 374-384, 1974
- [2]. Bakos LH: The giant cell fibroma: a review of 116 cases. Ann Dent 5: 32-35, 1992
- [3]. Houston GD: The giant cell fibroma: a review of 464 cases. Oral Surg Oral Med Oral Pathol 53: 582-587, 1982
- [4]. Weathers DR, Campbell WG: Ultrastructure of the giant cell fibroma of the oral mucosa. Oral Surg Oral Med Oral Pathol 38: 550-561, 1974
- [5]. Takeda, Y., Kaneko, R., Suzuki, A., and Niitsu, J.: Giant cell fibroma of the oral mucosa—report of a case with ultrastructural study. Acta Pathol Jpn 36: 1571-1578, 1986.
- [6]. Robert Marx E, Diane Stern. Oral and maxillofacial pathology : A rationale for diagnosis and treatment , 1st edition, Quintessence Publishing co, Chicago, 2003,p 396-7
- [7]. Swan RH: Giant cell fibroma. A case presentation and review. J Periodontol 59: 338-340, 1988
- [8]. Regezi JA, Zarbo RJ, Tomich CE, Lloyd RV, Coutney RM, Crissman JD: Immunoprofile of benign and malignant fibro-histiocytic tumors. J Oral Pathol 16: 260-265, 1987
- [9]. Odell E, Lock C, Lombardi T: Phenotypic characterization of stellate and giant cells in giant cell fibroma by immunocytochemistry. J Oral Pathol Med 23: 284-287, 1994
- [10]. Magnusson BC, Rasmusson LG: The giant cell fibroma. A review of 103 cases with immunohistochemical findings. Acta Odontol Scand 53: 293-296, 1995
- [11]. Campos Erica, Gomez Ricardo Santiago: Immunocytochemical Study of Giant Cell Fibroma. Braz Dent J 10(2): 89-92, 1999
- [12]. Winer, J. H., and Winer, L. H.: Hirsutoid papillomas of coronal margin of glans penis. J Urol 74: 375, 1955..
- [13]. Berman, F. R., and Fay, J. T.: The retrocuspid papilla. Oral Surg 42: 80, 1976.

LEGENDS FOR PHOTOGRAPHS:

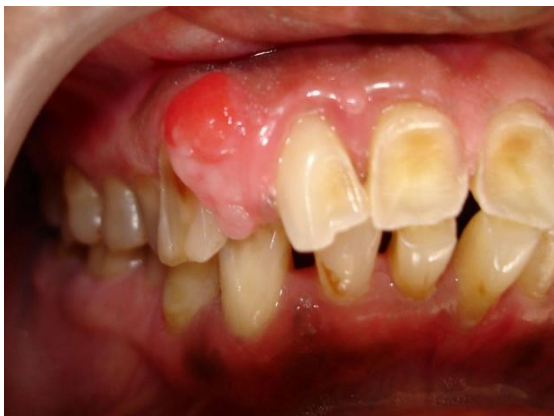

Figure 1:Pre-operative view

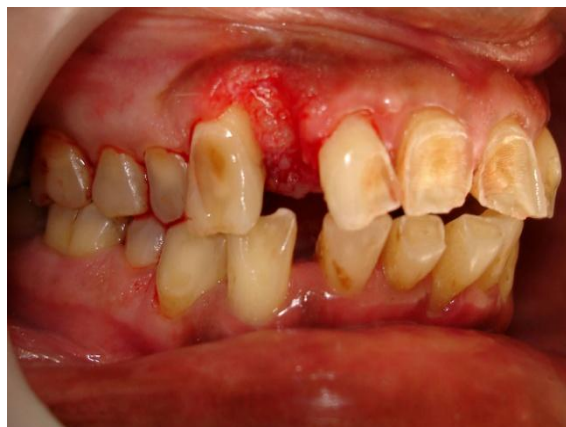

Figure 2:Immediate post operative view

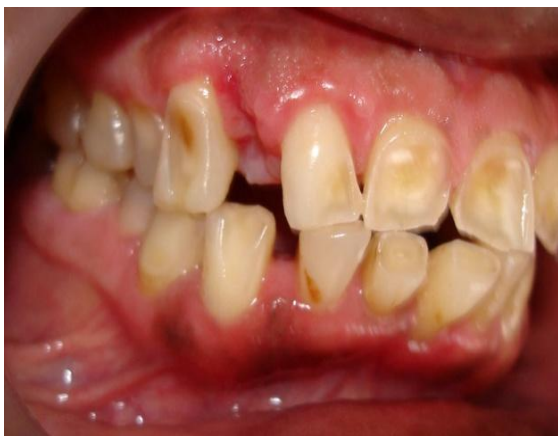

Figure 3: One week Post-operative view

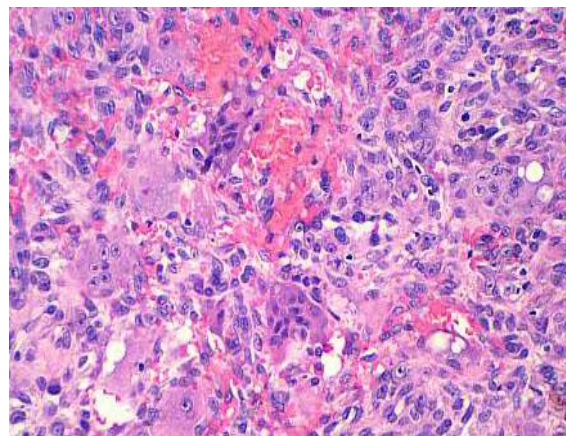


Figure 4: Histological appearance of the oral lesion