

SEPTO- Optic Dysplasia, a Rare Case Report

Dr.SaurabhSinghal¹, Dr.Vrishty Jain²

¹(HOD, Professor, Department of Medicine, Subharti Medical College, Meerut)

²(JR III, Department of Medicine, Subharti Medical College, Meerut)

Abstract: Septo-optic dysplasia (SOD) is a rare developmental disorder which comprises of clinical triad of midline brain abnormality, optic nerve hypoplasia and hypopituitarism. Diagnosis of this syndrome is clinical. However in recent times various genetic mutations have been found causing this syndrome complex like HESX1, OTX2, SOX3 and SOX2, at the same time yield of genetic diagnosis in less than 1%. We report here, a case of Septo-optic dysplasia, who presented with seizures and had pendular nystagmus with secondary optic atrophy in both eyes and absence of septum pellucidum on further evaluation.

Keywords: Septum pellucidum; Hypopituitarism; Optic atrophy.

I. Introduction

Septo-optic dysplasia (SOD), also known as de Morsier Syndrome, is a rare congenital condition with a heterogeneous phenotype (1-3). The diagnosis is clinical, based on the presence of two or more features of the classical triad of Optic nerve hypoplasia, pituitary hormone abnormalities, midline brain defects. It has an equal occurrence rate in both the sexes. However in recent times various genetic mutations have been found causing this syndrome complex like HESX1, OTX2, SOX3 and SOX2, at the same time yield of genetic diagnosis in less than 1%. Hypopituitarism is present in 62-80% of patients. Midline brain defects include agenesis of the septum pellucidum (60% of cases) and/or corpus callosum.

II. Case Report-

A 19 year old male presented to Subharti hospital with complaint of 2 episodes of generalized tonic clonic seizures around two hours before the time of presentation with involuntary passage of urine in clothes as noticed by his parents. This was associated with frothing from mouth and uprolling of eyes with fisting of hands lasting for around 10 seconds. This was followed by post-ictal confusion, with no loss of consciousness. There was no prior history of fever, nausea, vomiting, prior headache or trauma. No similar history in the past. The patient was non-alcoholic and non-smoker. Patient's birth history was not significant with no developmental delay. Family history was unremarkable.

On admission, the patient was in post ictal phase, confused, not oriented.

General examination-

- -B.P.- 120/76 mmHg
- -P.R.-94bpm, regular
- -R.R.- 20/minute
- -Temperature- 98.8 F (axillary)
- -sPO₂- 99% (At room air)
- -no pallor, icterus, cyanosis, clubbing, edema, lymphadenopathy.

Systemic examination-

- a) CNS Examination- E4V4M5
 1. Patient was conscious, not oriented to time, place and person.
 2. Bilateral plantar extensor.
 3. Tone normal.
 4. Power could not be assessed.
 5. Exaggerated DTRs.
- b) CVS Examination-
 - S1 and S2 heart sounds heard.
 - No murmur heard.
- c) Respiratory Examination-
 - Bilateral vesicular breath sounds heard.
- d) Per abdomen- soft, non tender, no organomegaly, bowel sounds present.

e) Ophthalmological examination:- both eye pendularnystagmus and right eye exotropia. Fundus examination showed both eye secondary optic atrophy.

Investigations-

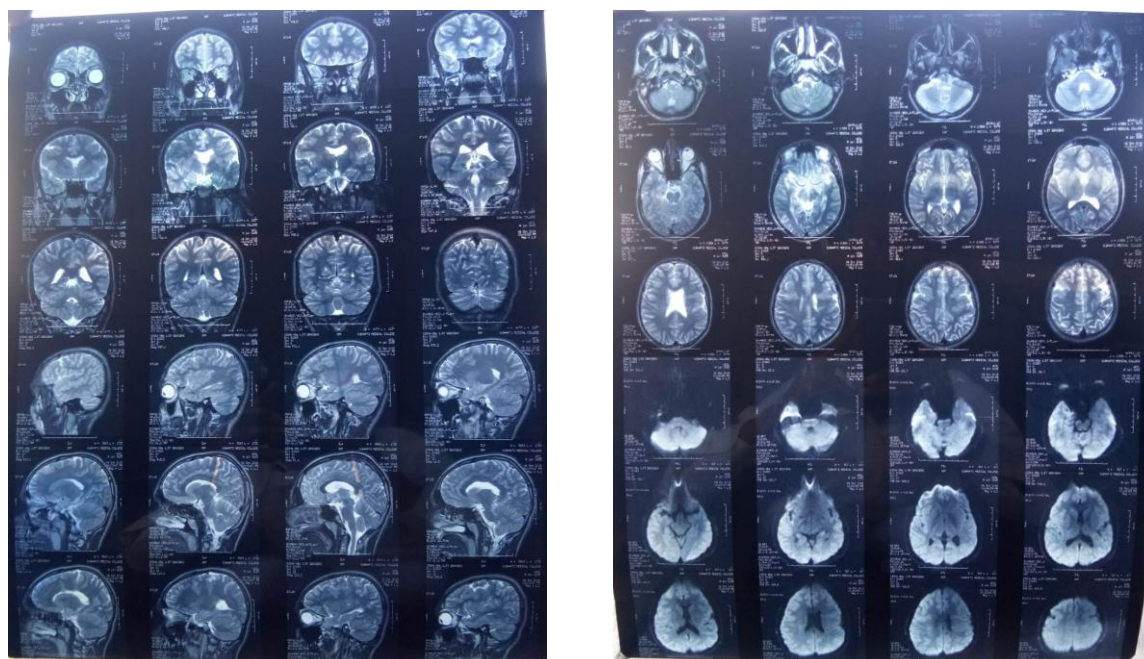
1. Blood investigations: Normal complete blood counts, liver function tests, renal function tests, lactate and ammonia levels. Normal levels of fasting insulin (4.86 pmol/l), cortisol (275.9 nmol/l) and adrenocorticotrophic hormone (4.85pmol/l).

2. EEG- normal baseline electrogenesis without paroxysmal activity.

3.NCCT head- revealed tiny hyperdense foci in left basal ganglia region.

4.Contrast enhanced MRI study of the brain - evidence of absence of septum pellucidum with prominent grey matter region in bilateral frontal lobes, crossing periventricular white matter to reach and touch bilateral lateral ventricles suggestive of – Septo-optic dysplasia with lobar holoprosencephaly.

Patient was given anti-epileptics during the course of hospital stay via intravenous route, to which patient responded.



CE MRI brain showing Lobarholoprosencephaly and Septo-optic dysplasia

III. Discussion

SOD diagnosis is clinical and can be made when two or more features of the classical triad are present: optic nerve hypoplasia, midline brain defects and pituitary hormone abnormalities. As in our case, patient presented with new onset seizures and further MRI study revealed holoprosencephaly, i.e. midline brain defect. Only about 30% of the cases have the complete triad.¹⁻⁸ The optic nerve hypoplasia can be unilateral or bilateral,⁴⁻¹¹ the latter being more common (>70% of cases). Clinically, the child may present with microphthalmia,⁴⁻¹⁰ coloboma, strabismus or nystagmus and a variable degree of visual impairment. Neurological findings may include mild to moderate developmental delay (more common in children with bilateral (57%) as opposed to unilateral optic nerve hypoplasia (32%), neurological focal deficits, mental retardation, cerebral palsy and seizures.¹² After detailed history, clinical examination and investigations, this patient was diagnosed with Septo-optic dysplasia, as a rare cause of seizure.

IV. Conclusion

Septo-optic dysplasia is a syndrome that varies tremendously in its presentation, sometimes occurring in isolation and sometimes in association with other cortical malformations. As in our case, patient presented with seizures and MRI revealed midline brain defect.

References

- [1]. Webb E, Dattan M. Septo-optic dysplasia. *Eur J Hum Genet* 2010;2013:393–7
- [2]. de Morsier G. Étudessur les dysraphiescranio-encephaliques: III. Agenesie du septum lucidum avec malformation du tractusoptique: La dysplasieseppto-optique. *Schweizer Arch Neurol Psychiatr*1956;2013:267–92
- [3]. Patel L, McNally RJ, Harrison E, et al. Geographical distribution of optic nerve hypoplasia and septo-optic dysplasia in Northwest England. *J Pediatr* 2006;2013:85–8
- [4]. Garcia ML, Ty EB, Taban M, et al. Systemic and ocular findings in 100 patients with optic nerve hypoplasia. *J Child Neurol* 2006;2013:949–56
- [5]. Atapattu N, Ainsworth J, Willshaw H. Septo-optic dysplasia: antenatal risk factors and clinical features in a regional study. *Horm Res Paediatr* 2012;2013:81–7
- [6]. Thomas PQ, Dattani MT, Brickman JM, et al. Heterozygous HESX1 mutations associated with isolated congenital pituitary hypoplasia and septo-optic dysplasia. *Hum Mol Genet* 2001;2013:39–45
- [7]. McNay DE, Turton JP, Kelberman D, et al. HESX1 mutations are an uncommon cause of septooptic dysplasia and hypopituitarism. *J ClinEndocrinolMetab* 2007;2013:691–7
- [8]. Kelberman D, Dattani MT. Genetics of septo-optic dysplasia. *Pituitary*. 2007;2013:393–407
- [9]. Riedl SW, Müllner-Eidenböck A, Prayer D, et al. Auxological, ophthalmological, neurological and MRI findings in 25 Austrian patients with septo-optic dysplasia (SOD): preliminary data. *Horm Res*2002;2013:S16–19
- [10]. Signorini SG, Decio A, Fedeli C. Septo-optic dysplasia in childhood: the neurological, cognitive and neuro-ophthalmological perspective. *Dev Med Child Neurol* 2012;2013:1018–24
- [11]. Haddad NG, Eugster EA. Hypopituitarism and neurodevelopmental abnormalities in relation to central nervous system structural defects in children with optic nerve hypoplasia. *J PediatrEndocrinol Metab*2005;2013:853–8