

Anti-Hemorrhoidal Activity of Leaf Butanol Fraction *Portulaca Oleracea* L., Belonging To the Family *Portulacaceae*

Takur Shivani¹, Kanakam Vijayabhaskar^{1**}, Pingali Srinivasa Rao,^{*1}
Bandi Anil Kumar¹ Dr.Kamal Yadav².

¹St. Peter's Institute of Pharmaceutical Sciences, Vidyanagar, Hanamkonda, Warangal urban, Telangana-506001
-INDIA.

²Vaagdevi Pharmacy College, Bollikunta, Warangal Urban, Telangana-506005-INDIA.

Corresponding author*: Kanakam Vijayabhaskar**

M.Pharm., Ph.D Assistant professor Department of Pharmacognosy,
St. Peter's Institute of Pharmaceutical Sciences, Vidyanagar, Warangal, Telangana

Abstract: The objective of present study of Anti-hemorrhoidal activity on leaf butanol fraction of *portulaca oleracea*. Anti-hemorrhoidal potential of fraction was determined by levels of inflammatory cytokines such as TNF- α , IL-6, PGE2 and rectoanal coefficient (RAC). The histopathological examination was done to evaluate the severity score in the treated and untreated groups. The methanolic extract of butanol fraction shows significantly reduced the inflammatory cytokines {TNF- α (4.99 \pm 0.047), IL-6(2.81 \pm 0.067), PGE2(40.08 \pm 0.563) and RAC(1.83 \pm 0.021)} as compared to positive control group{TNF- α (15.88 \pm 0.186),IL-6(2.01 \pm 0.061), PGE2(41.01 \pm 0.075) and RAC(2.832 \pm 0.107)}. Noticeably the results were comparable to that of standard pilex granules {TNF- α (5.397 \pm 0.044), IL-6(3.01 \pm 0.156), PGE2 (42.51 \pm 2.157) and RAC (1.168 \pm 0.014)}. Molecular docking and structure based pharmacophore mapping further confirmed the anti-inflammatory mediated antihemorrhoidal activity of the methanolic extract of n-butanol fraction.

Keywords: *Portulaca oleracea*, butanol fraction, L-ascorbic acid, UV-Visible spectrophotometer, Histopathology, Rat PGE2 Elisa kit, Rat IL-6 Elisa kit, TNF- α Elisa kit.

Date of Submission: 02-10-2019

Date of Acceptance: 18-10-2019

I. Introduction

Hemorrhoids are abnormal masses of dilated blood vessels in swollen tissue that occurs internally in the anal canal or externally around the anus which may be bleeding, pain or itching. It has been a common and pain full human disease for decades which are majorly due to dietary habits. This disease is frequently encountered in developing countries (1). Hemorrhoid is one of the most common inflammatory disease which can be characterized by an alteration in vasculature of the anal-canal including blood vessels, supporting tissues, muscles and elastic fibers. There are two types of piles, internal piles and external piles. Internal piles expand inside, along the anal. The common symptom of internal pile is the painless blood loss. The internal piles are totally prolapsed. External piles extend close to the anus. The colour of external piles is same as the skin. The outside piles forms thrombus. The outside piles are painful. When the external pile ruptures, it bleeds. The blood loss is more disturbing, and it is the major concern for considering a therapeutic measure by a medical practitioner. Prolapsed condition on the other hand, is an oral dysfunction a effect of piles (2). Free radical generation is the primary reason for initiation of many physiological and pathological disorders like hemorrhoids. Involvement of free radicals in the precipitation of hemorrhoids is well documented in the literature. It is well known fact that excess concentration of free radicals is a consequence of improper balance between reactive oxygen species and their metabolites.(3) Antioxidants neutralize free radicals and thus play major role in the eradication of these free radicals and hence are involved in the management of hemorrhoids. Unavoidable and serious adverse effects associated with commercial or synthetic antioxidants are becoming a major concern for the researchers to develop natural antioxidants. Herbal extracts rich in phytoantioxidants like polyphenols, flavonoids, tannins and other related compounds are known to possess positive health effects and eventually reduces the incidence of diseases.(4) Therefore much attention has been focused on the use of natural antioxidants that can provide more significant health benefits with minimal toxicities.(5) *Portulaca oleracea* also provides a source of nutritional benefits owing to its rich omega-3 fatty acids and antioxidant properties (6).

Portulaca oleracea has been used as a folk medicine in many countries, acting as a febrifuge, antiseptic, vermifuge, and so forth(7). It exhibits a wide range of pharmacological effects, including antibacterial(8), antiulcerogenic(9), anti-inflammatory(10), antioxidant(11), and wound-healing(12) properties.

It is listed by the World Health Organization as one of the most used medicinal plants, and it has been given the term “Global Panacea” (13). The Chinese folklore described it as “vegetable for long life” and it has been used for thousands of years in traditional Chinese Medicine (14-15). It is cold in nature and sour in taste and is used to cool the blood, stanch bleeding, clear heat, and resolve toxins. The dried aerial part of this plant is indicated for the treatment of fever, dysentery, diarrhoea, carbuncle, eczema and hematochezia, with a recommended dose of 9–15 g(16-18). One of the most effective constituents present in Chinese Herbal Medicines are flavonoids which are biologically active and possess a wide range of pharmacological properties. Hence, the present study focuses on the scientific investigation of Anti-hemorrhoidal activity on leaf butanol fraction of portulaca oleracea.

II. Materials And Methods

Plant material

Portulaca oleracea L., belonging to the Portulacaceae family, is commonly known as purslane in English and Ma-Chi-Xian in Chinese. It is a warm-climate, herbaceous succulent annual plant with a cosmopolitan distribution. It is eaten extensively as a potherb and added in soups and salads around the Mediterranean and tropical Asian countries and has been used as a folk medicine in many countries.

The plant was collected from local area of Warangal, telangana, India in the month of april, 2019 and was authenticated by Dr N.Raju at Department of Botany (Ref. KUBL421), Kakatiaya University ,Telanagana, India.

Drugs and chemicals

Pyridine, Diethyl ether and isoflurane were procured from Merck Specialities Pvt. Ltd., Mumbai, India. L-ascorbic acid, Rutin and Evans blue were procured from Hi-Media Research Laboratories Pvt. Ltd., Mumbai, India. Croton oil was procured from Sigma Aldrich, St. Louis, USA. Rat TNF- α Elisa kit and Rat IL-6 Elisa kit were purchased from Raybiotech Inc., Norcross, United States. Rotary evaporator used for concentrating the extract was procured from Heidolph, Schwabach, Germany. . Rat PGE2 Elisa kit was purchased from Cloud Clone Corp., Houston, USA. All analytical readings were taken on UVeVisible spectrophotometer (UV-1800, Shimadzu), and Elisa microplate reader (Erba Lisa Scan II, Mannheim). Microtome used for histological sections was procured from Scientech Inst., New Delhi, India.

Extraction of plant material

The coarsely powdered *leaves* (600g) of *Portulaca oleracea* were extracted to exhaustion in a soxhlet apparatus at 50°C with 500ml of methanol. The extract was filtered through a cotton plug, followed by whatman filter paper (no.1) and then concentrated by using a rotary evaporator at a low temperature (40-60°C) and reduced pressure to provide methanolic extractive of 15.4g, and fractionated by column chromatography with butanol as a solvent residue weigh of 5.2 g.

Animals

Wistar albino rats (150-250 g) were kept in polypropylene cages at an ambient temperature of 25±2°C and 55-65% relative humidity. A 12 h light/dark cycle was maintained in the animal house. The rats had free access to water and fed with ad libitum. Acute toxicity studies Acute toxicity of methanolic extract of n-butanol fraction was performed as per the OECD- 420 guidelines. Wistar albino rats of either sex weighing between 150 and 250 g were divided into different groups comprising six animals each. The control group received normal saline (2 ml/kg,p.o.). The other groups received 100 to 2000 mg/kg of the test fraction respectively. Post dosing, the animals were observed continuously for the first 4 h for any behavioral changes. Thereafter, they were then kept under observation up to 14 days after drug administration to find out the mortality if any.

Experimental design

Wistar rats were divided into four groups,

Group I: Served as normal control and received only distilled water.

Group II: Served as positive control and received 6% croton oil (10 ml).

Group III: Served as treated group and was administered with butanol fraction of *Portulaca oleracea* leaves (100 mg/kg, b.wt, PO) and 6% croton oil (10 ml).

Group IV: Served as standard and was administered with Pilex granules (100 mg/kg, b.wt, PO) and 6% croton oil (10 ml). After overnight fasting, Evans blue (30 mg/kg i.v.) was injected in tail of animals of all the groups. After 30 min, hemorrhoids were induced in all groups except normal control group by applying croton-oil preparation (deionized water, pyridine, diethyl ether, and 6% croton oil in diethyl ether in the ratio of 1: 4: 5: 10). Sterile cotton swab (4mm in diameter) soaked in cotton oil preparation (100 ml) was inserted into the anus (about 22mm diameter) and kept for 10 s. A linear development of oedema was observed within 8h to 10 hrs of

induction of croton oil. After 24 h of induction, relevant treatment was given to all the groups for five days. On fifth day, 1 h after the treatment, blood was collected from the retro-orbital sinus. Inflammatory cytokines such as PG, TNF-a and IL-6 was estimated in blood by using Elisa Microplate Reader (Erba Lisa Scan II, Mannheim). All animals were euthanized by exsanguinations under deep iso-flurane anesthesia and recto-anal tissue (20mm in length) was isolated and weighed. Evans blue present in the tissue was extracted by 1ml formaldehyde and absorbance was taken at 620 nm using Elisa Microplate Reader (Erba Lisa Scan II, Mannheim). Concentration was quantified using standard curve of evans blue dye. For histological examination, same tissue was examined for severity score and rectoanal-coefficient by fixing the tissue in 10% neutral buffered formalin. The recto-anal-coefficient (RAC) was calculated from the formula
 Recto-anal Coefficient $\frac{1}{4}$ Weight of rectoanal tissue (mg) / Bodyweight (mg)
 Histological observation was performed for inflammation, congestion, hemorrhage, vasodilation and necrosis.(19)

Statistical analysis

The results were expressed as Mean \pm SEM and analyzed by one-way ANOVA followed by Student t-test and P < 0.001 was considered to be statistically significant.

III. Results And Discussion

The results of methanolic extract of butanol fraction of *Portulaca oleracea leaves* was evaluated for acute toxicity in rats and it was observed is safe even at the higher concentration of 2000 mg/kg b.wt, and no mortality was observed after 14 days of fraction administration. Croton oil application in the recto-anal region caused significant increase in RAC (P < 0.001), PGE2 (P < 0.001), TNF-a (P < 0.001) and IL-6 (P < 0.001), it also resulted in increased exudation (4.00 ± 0.122 , P < 0.001) of evans-blue dye as compared to normal control group animals (0.982 ± 0.0678). Treatment with leaf butanol fraction (100 mg/kg, P < 0.001) has maintained the RAC of 1.83 ± 0.021 and IL-6 of 2.81 ± 0.067 nearly same as normal control groups animals (0.912 ± 0.0617 , 1.83 ± 0.021) whereas, treatment with pilex granules (100 mg/kg, b.wt, PO) showed the RAC of 1.168 ± 0.014 and IL-6 of 2.01 ± 0.061 . Moreover, the effect of butanol-fraction (100 mg/kg, P < 0.001) was statistically significant against elevated levels of TNF-a (4.99 ± 0.047) as compared to normal control group (4.70 ± 0.329) as given in Table 1. Treatment with pilex granules has also significantly reduced the elevated levels of TNF-a (5.397 ± 0.044). butanol fraction and pilex granules (400 mg/kg, P < 0.001) have also offered significant protection against increased evans-blue dye exudation on application of croton oil.

Histopathological examination of treated group (butanol fraction, 100 mg/kg) and pilex granules (100 mg/kg) revealed that there was marked reduction in the RAC severity score, vasodilation extent, hemorrhagic and necrosis level. It is noteworthy that treatment with the butanol fraction at 100 mg/kg restored almost normal architecture of recto-anal region. It is a well known fact that herbal drugs have been in use since many decades, most probably owing to their lesser side effects and high safety profile.

In view of traditional use of leaves of *Portulaca oleracea* as an pharmacological properties such as neuroprotective, antimicrobial, antidiabetic, antioxidant, anti-inflammatory, antiulcerogenic, and anticancer activities, blood motions, laxative property. We have attempted to evaluate its anti-hemorrhoidal activity through well established scientific methods. As a starting point the methanolic extract of n-butanol fraction with leaves of *Portulaca oleracea* has been screened.

Table 1

Table 1: Parameters of anti-hemorrhoidal activity.

S. No.	Groups	Severity score	Recto-anal Coefficient	Evans Blue	TNF-a	IL-6	PGE2
1	Normal control (Only vehicle)	---	0.963 ± 0.0846	0.982 ± 0.0678	4.70 ± 0.329	2.15 ± 0.141	36.44 ± 2.876
2	Positive Control (Croton oil)	2.19 ± 0.178	2.832 ± 0.107	4.00 ± 0.122	15.88 ± 0.186	6.38 ± 0.137	91.01 ± 0.193
3	Butanol fraction (100 mg/kg)	0.80 ± 0.054	1.83 ± 0.021	1.211 ± 0.028	4.99 ± 0.047	2.81 ± 0.067	40.08 ± 0.563
4	Pilex granules (100 mg/kg)	0.49 ± 0.177	1.168 ± 0.014	1.02 ± 0.608	5.397 ± 0.044	2.01 ± 0.061	41.01 ± 0.075

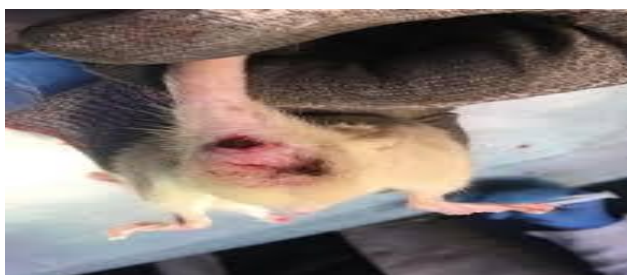Histopathology

Effect of butanol fraction and Pilex granules on the histology of rectoanal tissue in croton-oil induced hemorrhoids. Rectoanal sections of rats: Fig. 1 (a) Group I (normal control) has normal architecture of rectal tissue; (b) Group II (positive control) exhibited severe inflammation, hemorrhage, necrosis, vasodilation and congestion (c) Group III treated with

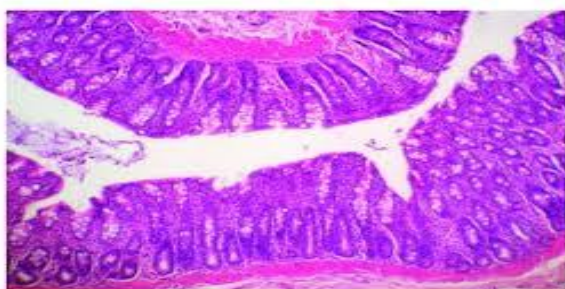
methanolic extract of n butanol fraction of leaves showed minimal inflammation, congestion, hemorrhage, dilatation, degeneration and necrosis (d) Group IV treated with pilex granules (100 mg/kg p.o.) showed nearly normal architecture of the tissue.



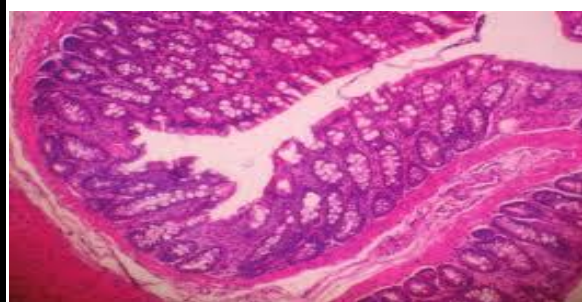
Inducing agent



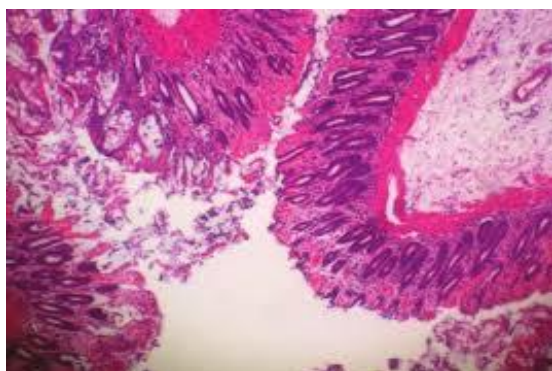
after croton oil



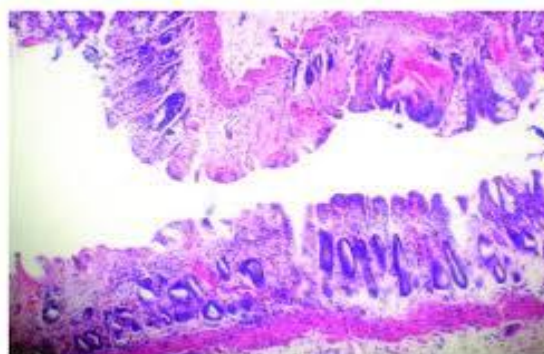
Group I-* Control



Group II-* Toxic



Group III*- Test



Group IV* Standard

Hemorrhoids are the pathological condition, often characterized by vasodilatation and inflammation in the recto-anal region, which results in increased vascular permeability and extravasation of inflammatory cytokines in the interstitial spaces. In the present study, croton oil has been used as phlogistic agent for experimental induction of hemorrhoids. Croton oil causes inflammation due to release of inflammatory lipid metabolites such as prostaglandins, leukotrienes, TNF- α , nitric acid and bradykinins. These factors alone or in combination regulates the activation of fibroblasts, endothelial cells, macrophages and newly recruited monocytes, lymphocytes, neutrophils and eosinophils which leads to severe inflammation. In present studies, extravasation of Evans blue dye has been used for estimation of inflammatory cytokines. The positive control group showed severe exudation of Evans blue dye and increased concentration of pro-inflammatory cytokines {TNF- α , IL-6, PGE2 -15.88 ± 0.186 , 6.38 ± 0.137 , 91.01 ± 0.193 and rectoanal-coefficient 2.832 ± 0.107 . These changes were further supported by the histopathological changes in the rectoanal region such as severe vasodilatation, infiltration of inflammatory cytokines and hemorrhagic spots. On the other hand, as expected the fraction showed good anti-hemorrhoidal activity as reflected by reduced levels of inflammatory cytokines such as TNF- α , IL-6, PGE2, rectoanal-coefficient 4.99 ± 0.047 , 2.81 ± 0.067 , 40.08 ± 0.563 , 1.83 ± 0.021 . The earlier reports have established the role of flavonoids in oxidative stress, inflammation and hemorrhoid in both clinical and pre-clinical settings. It is well known fact that flavonoids reduce the concentration of PGE2e and PGE2a

and other inflammatory mediators. In view of aforementioned facts, the observed antihemorrhoidal activity can be attributed in the leaves of *Portulaca oleracea*. It is noticeable that fraction has exhibited equipotent activity to that of standard therapy of pilex granules with reduced levels of inflammatory cytokines

IV. Conclusion

In the present study screening of the efficiency of butanolic fraction can be attributed as anti-hemorrhoidal agent. Results clearly shows anti-inflammatory activity in croton oil induced hemorrhoids which could be attributed to the presence of potent antioxidants, Moreover, butanol fraction had significantly reduced the levels of inflammatory markers like prostaglandins, leukotrienes interleukins. Further study needed to structure elucidation of butanol fraction.

Acknowledgement

The authors are thankful to Management of St.Peter's institute of pharmaceutical sciences Warangal. And thanks to Dr. Kamal yadav for their continuous support.

References

- [1]. Abayomi S. Medicinal plant and traditional medicine in Africa. Spectrum Books.Ibadan. 2006;1-23
- [2]. Elvin M. Traditional medicine in Nigeria. (Ed.).Federal Ministry of Health, Nigeria Bulletin No 120. 2014;45:56-59
- [3]. Johanson JF, Sonnenberg A. The prevalence of hemorrhoids and chronic constipation:an epidemiologic study. *Gastroenterology*. 1990;98(2):380e386.
- [4]. Evans P, Halliwell B. Micronutrients: oxidants/antioxidants status. *Br J Nutr*.2001;85(Suppl 2):S67eS74.
- [5]. Gowri SS, Pavitha S, Vasantha K. Free radical scavenging capacity and antioxidant activity of young leaves and barks of *Acacia nilotica* (L.) Del. *Int J Pharm Pharmaceut Sci*. 2011;3(1):160e164.
- [6]. Palaniswamy U. R., McAvoy R. J., Bible B. B. Stage of harvest and polyunsaturated essential fatty acid concentrations in purslane (*Portulaca oleraceae*) leaves. *Journal of Agricultural and Food Chemistry*. 2001;49(7):3490–3493. doi: 10.1021/jf0102113.
- [7]. Lee A. S., Kim J. S., Lee Y. J., Kang D. G., Lee H. S. Anti-TNF- α activity of *Portulaca oleracea* in vascular endothelial cells. *International Journal of Molecular Sciences*. 2012;13(5):5628–5644. doi: 10.3390/ijms13055628.
- [8]. Zhang X. J., Ji Y. B., Qu Z. Y., Xia J. C., Wang L. Experimental studies on antibiotic functions of *Portulaca oleracea* L. *in vitro* . *Chinese Journal of Microecology*. 2002;14(6):277–280.
- [9]. Karimi G., Hosseinzadeh H., Ettehad N. Evaluation of the gastric antiulcerogenic effects of *Portulaca oleracea* L. extracts in mice. *Phytotherapy Research*. 2004;18(6):484–487. doi: 10.1002/ptr.1463.
- [10]. Chan K., Islam M. W., Kamil M., et al. The analgesic and anti-inflammatory effects of *Portulaca oleracea* L. subsp. *Sativa* (Haw.) Celak. *Journal of Ethnopharmacology*. 2000;73(3):445–451. doi: 10.1016/s0378-8741(00)00318-4.
- [11]. Chen B., Zhou H., Zhao W., Zhou W., Yuan Q., Yang G. Effects of aqueous extract of *Portulaca oleracea* L. on oxidative stress and liver, spleen leptin, PAR α and FAS mRNA expression in high-fat diet induced mice. *Molecular Biology Reports*. 2012;39(8):7981–7988. doi: 10.1007/s11033-012-1644-6.
- [12]. Rashed A. N., Afifi F. U., Disi A. M. Simple evaluation of the wound healing activity of a crude extract of *Portulaca oleracea* L. (growing in Jordan) in *Mus musculus* JVI-1. *Journal of Ethnopharmacology*. 2003;88(2-3):131–136. doi: 10.1016/s0378-8741(03)00194-6 .
- [13]. Xu X., Yu L., Chen G. Determination of flavonoids in *Portulaca oleracea* L. by capillary electrophoresis with electrochemical detection. *Journal of Pharmaceutical and Biomedical Analysis*. 2006;41(2):493–499. doi: 10.1016/j.jpba.2006.01.013.
- [14]. Chen C.-J., Wang W.-Y., Wang X.-L., et al. Anti-hypoxic activity of the ethanol extract from *Portulaca oleracea* in mice. *Journal of Ethnopharmacology*. 2009;124(2):246–250. doi: 10.1016/j.jep.2009.04.028.
- [15]. Jin R., Lin Z. J., Xue C. M., Zhang B. An improved association-mining research for exploring Chinese herbal property theory: based on data of the Shennong's Classic of Materia Medica. *Journal of integrative medicine*. 2013;11(5):352–365. doi: 10.3736/jintegrmed2013051.
- [16]. Li J., Wu X.-L., Chen Y., et al. Antidiarrheal properties of different extracts of Chinese herbal medicine formula Bao-Xie-Ning. *Journal of Chinese Integrative Medicine*. 2013;11(2):125–134. doi: 10.3736/jintegrmed2013019.
- [17]. Zhao C. Q., Zhou Y., Ping J., Xu L. M. Traditional Chinese medicine for treatment of liver diseases: progress, challenges and opportunities. *Journal of Integrative Medicine*. 2014;12(5):401–408. doi: 10.1016/s2095-4964(14)60039-x
- [18]. Committee for the Pharmacopoeia of PR China. *Pharmacopoeia of PR China: Part I*. Beijing, China: China Medical Science and Technology Press; 2010.
- [19]. Azeemuddin M, Viswanatha GL, Rafiq M, et al. An improved experimental model of hemorrhoids in rats: evaluation of antihemorrhoidal activity of an herbal formulation. *ISRN Pharmacol*. 2014;1e7.

IOSR Journal of Pharmacy and Biological Sciences (IOSR-JPBS) is UGC approved Journal with SI. No. 5012, Journal no. 49063.

Kanakam Vijayabhaskar." Anti-Hemorrhoidal Activity of Leaf Butanol Fraction Portulaca Oleracea L., Belonging To the Family Portulacaceae." *IOSR Journal of Pharmacy and Biological Sciences (IOSR-JPBS)* 14.5 (2019): 16-20.